

## Trauma Analysis in Paleopathology

NANCY C. LOVELL

*Department of Anthropology, University of Alberta,  
Edmonton, AB T6G 2H4, Canada*

**KEY WORDS** fracture; dislocation; violence; head injury

**ABSTRACT** This paper reviews the mechanisms of injury and the types of fractures that most commonly affect the human skeleton, presents descriptive protocols for cranial and postcranial fractures adapted from clinical and forensic medicine, and summarizes anatomically the injuries most likely to be found in archaeological skeletons along with their most common causes and complications. Mechanisms of injury are categorized as direct and indirect trauma, stress, and fracture that occurs secondary to pathology. These are considered to be the proximate, or most direct, causes of injury and they are influenced by intrinsic biological factors such as age and sex, and extrinsic environmental factors, both physical and sociocultural, that may be thought of as the ultimate, or remote, causes of injury. Interpersonal conflict may be one of those causes but the skeletal evidence itself is rarely conclusive and must therefore be evaluated in its individual, populational, sociocultural, and physical context. A cautionary tale regarding parry fractures is presented as an illustration. *Yrbk Phys Anthropol* 40:139-170, 1997. © 1997 Wiley-Liss, Inc.

Trauma may be defined many ways but conventionally is understood to refer to an injury to living tissue that is caused by a force or mechanism extrinsic to the body. The anatomical importance and sociocultural implications of trauma in antiquity long have been recognized and the description of trauma in human skeletal remains and the identification and comparison of trauma patterns among ancient populations therefore have a lengthy history. As the discipline of palaeopathology has developed, the objectives of traumatic injury analysis have shifted from a focus on the identification and description of the earliest and the most unusual pathological specimens to the interpretation of the social, cultural, or environmental causes of traumatic injury; their relationship to biological variables, such as sex and age, that may have social or cultural relevance; and their temporal and spatial variation. Thus, interpretations of the cause of trauma in antiquity range from inter- and intragroup conflict (e.g., Angel, 1974; Hamperl, 1967; Janssens, 1970; Jurmain, 1991;

Liston and Baker, 1996; Shermis, 1984; Stewart, 1974; Walker, 1989; Wood-Jones, 1910; Zivanovic, 1982; and others) to environmentally or occupationally facilitated misadventure and accident (e.g., Angel, 1974; Burrell et al., 1986; Cybulski, 1992; Grauer and Roberts, 1996; Kelley and Angel, 1987; Lovejoy and Heiple, 1981; Wells, 1964; and others). Although great advances have been made in paleopathological diagnosis and interpretation in recent years, inconsistencies in descriptions and interpretations of trauma in the literature, particularly as they affect our understanding of the nature and extent of interpersonal violence in antiquity, have made it difficult to compare the results of different studies and to accept with confidence some conclusions. The purpose of this paper, therefore, is to review types of fractures and the mechanisms of injury, critique protocols for fracture description, and consider the problems of interpreting the causes of injury. Although an important source of data for the study of the history of medicine, a discussion of skeletal

TABLE 1. Variation in the categorization of traumatic injuries by different authors

Knowles (1983)	Merbs (1989a)	Ortner and Putschar (1981)	Steinbock (1976)	Roberts and Manchester (1995)	This study
Fractures	Fractures	Fractures	Fractures	Fractures <sup>3</sup>	Fractures <sup>4</sup>
Dislocations	Dislocations	Dislocations	Dislocations	Dislocations	Dislocations
Trephination and amputation	Surgery	Trephination	Sharp Instruments <sup>2</sup>	Osteochondritis dissecans	
Weapon wounds	Weapon wounds	Weapon wounds	Growth arrest lines		
Exostoses	Scalping	Scalping	Crushing injuries		
Schmorl's nodes	Dental trauma <sup>1</sup>	Deformation <sup>1</sup>			
Osteochondritis dissecans		Pregnancy-related			

<sup>1</sup>Includes cranial deformation, filing of teeth, and other modifications performed for aesthetic purposes.

<sup>2</sup>Includes surgery and weapon wounds.

<sup>3</sup>Includes piercing injuries caused by knife and sword cuts, scalping, and projectile points (i.e., surgery and weapon wounds).

<sup>4</sup>Includes piercing injuries caused by knife and sword cuts, scalping, and projectile points (i.e., surgery and weapon wounds), and crush fractures caused by foot binding and by cranial binding and flattening.

indicators of surgical practice and other medical intervention is beyond the scope of this paper.

Scholars have categorized traumatic injuries in a variety of ways (Table 1), but generally refer to both accidental and intentional trauma, the former usually including most fractures and dislocations and the latter usually including examples of surgical intervention and weapon wounds. It may be more prudent, however, to first sort injuries according to their predominant characteristic, either *fracture*<sup>1</sup> (any break in the continuity of a bone) or *dislocation* (the displacement of one or more bones at a joint), rather than to classify injuries in a manner that implies causation or intent.

### DISLOCATIONS

Traumatic injuries to joints may result in partial or complete dislocations. A dislocation, or luxation, occurs when the articular surfaces of a joint are totally displaced from one another. A subluxation results when the articular surfaces are partially displaced but do retain some contact. Although dislocations and subluxations may be congenital or spontaneous in origin, they are most commonly caused by trauma and in such cases it is not uncommon for the joint displacement

to be associated with a fracture. Since displacement cannot occur without damage to the joint capsule and ligaments, complications such as the ossification of membrane, ligament, and tendon attachments to bone may ensue. Persistent instability of the joint also may result, particularly in the shoulder and ankle, although this complication cannot be easily identified in archaeological skeletal remains. Osteoarthritis is one of the more common, and recognizable, complications and results from damage to the articular cartilage itself or from prolonged incongruence of the joint surfaces.

For joint displacements to be recognizable in dry bone the injury must have occurred some time before the death of an individual and remained unreduced (i.e., not "set") long enough for bone modifications to take place. Some dislocations, such as of the digits, usually can be relatively quickly and easily reduced (but see Dreier, 1992), while others, such as of the vertebrae, may cause immediate death. In either case no evidence of the injury will be observable in archaeological skeletons.

Dislocations tend to be more frequent in young and middle-aged adults, since in subadults a similar force instead causes epiphyseal separation and in older adults causes fracture of osteoporotic bones. The glenohumeral joint is a common site of dislocation, the shallowness of the shoulder joint making it particularly susceptible to displacement. Traumatic dislocation of the femoral head from the acetabulum, in contrast, requires considerable force and this site is

<sup>1</sup>"Infracture" and "infracrion" are alternative terms for "fracture," particularly undisplaced fractures, according to medical dictionaries (e.g., Stedman, 1982). Although rarely used in paleopathology, these terms may be seen in the literature with a different meaning: "infracrion," for example, has been defined as an incomplete fracture. In the interests of developing clear and standard terminology, these alternative terms are not used in this review.

TABLE 2. Summary of mechanisms of injury and associated types of fractures

Mechanism of Injury	Type of fracture	Comments
Direct trauma	Penetrating	Partial or complete penetration of bone cortex
	Comminuted	Bone is broken in more than two pieces; most common in long bone diaphyses
	Transverse	Force applied in a line perpendicular to long axis of the bone
	Crush	Most common in cancellous bone
	Depression	Crushing force on one side of the bone
Indirect trauma	Compression	Crushing force on both sides
	Pressure	Force applied to growing bone
	Spiral	Rotational and longitudinal stress on long axis; often confused with oblique fracture
	Oblique	Rotational and angular stress on long axis; often confused with spiral fracture
	Torus/greenstick	Bending of the bone due to longitudinal compression; common in children
Stress	Impacted	Bone ends are driven into each other
	Burst	Found in the spine due to vertical compression
	Comminuted	Force splits in several directions and forms a "T" or "Y" shape
	Avulsion	Fracture due to tension at ligament or tendon attachment
	Secondary to pathology	Due to repetitive force, usually perpendicular to long axis May be confused with direct trauma transverse fracture Secondary to localized or systemic disease that has weakened the bone

more commonly associated with congenital dislocations.

### FRACTURES

A fracture consists of an incomplete or complete break in the continuity of a bone. The most common types of fractures, such as transverse, spiral, oblique, and crush fractures, result from direct or indirect trauma. Two additional types of fractures, those resulting from stress and those secondary to pathology, are less common and have distinct etiologies. Fracture types and their associated mechanisms of injury are reviewed below (and summarized in Table 2), followed by discussions of fracture healing and complications.<sup>2</sup>

#### Mechanisms of injury and types of fractures

**Direct trauma.** When a break occurs at the point of impact it is referred to as a direct trauma injury (Miller and Miller, 1979) and the resulting fracture may be transverse, penetrating, comminuted, or crush (Fig. 1). A transverse fracture results from force applied in, and appears as, a line perpendicular to the longitudinal axis of the bone. Clinically, this injury often results

from a hard kick to the shin and is often seen among soccer players. Typically, transverse fractures are caused by a relatively small force delivered to a small area.

Partial or complete penetration of the bone cortex by cutting, piercing, drilling, or scraping, such as the excision of pieces of cranial vault bones in the practice of trephination, or the amputation of a limb segment is classed as a direct trauma injury. Penetrating fractures typically are caused by application of a large force to a small area. In archaeological contexts, penetration could be caused by a projectile point, the blade of an axe or sword, or a musket ball (Blair, 1983; Butler, 1971). Wounds from arrow or spear points often can be identified with certainty only if the point remains embedded in the bone and healing would not be evident if such wounds were linked to the death of the individual. The human remains in many historic cemeteries show the traumatic results of conflicts with bullets and other projectiles (e.g., Gill, 1994; Larsen et al., 1996; Owsley et al., 1991). Early cases of penetrating projectile wounds can be expected to show subsequent infection and/or pronounced deformity in the absence of stabilization or rest of the injured part. Some penetrating fractures may also be comminuted, which occurs when the bone is broken in more than two pieces. In clinical cases,

<sup>2</sup>The information provided here has been compiled from a variety of sources, including Adams (1987), Apley and Solomon (1992), Gustilo (1991), Harkess and Ramsey (1991), and Schultz (1990).

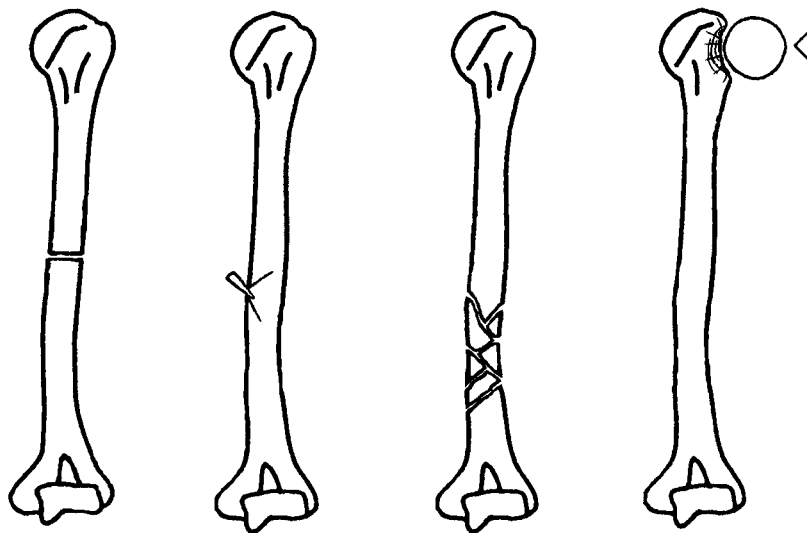


Fig. 1. Fractures caused by direct trauma. From left to right: transverse, penetrating, comminuted, and crush.

high velocity bullets and blunt force trauma to the cranium typically cause comminuted fractures.

Crush fractures most commonly occur in cancellous bone and result from the application of a direct force to the bone, which collapses on itself. Three types of crush fractures are recognized: depression, compression, and pressure. The first refers to crushing on one side of the bone (especially common on the ectocranium) while the second refers to a crushing force that originates on both sides of the bone. The incomplete penetration of a bone by a low velocity projectile may result in a crush fracture, such as depressed fractures caused by the impact of musket balls (Liston and Baker, 1996) or shotgun pellets (Swan and Swan, 1989). Blunt trauma, such as that produced by a bludgeon, fist, or hammer, or when an object is dropped on the hand or foot, results in crush fractures. The third type of crushing injury results when developing bone responds to the application of direct force. Examples of this last type are culturally mandated bone alterations, such as the shaping of immature cranial and foot bones by various types of binding for beautification.

Rarely, direct trauma injury that bruises a joint may fracture articular cartilage, and

sometimes the subchondral bone as well, causing separation of a fragment from the margin of the articular surface. This resulting lesion may be confused with osteochondritis dissecans, which is caused by aseptic necrosis and is usually seen as the complete or incomplete separation of a portion of joint cartilage and subchondral bone, most commonly on the femoral condyles. Osteochondritis dissecans is usually recognized in dry bone as a pit, often 2 to 5 mm in diameter, in the subchondral bone, although new bone formation may partially or completely fill the defect or may produce a deposit that exceeds the level of the normal articular surface. The etiology of osteochondritis dissecans is uncertain but indirect trauma is thought to play at least a contributory role.

**Indirect trauma.** When a fracture occurs in a place other than the point of impact it is said to result from indirect trauma (Miller and Miller, 1972). Oblique, spiral, greenstick, impacted, burst, and avulsion fractures are consequences of indirect trauma (Fig. 2). An oblique fracture, where the line angles across the longitudinal axis, is indicative of a combined angulated/rotated force (Harkess and Ramsey, 1991). If the fracture is well healed, this break is easily confused

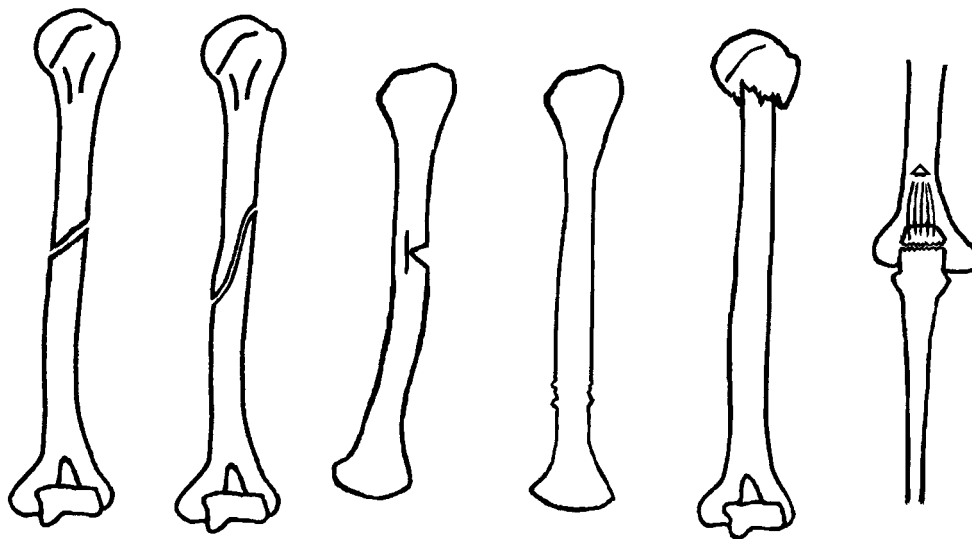


Fig. 2. Fractures caused by indirect trauma. From left to right: oblique, spiral, greenstick due to angular force, greenstick due to compression, impaction, and avulsion.

with a spiral line. A spiral fracture line winds down around a long bone shaft due to a rotational and downward loading stress on the longitudinal axis. In some cases, such a force applied to the tibia results in a fracture-dislocation of the ankle rather than a spiral fracture (Harkess and Ramsey, 1991); at other times, the force results in an associated proximal fibular fracture.

Torus or greenstick fractures result from bending or buckling of bone when stress is applied. These often are due to indirect trauma and are most commonly seen in children, whose bones are still pliable and hence less likely to break, instead producing a localized bulging on the bone. An example is a greenstick fracture of the clavicle that results during childbirth when the child's biacromial breadth is too large to pass easily through the mother's pelvic outlet. Greenstick fractures are also characterized by an incomplete fracture involving only the convex side of a bone that has been subjected to bending stress. In adults the ribs are commonly affected.

Less common fractures resulting from indirect trauma are impacted, avulsion, and burst fractures. An impacted fracture occurs when the bone ends at a fracture site are driven into each other by the force of injury.

Clinically, this is often seen in the proximal humerus as the result of a fall onto an outstretched hand, and in the metacarpals as a result of trauma to the fist when punching. An avulsion fracture is caused when a joint capsule, ligament, or tendon is strained and pulls away from its attachment to the bone, tearing a piece of bone with it. A particular type of avulsion fracture leaves a transverse fracture line: a transverse fracture may occur to the ulnar olecranon process or the patella if the extensor muscles contract forcefully while the joint is flexed, and in extreme cases the bone fragments will separate and may heal without uniting.

A burst fracture is located in the spine. It results from a vertical compression that ruptures the intervertebral disc through the vertebral end plate, forcing disc tissue into the vertebral body (Fig. 3). A mild form of this injury is often seen in archaeological specimens as a small, localized, typically circular, depression in the end plate that is usually called a "Schmorl's node."

Comminuted fractures may be due to indirect trauma as well as to direct trauma. The indirect comminuted fracture is patterned like a "T" or "Y," and is produced by a force that passes through the bone, splitting it in several directions (Perkins, 1958). Crush

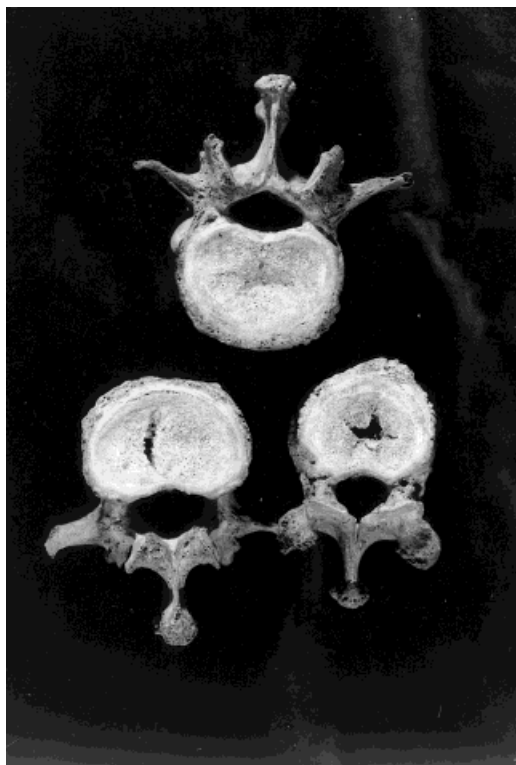

Fig. 3. Burst fractures of the lumbar vertebrae in a young adult male from the historic Fur Trade period in Alberta.

fractures also can be found as a result of indirect trauma, such as in the calcaneus after a person has jumped from a height.

**Stress fractures.** Repetitive force can result in a stress or fatigue fracture. The usual areas of occurrence are the metatarsal, calcaneus, and tibia (Wilson and Katz, 1969). Stress fractures in the metatarsals are sometimes referred to as "marching" fractures, since they are often diagnosed in military cadets. Those in the tibia have been known for some time to affect dancers, while the increased interest in jogging and aerobic dancing in recent decades as well as the adoption of alternative religious practices has led to their higher prevalence in other segments of western society (Burrows, 1956; Cohen et al., 1974). The fracture line is usually perpendicular to the longitudinal axis, therefore problems may arise in trying to distinguish between stress and direct

trauma transverse injuries. Commonly a stress fracture will be visible as a nondisplaced line or crack in the bone, called a hairline fracture, which is not detectable radiologically until a bony callus has formed over the break.

**Fractures secondary to pathology.** Fractures often occur secondarily to a disease already present in the body. Systemic diseases such as metabolic disturbances and nutritional deficiencies leave bone vulnerable to spontaneous fracture or to fracture from minor trauma. For example, postmenopausal females may suffer fractures if their bones have been weakened by osteoporosis. Other skeletal markers of specific disease may aid in attributing cause to the fracture: neoplastic fractures are seen when the break is through or adjacent to a tumor that is in, or of, bone, and the collapse of vertebral bodies is not an uncommon consequence of tuberculosis in the spine (Pott's disease).

#### Fracture healing

**Duration of healing.** Fractures begin to heal immediately after the bone is broken, but the process differs for cancellous and tubular bone. Most investigators identify five overlapping stages in tubular bone healing (Adams, 1987; Apley and Solomon, 1992; Paton, 1984). Table 3 summarizes the activities of these stages and the approximate time after injury that each is observed. Healing normally is not visible on radiographs until approximately 2 to 3 weeks after the injury, when a callus of woven bone, the result of cell proliferation from the periosteum, marrow cavity, and surrounding connective tissue, appears around the site of injury. The callus internally and externally bridges the gap caused by the fracture and stabilizes the fractured ends. Consolidation of this woven bone into mature lamellar bone occurs subsequently, but the duration of the process depends upon the nature of the fracture and the type of bone involved. In a phalanx, a solidly united fracture may develop in less than 1 month, while the same transformation may take up to 6 months in a tibia or femur. Bones of the

TABLE 3. The process and duration of fracture healing in tubular bones  
(Adams, 1987, Apley and Solomon, 1993, and Paton, 1984)

Healing stage	Healing processes	Duration
Haematoma formation	Blood from torn vessels seeps out and forms a haematoma	24 hours
Cellular proliferation	Fractured bone ends die due to lack of blood supply	3 weeks
Callus formation	Osteoid is deposited around each fragment by osteoblasts of periosteum and endosteum and pushes haematoma aside	
	Fracture is bridged; visible in dry bone	
	Callus of woven bone forms from mineralization of osteoid and acts as a splint for periosteal and endosteal surfaces	3 to 9 weeks
Consolidation	Visible radiologically	
	Mature lamellar bone forms from callus precursor and results in a solidly united fracture area	Varies by skeletal element from a few weeks to a few months
Remodelling	Gradual remodelling of bone to its original form, strengthening along lines of mechanical stress	6 to 9 years
	Increased density on radiographs marks the fracture site on adult bones	

upper limb tend to heal faster than do those of the lower limbs, and spiral and oblique fractures heal faster than do transverse fractures.

In contrast to compact tubular bone, cancellous bone has a meshlike structure with no medullary canal. This provides a much larger area of contact between fracture fragments, which facilitates healing. In addition, this mesh can be more easily penetrated by bone-forming tissue than can compact bone, so the union occurs directly between bone fragments instead of indirectly via the periosteal and endosteal callus. The initial haematoma is penetrated by proliferating bone cells which grow from opposing fracture surfaces. The developing tissues fuse when they meet and subsequently calcify to form woven bone. Healing is thus simpler and faster in cancellous bone than in compact bone.

Because there is a delay before healing is visible macroscopically or radiographically, it may be difficult to distinguish some post-mortem breaks from unhealed pre-mortem fractures. Perimortem fractures is the term given to such injuries, which may have occurred in the recent antemortem period (i.e., up to 3 weeks before death) and are therefore unhealed, or that alternatively may have occurred in a postmortem period that is of indeterminate length (perhaps weeks or months) but during which the bone is still relatively fresh and its organic components not yet deteriorated. Otherwise, distinguishing between antemortem/perimortem trauma and that which clearly occurred

after death is predicated upon the different fracture properties associated with bone that retains its viscoelastic nature and bone that does not, and upon the different appearances of bone surfaces after various post-mortem intervals (Buikstra and Ubelaker, 1994; Maples, 1986; Mann and Murphy, 1990; Ubelaker and Adams, 1995). Antemortem or perimortem fractures can be identified by 1) any evidence of healing or inflammation; 2) the uniform presence of stains from water, soil, or vegetation on broken and adjacent bone surfaces; 3) the presence of greenstick fractures, incomplete fractures, spiral fractures, and depressed or compressed fractures; 4) oblique angles on fracture edges; and/or 5) a pattern of concentric circular, radiating, or stellate fracture lines. Post-mortem fractures, in contrast, tend to be characterized by 1) smaller fragments; 2) nonuniform coloration of the fracture ends and the adjacent bone surface, especially light-colored edges; 3) squared fracture edges; and 4) absence of fracture patterning due to the increased tendency of dry, brittle, bone to shatter on impact.

**Complications of healing.** Complications should be assessed when examining fractures because they may provide information regarding mobility, morbidity, mortality, and medical treatment or the lack thereof. In addition to the fracture types described above, the relationship of the fracture to surrounding tissue is referred to as "closed" or "open." When the fractured bone does not come into contact with the outer

surface of the skin, the fracture is termed closed. An open fracture, also known as a compound fracture, is when the bone protrudes through the skin or the skin is broken to the level of the bone, as in a crushing or penetrating wound. Open fractures are prone to infection, which hinders the union of the fracture and creates instability. A pathogen, *Staphylococcus aureus* in about 90% of clinical cases (Ortner and Putschar, 1981), may be introduced to the body through an open fracture from surface contamination or from a penetrating instrument or contaminant. Although there is a tendency to regard localized infections as related to observed fractures, but to interpret nonlocalized infections as unrelated to fracture, posttraumatic infection may in fact be present either as a localized condition or, due to hematogenous dissemination of the pathogen, as a systemic infection. Whether localized or systemic, if the body's immune system is unable to combat the infection successfully bony response is usually visible in the form of periostitis (an inflammation of the periosteum) or osteomyelitis (a more severe bone infection that involves the medullary cavity). Periostitis is usually characterized by focal periosteal bone deposition that may eventually form a plaque-like sheet over the cortex. Osteomyelitis is identified by a thickened contour in the area of the fracture and the bone may feel heavier. Pathognomonic evidence of osteomyelitis results from the development of subperiosteal abscesses that deprive the bone of its blood supply and lead to necrosis (the dead bone forms a sequestrum). The periosteum continues to produce new, hypervascular bone around the sequestrum, forming a shell of bone called involucrum. The subperiosteal pus must escape through the involucrum to the skin surface, however, and in doing so forms one or more sinuses (cloacae) in the involucrum for pus drainage. In dry bone the sequestrum, lying under the involucrum, may be visible through a cloacal opening. Posttraumatic osteomyelitis is most commonly observed in the cranium and long bones of archaeological skeletons.

Fractures inevitably result in the rupture of minor blood vessels but this is not usually a serious complication. In some cases, however, bone displacement can compress or

twist blood vessels and lead to ischemia. This will delay the healing process and could lead to bone death if unrelieved. Avascular necrosis normally occurs near the articular ends of bones where the blood supply to subchondral bone is limited. Death of the tissue begins a week after the nutrient supply is reduced and may continue for up to 4 years. During this time the bone loses its trabecular structure, becomes granular, and begins to disintegrate due to muscle stress or body weight. The adjacent articular cartilage also dies as a result of deficient nourishment, usually resulting in osteoarthritis.

Nerve injuries also may be associated with fractures. Three types of nerve injuries are generally recognized. Damage is slight in neurapraxia and results in temporary impairment that corrects itself within a few weeks. In contrast, the internal nerve architecture is preserved but axons are badly damaged in axonotmesis, resulting in peripheral degeneration that may take many months to heal. Such a lesion may result from pinching, crushing, or prolonged pressure. The most serious type of nerve injury, neurotmesis, involves complete division of a nerve, either through severing or severe scarring, and requires surgical repair. The consequences of these types of nerve injuries range from loss of sensation to loss of function. Usually the loss is temporary, but muscle atrophy may result and if the nerve loss is prolonged or permanent the bones will display signs of disuse atrophy as well. This sequel would be most likely in archaeological cases of neurotmesis. In addition, if there is loss of innervation to the fracture site, the individual will not feel pain and may therefore continue to use the broken bone, impairing healing. Fracture of the vertebral column may result in damage to the spinal cord or spinal nerves, with paralysis below the level of the injury a possible outcome. Depressed skull fractures with endocranial displacement are usually associated with significant brain injury, which must also be considered in cases of linear fractures of the cranial vault.

Another complication is posttraumatic ossification of a haematoma, which results when absorption of the haematoma is prevented by excessive stress placed on the



periosteum. A smooth mass of bone is macroscopically visible after 2 months, with calcification being visible radiologically a few weeks after the injury. Although usually benign, movement may be restricted if there is joint involvement.

If joint function is affected by traumatic injury, osteoarthritis may develop as a complication. Stiffness caused by fibrous adhesions or joint swelling may lead to prolonged disuse of the joint or limb. Shortening or angulation may result in some loss of normal function in the affected limb or in the joints directly above and below the fracture; this may be difficult to interpret since unusual biomechanical stress at a joint in which a fractured bone participates may cause osteoarthritis, but it is also possible for a joint on an uninjured limb to be affected. The latter might occur, for example, if weight bearing was shifted in order to favor the injured leg. Premature deterioration of articular cartilage and subsequent deterioration of subchondral bone are common complications of breaks affecting the joint surface itself, since cartilage repair is a very slow process. Such fractures also can result in ankylosis of the joint.

Three final complications of fractures are delayed union, nonunion, and malunion. In clinical settings the union of a fracture is defined as delayed if it has not occurred in the time expected for that skeletal element, age, and sex of the individual, and it may eventually be classed as a nonunion. In dry bone specimens, of course, delayed but eventually successful union cannot be distinguished from undelayed union. Several factors may impede the process of healing, but overall poor health and/or nutrition in ancient populations may be a largely unrecognized contributor (Grauer and Roberts, 1996).

The diagnosis of nonunion is applied when the fracture fragments fail to unite and the marrow cavity seals. Radiologically, nonunion may be identified by sclerosis at the bone ends. After a prolonged period of time, the fragments take on a rounded appearance at their ends, which are connected by fibrous tissue. Nonunion may result from inadequate bone healing due to infection, inadequate blood supply, insufficiency of vi-

tamin D or C or of calcium, excessive movement between bone fragments during healing, soft tissue being caught between the fragment ends, inadequate contact between the fragments, presence of foreign material, or from the destruction of bone due to pathology or the injury itself (Altner et al., 1975; Karlstrom and Olerud, 1974; Sevitt, 1981; Stewart, 1974; Urist et al., 1954; Yamigashi and Yoshimura, 1955). If there is persistent movement between the ununited ends, a pseudarthrosis, or false joint, may form, although this complication is relatively rare (Stewart, 1974). Studies of modern human populations indicate a frequency of pseudarthrosis of less than 5% (Heppenstall, 1980; Urist et al., 1954), while an examination of data from temporally, geographically, and culturally diverse archaeological populations reveals an average frequency of 2% (Burrell et al., 1986; Jimenez, 1994; Lovejoy et al., 1981; Stewart, 1974). Among alloprimates, data from Bramblett (1967), Jurmain (1989), Lovell (1990), and Schultz (1937, 1939) also give an average pseudarthrosis frequency of approximately 2%.

A malunion consists of a fracture that heals leaving a deformity. This may occur when a fracture has not been reduced or when reduction was not maintained, leaving the fragments to heal grossly angulated or excessively shortened. Shortening is caused by overlap, substantial angulation, crushing, or gross bone loss. Injuries to growing bone that affect the epiphyses and lead to premature fusion of the growth plate may result in shortening, as may bone infarction resulting from sickle cell disease, which most often affects the epiphyses of the growing skeleton, especially those of the proximal femur. The presence of a shortened bone is most detrimental to the lower, weight-bearing limbs, although a difference of up to 20 mm is considered by clinical practitioners to be tolerable. A greater loss in length can lead to backache from pelvis tilting and lateral and rotational spinal deviation. Recent studies have interpreted minimal deformity in bones that are likely to be severely affected when fractured as evidence for immobilization of the injured part and possible medical treatment (Grauer and Roberts, 1996).

### DESCRIPTIVE PROTOCOLS FOR FRACTURES

Proper description of an injury is the first step in trauma analysis (Ortner and Putschar, 1981; Steinbock, 1976) and is the basis for determining the mechanism, or proximate cause, of the injury. In turn, an understanding of the proximate cause is crucial for the identification of the ultimate cause of trauma, usually behavior. Proper description of observed lesions also provides other scholars with an opportunity to agree or disagree with the diagnosis and/or inferences that are made about the sociocultural or environmental context of the injury. Although several models proposed recently have made great strides in standardizing descriptive protocols (e.g., Buikstra and Ubelaker, 1994; Dastugue and Gervais, 1992; Grauer and Roberts, 1996; Roberts, 1991), paleopathologists have not yet reached a consensus on descriptive standards for trauma and many are not always familiar with the underlying mechanisms of injury. Ideally, any method of fracture description will recognize two main sources of confusion in interpretation: the variation in appearance expressed by fractures caused by the same mechanism of injury, as well as the similarities in appearance displayed by fractures caused by different mechanisms of injury. Ultimately, proper fracture description should seek to improve the accuracy and reliability of interpretation without exceeding the limits of inference that are set by the descriptive data themselves.

Although fracture types are here subsumed under their proximate cause, when describing and interpreting injury the fracture type is usually recognized first. Identification of the mechanism of injury then follows logically, and the third step in trauma analysis involves interpretation of the ultimate cause of the injury. For example, an impacted fracture of the distal radius with posterior displacement of the distal fragment may be recognized as a Colles' fracture due to its characteristic location and deformity. The proximate cause of the injury may then be identified as indirect trauma. Interpreting the ultimate cause may be difficult, but a fall onto the outstretched hand would

be a logical conclusion. If the fracture was observed in an older female, the possibility of the fracture occurring secondary to osteoporosis could also be considered.

The principal aim of most protocols has been to establish standardized descriptions for fractures observed in dry bone, although additional objectives, such as the evaluation of evidence for treatment of traumatic injuries are sometimes also stated (e.g., Grauer and Roberts, 1996; Roberts, 1991). Three recently developed protocols are outlined here.

The repatriation of Native American prehistoric and historic skeletal remains drove the development of standards for data collection that includes procedures for documenting fractures (Buikstra and Ubelaker, 1994). These procedures recognize nine types of fractures and eight varieties of shape characteristics. All types and varieties are not mutually exclusive, but may have restricted application. Shape characteristics, for example, describe lesions caused by blunt or sharp force and by projectiles, as well as radiating fractures and amputations. Perimortem fractures are identified at a third level of description, followed by sequelae such as healing status and various complications. Dislocations are classed separately. The recommended data collection forms and descriptive protocol do not provide for malunion as a component of fracture description specifically, but rather under the pathology category of "abnormality of shape," in which malunion would be identified as either barely discernable or clearly discernable angulation.

A second method was designed specifically to describe fractures in a way that would provide the information necessary to examine the technology and knowledge of treatments in past societies (Grauer and Roberts, 1996; Roberts, 1991). The method describes the location and type of fracture and emphasizes evaluation of the success of long bone healing. Macroscopic and radiographic means are employed to assess complications of shortening and deformity, and sequelae such as infection and osteoarthritis. Skull fractures are described as resulting from blunt or sharp force and are evaluated in terms of healing as well as evidence for trepanation. The need for radiographic

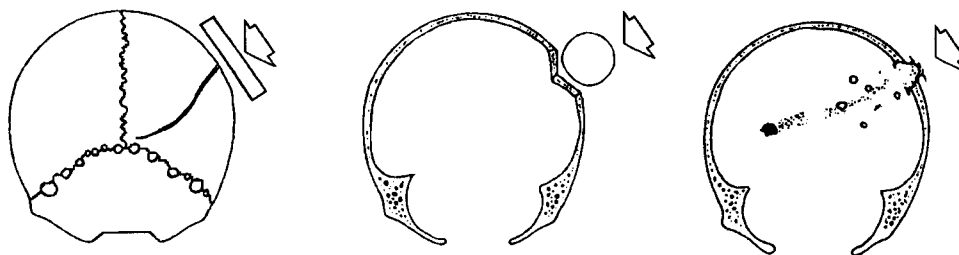


Fig. 4. Common fractures of the cranial vault. From left to right: simple linear fracture due to blunt trauma, comminuted depressed fracture due to blunt trauma, and comminuted penetrating fracture from a high velocity projectile.

evaluation of fractures in order to determine the amount of healing and the particulars of deformity and/or displacement is stressed, as is the importance of radiography for detecting and interpreting well-remodelled fractures (Grauer and Roberts, 1996; Roberts, 1991). Unfortunately, radiographic equipment is not always available, especially in field settings, and the interpretation of radiographs may be made difficult by postmortem alterations common in archaeological contexts, such as soil inclusions that affect density or the differential identification of osteoporosis versus diagenetic bone loss (Roberts, 1991).

Finally, a third system concerns cranial vault injuries, categorizing them as piercings, depressions, gashes, cuts, and slices (Filer, 1992). The first category is described as consistent with a penetrating injury, the second with blunt force trauma, and the last three as resulting from edged/bladed implements, including sharp projectiles. The majority of these lesions were interpreted as resulting from interpersonal violence, an assessment not inconsistent with the apparent culture-historical context of the remains.

It is likely that no one system of fracture description will suit all investigators, since some will be more or less concerned with the affected body part, specific complications, or possible causative behaviors. Most protocols, however, share similar basic categories of description. The method for fracture description that is presented below incorporates these categories in a system adapted from clinical and forensic medicine. It is predicated on identification of the skeletal element(s) involved and the type of injury, as

well as detailed descriptions of deformation and of any associated nontraumatic lesions that may indicate causality or postinjury complications. The information thus obtained then serves as a basis for inferences about the mechanism of injury, which can in turn provide clues as to the social, cultural, or environmental associations of the injury. The method outlines descriptive features for cranial and long bone fractures since these predominate in the paleopathological literature.

#### Description of cranial fractures

The interpretation of the mechanism of injury of cranial fractures relies on a variety of characteristics of the fracture, such as the bones involved, patterning of fracture lines, and presence of deformation (Gurdjian, 1975; Gustilo, 1991; Hooper, 1969; for a comprehensive discussion of lesions of the calvarium, see Kaufman et al., 1997). Stress fractures and fractures secondary to pathology are uncommon in the cranium. The most common fractures of the cranium affect the vault and are caused by direct trauma. These can be described according to their basic type, usually linear, crush, or penetrating (Fig. 4), which are not necessarily mutually exclusive. Although vault fractures are most common, the base, maxillae, nasal bones, orbits, and/or zygomae may be fractured alternatively or additionally, and the temporomandibular joint may be traumatically dislocated.

Low velocity, blunt trauma to the head may result in simple linear fractures or depressed (crush) fractures. The kinetics involved may relate to acceleration injuries,

in which the head is struck by an object and set in motion, or deceleration injuries, in which the moving head suddenly comes to a halt. In either case, the curve of the skull at the point of impact tends to flatten out, and as a result the force of the impact is distributed over a relatively large area. The bone surrounding the area of impact bends outward, and, if the deformity of the cranium is great enough, fracture lines begin, usually in the areas subjected to bending outward. The areas of bending are not uniformly circular, since the degree and direction to which the fracture lines extend depends upon both the magnitude of the applied force and the local bony architecture.

Penetrating injuries of the cranium are characterized by a small area of impact with a localized area of distortion and are usually caused by sharp-edged objects or projectiles. With higher velocity impact, the inbending of the skull remains localized but the depth of penetration increased. As a general rule, when the area of impact decreases the stresses are more localized but greater in magnitude and the stresses in surrounding areas diminish. The severity of impact in direct cranial trauma is usually determined from the extent and separation of linear fractures, by the extent of comminution of a localized fracture, or by the displacement of bone fragments in penetrating wounds.

Indirect trauma injuries are relatively rare, but may result from vertical loading forces transmitted from the feet or buttocks when a person falls from a height. A basilar "ring" fracture around the foramen magnum is an example of such an injury; it reflects impact forces transmitted up through the cervical spine and occipital condyles. Basilar fractures through the petrous bones and fractures of the mandibular condyles have been observed to result from impact to the chin (Harvey and Jones, 1980).

#### Description of long bone fractures

In contrast to fractures of flat and irregular bones, fractures of appendicular long bones (and, by extension, short bones) often require more comprehensive description since their positions in the skeleton and their functions make them more susceptible to a variety of forces. Long bone fractures

from archaeological contexts can be described in a manner adapted from that used in clinical orthopedics (e.g., Gustilo, 1991; Harkess and Ramsey, 1991; Schultz, 1990) and can be first classified as intraarticular (involving a joint, including the metaphyseal region) or extraarticular. Intraarticular fractures are described as either linear, comminuted, or impacted. Extraarticular fractures are described as linear, comminuted, or segmental.

Linear fractures fall into three subtypes, transverse, oblique, and spiral, all of which have been previously described. Comminuted fractures are categorized according to the size of the fragments (multiple or "butterfly") and the percentage of the shaft (<50% or >50%) that is involved. A butterfly fracture is formed from a combination of compression and tension stresses that result in the separation of a triangular fragment of bone. Segmental fractures are identified by the multiple fracture lines that divide the bone into at least two segments along a longitudinal axis. The location of the fracture should be noted as occurring at the proximal end, distal end, or shaft (either the proximal, middle, or distal third of the shaft or one of the junctions thereof).

The final components of long bone fracture description are length, apposition (shift), rotation, and angulation (alignment), identified by the acronym, LARA. Convention decrees that when describing the four components the distal fragment is measured in relation to the proximal fragment. The principal aims here are to describe fractures so that the mechanism of injury can be deduced, and to distinguish fractures with no or slight deformity from those with marked deformity.

*Length* of the bone is measured with an osteometric board and the maximum length is recorded (per Bass, 1987). Length is recorded as normal, distracted, or shortened, and is determined by comparing the injured bone to its counterpart, if possible. Distraction is a lengthening of the bone and is caused by the separation of bone fragments, often due to muscular forces. Bones themselves may distract a fracture, however, such as when an intact ulna pulls apart the fragment ends of a fractured radius or when

a fractured tibia is associated with an intact fibula. Distraction also may be caused when tissue is caught between fragment ends. In contrast, shortening results when muscular forces pull the fragments over each other. This typically occurs when broken bones have not been set, often due to severe pain or muscle spasm, or if a fracture reduction failed because of instability.

*Apposition* is the percentage of bony contact between fragment ends in fresh injuries and is measured on radiographs. Apposition from an x-ray is measured using a ruler and is expressed as a percentage, the horizontal displacement being a function of the surface area of bone. Therefore, if there is no horizontal displacement between the fractured bone ends when healed, that is, the bone ends are in perfect alignment, the bone is 100% apposed. In dry bone, however, shifting of the distal fragment in relation to the proximal end can be recorded in the absence of radiographs. If the bone is viewed in anatomical position, a medial or lateral shift may be seen; if viewed in a lateral position, anterior or posterior displacement may be observed. The shift in both the anteroposterior (AP) and lateral planes should be noted, as the bone can be displaced in both directions.

*Rotation* occurs when the distal fragment has turned relative to the proximal fragment. There is no measurement, but the distal portion is recorded as being internally or externally rotated. This is usually easily identifiable in dry bone, especially if the affected bone can be compared to the contralateral element. If rotation is observed, the adjacent joint surfaces should be examined since rotation may result in osteoarthritis, or in ankylosis of a joint if ligaments were torn in the injury.

*Angulation* at the fracture site is measured in degrees with a goniometer. This measurement is easily obtained from a radiograph but also may be obtained from the bone. One end of the goniometer is placed on the midline of the proximal fragment's longitudinal axis, the other end on the axis of the distal fragment with the center of the goniometer directly over the fracture site. The number of degrees the distal fragment has displaced in relation to the midline of the proximal fragment is the angulation. The

direction of movement must also be noted. In the AP view, the distal portion of the distal fragment will move medially (varus) or laterally (valgus). In the lateral view, anterior angulation refers to the distal portion of the distal fragment moving anteriorly so that the fracture site appears posteriorly bowed. Posterior angulation refers to the distal portion of the distal fragment moving posteriorly; the fracture site appears anteriorly bowed. Degree and direction of angulation should be measured in the AP and lateral positions as both planes are often affected.

### Examples of long bone fractures

The value and application of standardized fracture descriptions is illustrated here with the description of radiographs from four clinical cases at the University of Alberta Hospital in Edmonton. With known mechanisms of injury, treatment, and follow-up, these cases unambiguously illustrate the skeletal effects of trauma and their variability of expression. For each set of radiographs, fractures were noted for their type, the bone(s) involved, area of involvement, degree of healing, length, apposition, rotation, and angulation. Apposition data are reported to  $\pm 5\%$ . The measurement of angulation was found to be the most problematic and consequently all angulation data are presented to  $\pm 2^\circ$ .<sup>3</sup> The sex and age of each patient were recorded although other personal, identifying information was not revealed. Although the degree of deformity is sometimes used to assess the existence and/or quality of medical treatment in the past, these examples reinforce the observation that the association is not always direct (Grauer and Roberts, 1996). Fracture injuries often improve with time but conversely they may deteriorate and individual responses to fracture vary widely.

A direct trauma transverse fracture resulted when a 20-year-old male was kicked in the shin while playing soccer. Figure 5a is a lateral view radiograph taken immedi-

<sup>3</sup>In order to evaluate interobserver error all clinical cases were independently scored by N. Lovell and C. Prins. The error in measured length as  $\pm 1$  mm; in apposition  $\pm 5\%$ ; and in angulation  $\pm 2^\circ$ ; all adequate for distinguishing between none, slight, and marked deformity.

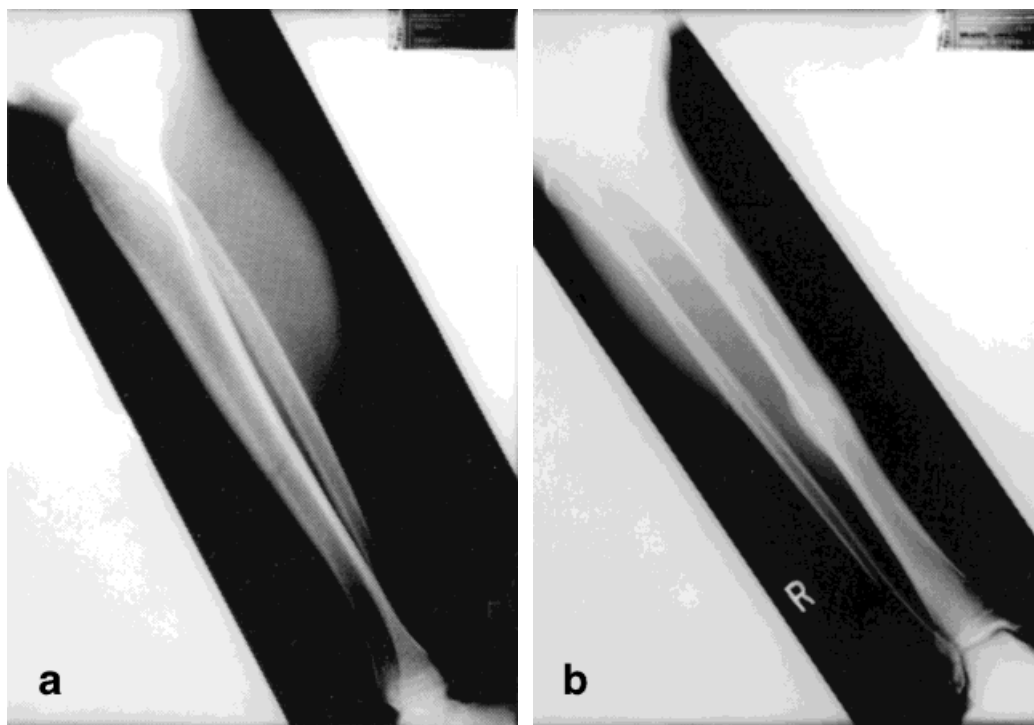


Fig. 5. Transverse fracture due to direct trauma. **a:** Radiograph taken immediately postinjury, showing a transverse midshaft fracture without fibular involvement. **b:** Radiograph taken more than 5 months later, showing callus around the fracture site.

ately postinjury that shows a transverse, midshaft tibial fracture with no fibular involvement. The bone was perfectly aligned on both the initial x-rays and those taken more than 5 months later (Fig. 5b). The degree of callus formation may appear to those who are inexperienced with clinical cases to be excessive, given the apparent lack of angular deformity, displacement, or comminution, but this example is fairly typical of such injury. Not all transverse fractures heal as nicely, however, and nonunion, despite good alignment, may often occur in the tibia and/or fibula due to their inherent instability when supporting the body's weight in locomotion.

In some cases fractured bones heal well in one dimension, only to deteriorate in another. Initial radiographs of a 24-year-old male injured in a motor vehicle accident showed a transverse fracture at the junction of the mid and distal thirds of the left tibia, with two fibular fractures, one at the same

level as in the tibia and another at the proximal end of the shaft. Both tibia and fibula were in perfect alignment when viewed anteroposteriorly immediately after the injury, although 3° of posterior angulation of the tibia was noted in the lateral view. Figures 6a and 6b were taken more than 4 months after the injury and the fracture lines are still visible. In the AP view, the tibia has now shifted laterally by about the width of the bone cortex, and shows 4° of valgus angulation. The midshaft fibular fracture also displays 4° of valgus in the AP plane. The lateral view, however, now shows the tibia in good alignment. Although the effects of high velocity vehicular accidents may appear to have little relevance to archaeological remains, multiple fractures of this type have been noted in historic cases of injury in horse-drawn cart and carriage accidents, and this case has obvious relevance for modern forensic investigations of dry bone lesions.

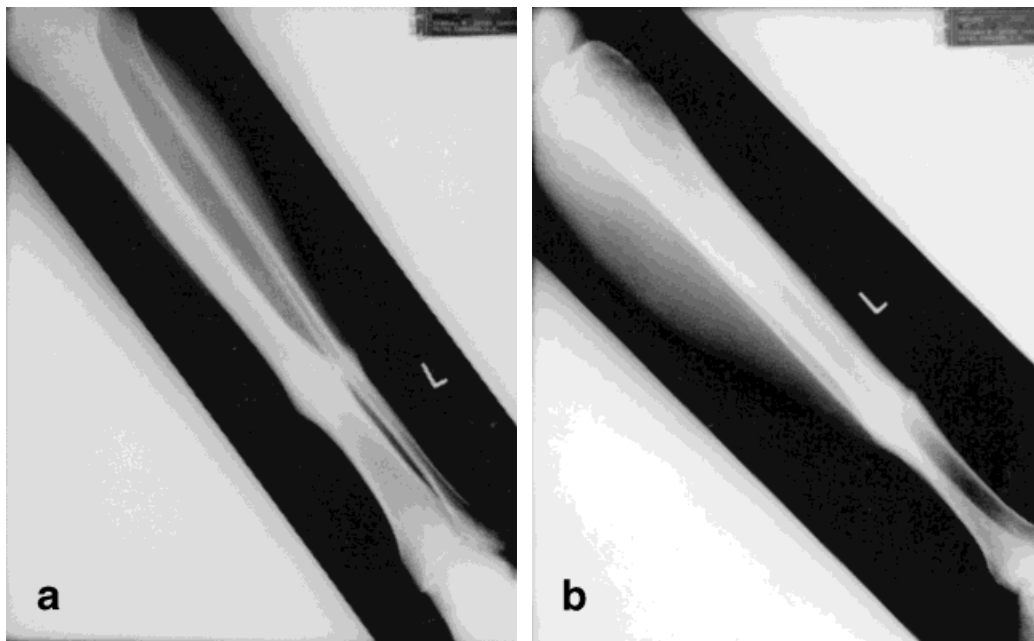


Fig. 6. Single tibial fracture with double fibular fracture. These radiographs were taken more than 4 months postinjury and the fracture lines are still visible. **a:** Anterior view. **b:** Lateral view.

Figure 7a is an immediate postinjury x-ray of a 54-year-old male who fell and suffered oblique, midshaft fractures of the right tibia and fibula. In the AP view there is  $11^\circ$  of valgus angulation in the tibia and  $13^\circ$  of valgus angulation in the fibula. The lateral view shows 10 mm of shortening in both the tibia and fibula and  $1^\circ$  of posterior angulation in the tibia. Both bones have shifted anteriorly about the width of the bone cortex. Figures 7b and 7c were taken 6 months later. The fracture lines are still very evident, little callus is seen, and the fragment ends are rounded, suggesting nonunion in both bones. Shortening has lessened to 6 mm in both the tibia and fibula. On the AP view the tibia retains  $11^\circ$  of valgus angulation but the fibula now displays only  $4^\circ$  of valgus. In the lateral view, posterior angulation in the tibia has increased to  $4^\circ$ ,  $1^\circ$  of posterior angulation is seen in the fibula, and both bones retain their anterior shifting.

A good example of a rotation injury with no fibular involvement is a spiral fracture of the distal third of the right tibia in a 12-year-old male who fell off his bicycle (Fig. 8). Callus is evident since the radiographs were

taken about 2 months postinjury, and on the AP view there is  $5^\circ$  of valgus angulation. The tibia is not shortened, probably because the intact fibula helped it maintain normal length. On the lateral view, there is  $6^\circ$  of anterior angulation in the tibia.

#### ANATOMICAL SUMMARY OF FRACTURES AND DISLOCATIONS COMMONLY SEEN IN ARCHAEOLOGICAL BONE

To aid the diagnosis of trauma according to the mechanism of injury, this section is organized as an atlas and describes those fractures and dislocations commonly seen in archaeological bone according to their anatomical location. The possible complications of the injury and their affects on healing also are described.

#### Cranium

Fractures of the bones of the cranium vary considerably, but perhaps the most commonly described are those involving the flat bones of the vault. Typically, the patterning of fracture lines on the cranium is correlated with the severity of the force: whether a

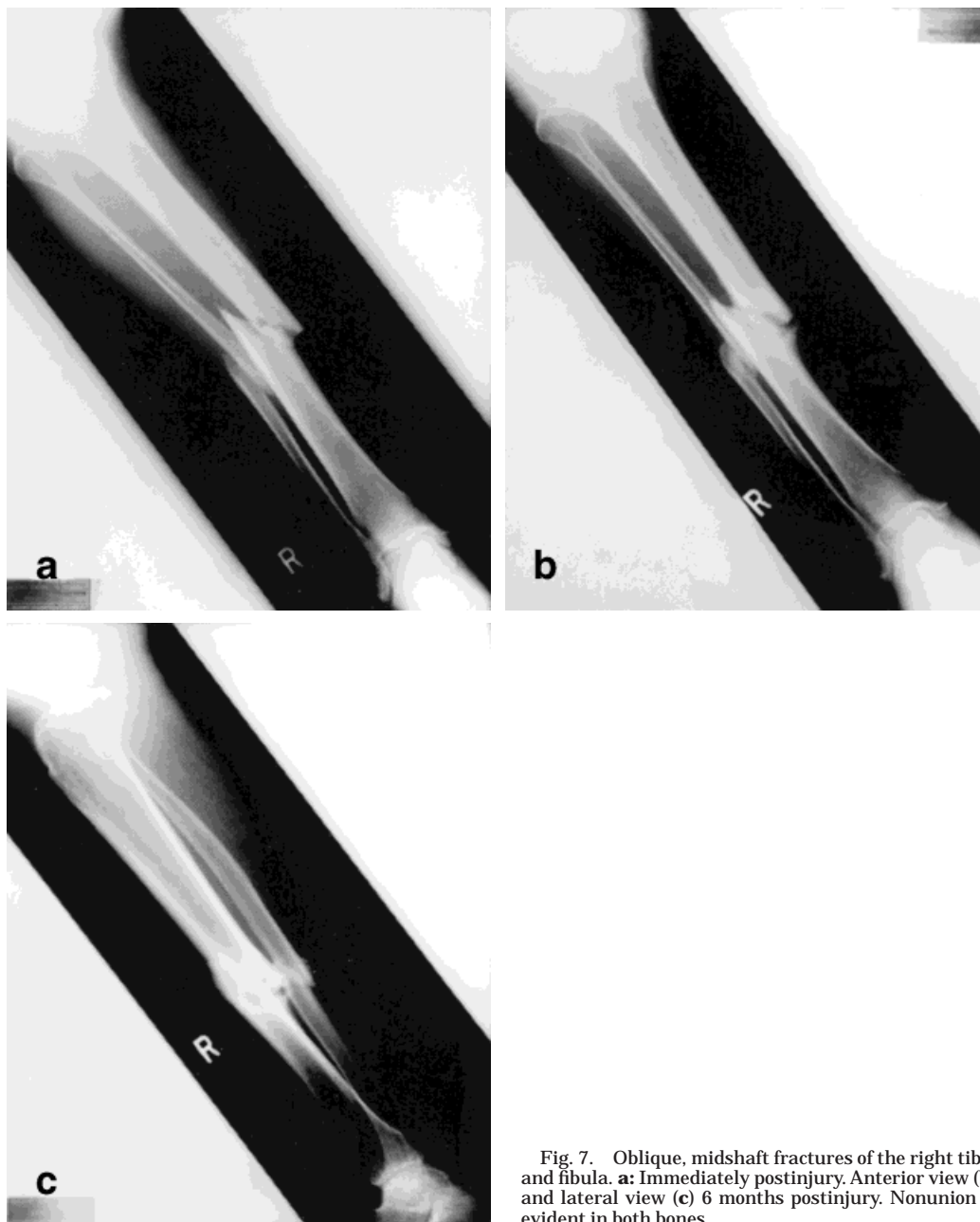


Fig. 7. Oblique, midshaft fractures of the right tibia and fibula. **a**: Immediately postinjury. Anterior view (**b**) and lateral view (**c**) 6 months postinjury. Nonunion is evident in both bones.

blow lands on the frontal, occipital, or parietal region, a single linear fracture line indicates less force than does a pattern of concentric and radiating stellate fracture lines (Gurdjian et al., 1950). The position of fracture lines can sometimes be used to identify the point of impact. Stellate, or

star-shaped, fracture lines form at the point of impact, for example, and radiating fracture lines run laterally, away from the point of impact. Concentric heaving fractures are caused by shearing forces and have characteristics, such as bevel angle, that can distinguish between high velocity and blunt



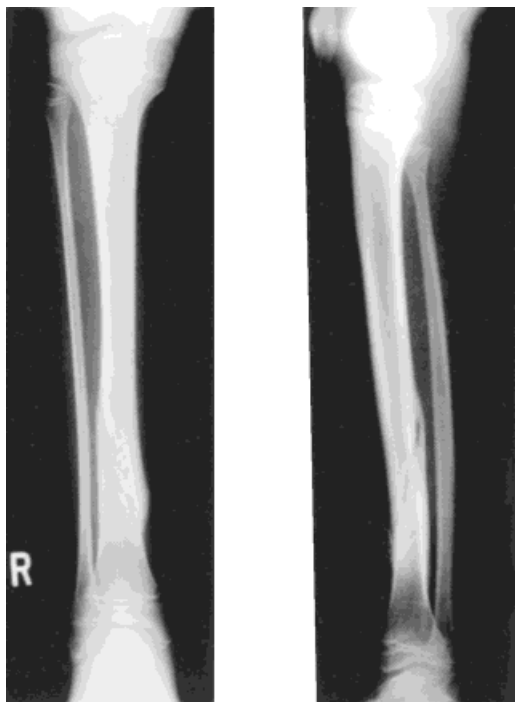

Fig. 8. Spiral fracture, 2 months postinjury. Anterior view is on the left and lateral view is on the right.

trauma injury (Berryman and Haun, 1996). With blunt trauma the concentric fractures are caused by force from outside the cranium, which leads to beveling on the inner table, whereas with high velocity projectile trauma the fractures are caused by pressure from within the cranium, which produces beveling on the outer table. Identification of the point of impact and the direction of the force becomes increasingly difficult with more severe trauma but the sequence of multiple impacts usually can be determined since a subsequently produced fracture will not cross a preexisting one.

Direct trauma injuries to the cranium often occur when the head is struck by a moving object. Trauma from high velocity objects, such as bullets and motorized vehicles, is seen commonly in clinical cases, but that from lower velocity objects (e.g., bricks, rocks, bludgeons, push carts, wagons) is also observed today and undoubtedly occurred in the past. Direct trauma to the cranium also occurs if the head strikes the ground after a fall or jump from a height or

when balance is lost after landing on the feet. These low velocity impacts usually result in linear fractures. Linear fracture lines tend to sweep around the thick, bony buttresses of the cranium (i.e., the petrous bones, mastoid process, etc.) unless they approach these areas perpendicularly. Since the structurally weak areas of the cranium are most prone to develop fracture lines, the unfused cranial sutures in children will readily separate to accommodate the forces of impact. Alternatively, in very young children the cranial bones may bend inward without fracturing and the depressed deformity may persist.

Clinically, blunt trauma injuries to the cranium usually cause linear fractures of the vault and the appearance of these fracture lines may help identify the point of impact and the mechanism of injury. Blunt trauma to the frontal bone, for example, produces fracture lines that radiate through the frontal sinus, the cribriform plate, and the orbital roofs, although transverse fracture lines affecting the temporal regions may also appear. Anterior temporal impact leads to fracture lines that radiate down, across either the orbital plate or the sphenoid-temporal region. In contrast, lateral or posterior temporal impact produces fracture lines that radiate downwards either in front of or behind the petrous portion of the temporal bone and extend across the cranial base. Impact to the occipital bone usually produces fracture lines that radiate down to the foramen magnum or the jugular foramen, and that may extend anteriorly across the cranial base. Trauma to the cranial base must be severe in order to cause a fracture, since the bone here is heavily buttressed. A base fracture is therefore considered to represent a severe injury.

After vault fractures, sphenoid fractures are the most common clinical result of blunt trauma to the cranium (Unger et al., 1990). Unfortunately, sphenoidal structures are very fragile and thus prone to postmortem damage as well as to fatal consequences of fracture and therefore it may be difficult to identify sphenoid fractures in archaeological skeletons. Facial fractures, either due to direct or indirect trauma, are often very complex but commonly heal adequately with-

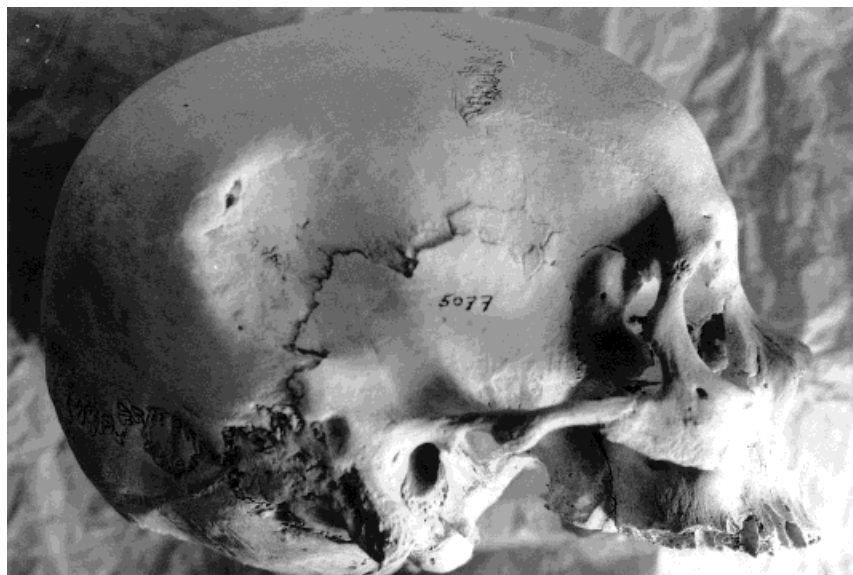


Fig. 9. Well-healed, crush fracture of the right parieto-temporal region.

out medical treatment. Since the zygoma, maxilla, and orbital margin are mutually supportive, a fracture of one of these bones usually involves a fracture of at least one of the others. Fractures of the nasal bones, while usually not severe, are not uncommon. These are often called depressed fractures (e.g., Filer, 1992) although this description refers to the observed deformity of the nasal bridge, not the type of injury. Clinically, interpersonal violence often produces small fractures of the nasal and zygomatic bones.

Crush fractures of the cranial vault are commonly seen in archaeological human remains and are caused by low velocity direct trauma (Fig. 9). Lesser force is indicated by the lack of displacement of bone fragments, while greater force is characterized by inward displacement. A portion of bone might be completely detached if great force is applied, particularly if the object has a small striking surface, but more often seen in archaeological remains is the incomplete detachment of the bone (Fig. 10). The fracture line on the ectocranium is usually irregular and may be comminuted, producing a cobweb or mosaic pattern. The depressed area indicates the point of impact, from which linear fractures radiate. Clinically, blows from hammers, fireplace pokers, and

the butt ends of axes are commonly responsible for incompletely detached depression fractures, as are falls onto the sharp edge of furniture or concrete steps (Polson et al., 1985).

Penetrating injuries of the cranium are caused by pointed and edged objects (e.g., knives, swords) or by bullets. Heavy cutting-edged weapons that are used in a chopping manner will produce crush injuries in addition to penetration, and further injury may be caused if the embedded weapon is removed with a twisting motion. This damage is often indicated by splintering of the bone with outward displacement near the initial impact site. The type and size of wound produced by a projectile depends upon the size of the projectile, the speed at which it strikes the bone, and the distance it travels. Historical skeletons may exhibit evidence of gunshot trauma, although these injuries would be less severe in terms of bone fragmentation and destruction than those typically found in a metropolitan trauma center today. Early musket balls, for example, had low velocity characteristics due to their spherical shape and the poor quality of gun powder (Butler, 1971). High velocity bullets (>3,000 ft/sec) were not developed until almost 1900, a date that usually places

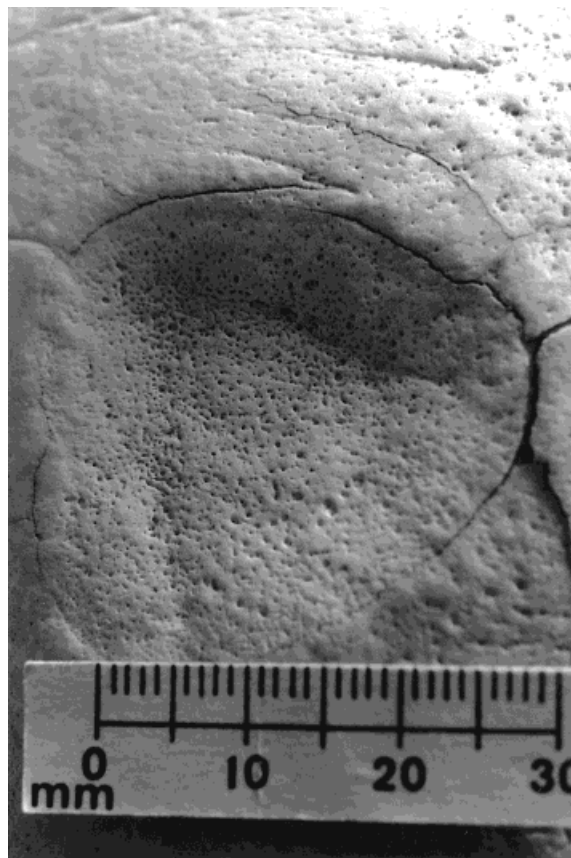


Fig. 10. Depression fracture of the cranial vault, showing radiating and concentric fracture lines. Probably due to low velocity blunt trauma.

human remains in a forensic rather than archaeological context. Details of the interpretation of modern gunshot wounds can be found in many textbooks on forensic medicine.

Possible complications of cranial fractures include displacement of bone fragments (malunion), indirect trauma injuries elsewhere on the cranium due to the transmission of impact force, and soft tissue damage. The location of the impact determines the subsequent consequences of the injury due to the different anatomical structures in the cranium. Linear fractures usually involve both the inner and outer tables of the cranium but do not involve displacement or depression of the bone and thus are often not considered as serious as those injuries resulting from greater force. Complications can arise, however, due to transmission of the

force of impact, such as when direct trauma to the back of the cranium produces indirect effects on the orbital plates. The consequences of cranial fractures can be fatal if the blood vessels running along the inner tables of the cranium (e.g., middle meningeal arteries) are torn, although this complication is unlikely to be detected with certainty in archaeological remains.

#### **Mandible**

The mandible forms what is essentially part of a "ring" structure, and therefore a fracture on one side is commonly accompanied by a balancing fracture on the other side. Usually the fracture affects the horizontal ramus or angle on one side and the condyle on the opposite side. Fractures at the angle very often communicate with the

roots of the distal molars. Very few mandibular fractures in ancient skulls have been described but fractures of the ascending ramus, mandibular angle, and condylar processes have been reported (Alexandersen, 1967). Asymmetrical tooth wear and osteoarthritis at the temporomandibular joint are possible complications of jaw fractures.

### Hyoid

Although the hyoid bone is not always recovered during archaeological excavations, a perimortem hyoid fracture is considered strongly suggestive of interpersonal violence through strangulation (Maples, 1986).

### Vertebrae

The most common fractures of the vertebrae are due to indirect trauma, preexisting disease, or stress. A very distinctive vertebral fracture is the traumatic separation of the neural arch from the vertebral body at the *pars interarticularis* (known as spondylolysis; Fig. 11), which appears to be a common consequence of habitual physical stress (Jimenez, 1994; Merbs, 1989a, 1989b, 1995, 1996). Although the spondylolysis seen most often in clinical settings is complete separation, comprehensive surveys of archaeological skeletons indicate that the condition begins as incomplete stress fractures in adolescents that may heal or, conversely, may progress to complete lysis by young adulthood (Merbs, 1995). The condition may be initiated by an acute overload event that causes microfractures, but it is generally agreed that the determining factor is chronic trauma, with repeated stressing promoting nonunion of the microfractures. These fatigue fractures appear to have the greatest populational frequency (approaching 50%) among arctic-adapted peoples following traditional lifeways, but clinically they are most often observed among athletes and laborers whose activities involve frequent and large stress reversals between lumbar hyperextension and lumbar flexion (Merbs, 1989b, 1996). Reported sex differences in the prevalence of the condition may be activity-related (Merbs, 1989b). Spondylolysis may be unilateral or bilateral in expression, but predominates in the lumbosacral region, particularly L5 and, to a lesser degree, L4



Fig. 11. Lumbar spondylolysis. This separation of the neural arch and the body at the *pars interarticularis* is usually attributed to a fatigue fracture.

(Merbs, 1996). Complete separation is frequently accompanied by anterior slippage of the vertebral body (spondylolisthesis), but functional complications of this are rare (Merbs, 1989b). A fracture with possibly a similar origin is the traumatic separation of the tip of the spinous process of the seventh cervical or first thoracic vertebra. Referred to as "clay-shoveller's fracture" (Roberts and Manchester, 1995), it may result from the strenuous muscle action associated with shovelling clay, cement, or rocks.

More common in archaeological vertebrae than stress fractures are indirect trauma injuries, such as Schmorl's nodes. These result from bulging of the disc's nucleus pulposus, which puts pressure on the vertebral end plate and leads to bone resorption in the affected area. Herniation of the disc tends to occur gradually in adults because the nucleus has lost resiliency, whereas it may occur suddenly in younger individuals

in whom the nucleus still quite gelatinous (Bullough and Boachie-Adjei, 1988). Indirect vertebral damage also can occur in a fall or jump onto the feet, since the force of impact is carried up from the lower limbs through the spine.

Fractures secondary to pathology are also common in the vertebral column. The best known clinical example is that of biconcave vertebrae, which result when intervertebral disks expand into the superior or inferior surfaces of vertebral bodies that have been weakened by osteoporosis.<sup>4</sup> Similarly, compression flattening of vertebral end plates due to sparse, coarse trabeculation in the vertebral body is a classic feature of sickle cell disease. Due to the greater strength of the rims of the vertebral end plates, they may be spared even when the vertebral body is compressed.

Although direct trauma injuries to the vertebrae are rare, hairline transverse fractures on, or posterior to, the superior articular processes of the second cervical vertebra are worth noting since they can result from strangulation (Maples, 1986).

### Ribs and sternum

Ribs are known to incur stress fractures, usually as a result of occupational or similarly habitual labor but sometimes as a consequence of persistent coughing or vomiting. Most often, however, rib fractures result from direct trauma, such as a blow or a fall against a hard object (Adams, 1987). Clinically, rib fractures are the most common type of thoracic injury and are observed in 60 to 70% of individuals admitted to hospital with blunt chest trauma (Carrero and Wayne, 1989). The direction of the impact usually can be determined from the location of the fracture, i.e., ribs are usually fractured near the angle if the force is applied from the front; beside the spine if the force is applied from the back; and beside both the spine and the sternum if the force is applied from the sides.

The fifth to ninth ribs are most often fractured (Fig. 12). Fracture of the first to third ribs and/or the sternum indicates that



Fig. 12. Multiple healed fractures of the left ribs. The location of the fractures, near the angle, suggests that the force was applied from the front.

the mechanism of injury was a high kinetic force. Due to the flexibility of the rib cage, particularly in the anteroposterior dimension, the degree of inward displacement at impact may have been much greater than that discernable postinjury, and thus soft tissue damage may have been more severe than might be inferred from the damage to the bones themselves. Such soft tissue damage includes laceration of the pleura, lungs, or intercostal vessels, which would have been largely untreatable in earlier times and thus may point to a possible cause of death. Pneumothorax (the presence of air in the pleural cavity) and hemothorax (the presence of blood in the pleural cavity) may be caused by rib fractures at any level in the thoracic cage and may be similarly life-threatening. Another serious complication of rib fracture occurs when there are at least two breaks in one rib. This produces a free-floating fragment and thus a risk of

<sup>4</sup>A biconcave vertebra should not be confused with a "butterfly vertebra," which is a congenital malformation.

internal damage, referred to as "flail" injury. Unfortunately, if the soft tissue damage caused by rib fractures is serious enough to cause death, the bony injuries observed in the archaeological skeleton would be identifiable only as perimortem fractures. Healed rib fractures in the archaeological record thus probably represent non-life-threatening trauma.

### Clavicle

Clavicular fractures are most often caused by a fall onto the shoulder but occasionally result from a fall onto an outstretched hand. The break tends to occur at the junction of the middle and lateral thirds, with downward and medial displacement of the lateral fragment being a common complication. Since clinical treatment of clavicular fractures is usually limited to the use of a sling for 1 or 2 weeks for pain relief, healed fractures often exhibit some deformity. Malaligned clavicular fractures in archaeological skeletons therefore do not necessarily point to an absence of medical treatment.

### Scapula

Scapular fractures are uncommon but are usually the result of direct trauma. Both the flat and irregular portions of the scapula may be involved. Four types are commonly described in the clinical literature: 1) fracture of the scapular body, which may be comminuted but rarely displaced because of the large muscles holding the bone in place; 2) fracture of the neck, which may lead to downward displacement of the glenoid; 3) and 4) fractures of the acromion and coracoid processes, respectively, which range from simple cracks to comminution and which may be associated with downward displacement. Although none of these injuries is usually considered serious, a possible complication of scapular fracture, especially if the injury occurs on the left side, is pneumothorax (Carrero and Wayne, 1989).

### Humerus

The most common humeral fractures in adults affect the neck, greater tuberosity, and shaft. Neck fractures are most common in older women in whom osteoporosis has weakened the bone. Indirect trauma from a

fall onto an outstretched hand is the usual cause and in more than 50% of these cases the fracture is self-stabilized through impaction. Direct trauma, in the form of a fall onto the shoulder or a blow, may cause fracture of the greater tuberosity. Shaft fractures are most common in the middle third of the bone and may be due to direct or indirect trauma. The proximal half of the shaft is a common site of fracture secondary to pathology, such as when the bone has been invaded by metastatic disease. Complications of humeral shaft fractures include displacement, nonunion, and injury to the radial nerve.

In contrast to the pattern observed in adults and described above, humeral fractures in children tend to occur at the distal end, affecting the supracondylar, epicondylar, and condylar regions. Supracondylar fractures are indirect trauma injuries caused by a fall onto an outstretched arm, with displacement occurring posteriorly. Complications include malunion, damage to the brachial artery, and tearing of the joint capsule with hemorrhage into the joint and surrounding tissues. Epicondylar fractures are usually medial and may result from direct trauma but more often from avulsion by flexor muscles in a fall. If the avulsed fragment enters the joint, which occurs frequently in children, complications in terms of reduced function and osteoarthritis usually ensue. This injury may also cause damage to the ulnar nerve. Condylar fractures are uncommon but also tend to result from a fall. In contrast to the medial involvement in epicondylar fractures, the lateral portion, or capitulum, is usually involved in condylar fractures. Displacement is not uncommon and this injury is often complicated by deformity, nonunion, and osteoarthritis.

### Ulna

Ulnar fractures are not especially common clinically, but when they occur they usually affect the olecranon or the shaft. Olecranon fractures are more common in adults and result from the direct trauma of a fall onto the point of the elbow. Severity ranges from a simple crack to comminution and the injury may be complicated by nonunion and osteoarthritis. Diaphyseal fractures can result from either direct or indi-



Fig. 13. Healed oblique fracture of the ulnar shaft. This type of fracture suggests that the mechanism of injury was indirect trauma (e.g., falling onto an outstretched hand) rather than direct trauma (e.g., parrying a blow).

rect trauma (Fig. 13). They are prone to severe displacement, malunion, nonunion, and to infection because of the bone's proximity to the surface of the skin. Fracture of the proximal shaft of the ulna is often associated with the dislocation of the radial head. This injury is referred to as a Monteggia fracture-dislocation. It is usually caused by a fall onto an outstretched hand with forced pronation, but it may also be caused by a blow to the back of the upper forearm (i.e., a "parry" fracture). Deformity commonly characterizes this injury in archaeological skeletons since the fracture cannot be properly reduced without surgery.

#### Radius

Another forearm injury, the Galeazzi fracture-dislocation of the radius, is more common clinically than is the Monteggia fracture-dislocation. It is also usually caused by a fall onto the hand, and similarly it is difficult to realign without surgical intervention. The fracture occurs near the junction of the middle and distal thirds of the radial shaft and is accompanied by dislocation of the inferior radio-ulnar joint. The most common radius fracture occurs at the distal shaft and is called the Colles' fracture. Clinically, it is the most common of all fractures in adults over the age of 40, especially females, and is nearly always caused by the indirect trauma of a fall onto the hand. The break usually occurs about 2 cm above the distal articular surface of the radius, and

the distal fragment is posteriorly displaced and usually impacted. This injury may be associated with fracture of the styloid process of the ulna. Although fractures of the distal radius, such as this, are one hundred-fold more frequent than are fractures of the proximal radius (Knowelden et al., 1964), fracture of the radial head also can result from a fall on an outstretched hand. Observed mainly in young adults, it usually appears as a crack without displacement. Comminution is possible, however, and in such cases the injury may be complicated by osteoarthritis. In contrast to these indirect trauma injuries, a simple fracture of the radial shaft, somewhat less common than the fracture-dislocation injuries, usually results from direct trauma.

Malunion is the most common complication of radius fractures, and absence of medical treatment cannot be presumed if deformity is observed since redisplacement is very common clinically within a week of fracture reduction. In archaeological specimens, at least one study has reported that radius fractures rarely healed without deformity (Grauer and Roberts, 1996).

#### Pelvis

Isolated fractures of the pelvic bones most commonly appear on the superior and/or inferior ischio-pubic ramus and the wing of the ilium. These fractures are quite benign unless displacement occurs. More serious pelvic fractures are those that disrupt the

pelvic ring through the rami or at the pubic symphysis, with associated dislocation of the sacroiliac joint. The mechanism of injury in these cases tends to be anterior-posterior crushing, lateral compression, or vertical shearing force. Complications are usually serious and would likely be life-threatening in the absence of modern medical treatment. A fracture-dislocation of the hip occurs when the head of the femur is driven through the floor of the acetabulum. This is usually the result of a heavy blow upon the lateral femur, due to a serious fall or a similar impact (e.g., vehicular trauma in clinical cases). The injury tends to comminution and serious complications. A poorly understood lesion that may result from the incomplete and temporary dislocation of the hip is the acetabular flange lesion, which appears as a flattening of the superoposterior rim of the acetabulum (Knowles, 1983). Osteoarthritis is a common sequel to any injury that involves the acetabulum.

### Femur

Clinical data indicate that fractures of the femoral neck and trochanteric region are very common in the elderly and are seriously disabling. Femoral neck fractures are often a consequence of osteoporosis and therefore appear most often among older females, although physical activity during the reproductive years (i.e., age 15 to 45) diminishes significantly the long-term risk of femoral neck fractures (Åström et al., 1987). When secondary to osteoporosis, femoral neck fractures may result from very mild trauma, such as a stumble. They usually are due to rotational force and cause lateral rotation and upward displacement of the shaft. Avascular necrosis is a serious complication of femoral neck fracture and is caused by damage to vessels in the neck that supply the femoral head. The result is that the blood supply to the head may rely overly on vessels in the ligamentum teres, which is only one of three routes of blood supply and which is usually inadequate on its own. Necrosis is usually sufficiently advanced within 2 to 6 months postinjury that the head collapses. Unless rigidly immobilized, femoral neck fractures are prone to non-union, with avascular necrosis being the

most important contributor. Osteoarthritis is another common sequel and may be due to mechanical damage at the time of injury, impairment of blood supply to the basal layer of articular cartilage, and/or to malalignment of a united fracture. An impacted abduction fracture of the femoral neck occurs less commonly, but it usually unites without surgical intervention and may be complicated only by slight shortening of the limb and possibly by arthritis.

Fractures of the trochanteric region (i.e., roughly between the greater and lesser trochanters) are common clinically but are not likely to be observed in archaeological populations because they are almost always seen in adults over 75 years of age. Decreased physical activity among older individuals is likely a contributing factor (Nilsson et al., 1991), further limiting their occurrence in past populations who followed traditional, nonmechanized, lifeways.

Femoral shaft fractures are often due to severe direct or indirect trauma. They may occur at any location on the shaft and may be of any fracture type. They are complicated by simultaneous hip dislocation; arterial damage that can compromise the viability of the limb; nerve damage, especially to the sciatic nerve; and delayed, mal-, or non-union. Four months is considered the average healing time in clinical cases of shaft fractures. Associated deformity of shaft fractures tends to be shortening or angulation, the latter having a tendency to facilitate development of osteoarthritis at the knee.

Supracondylar fractures of the femur are more or less transverse and located just above the epicondylar region. Malunion is not a common sequel in clinical cases where there has been proper medical treatment but is a possible complication in earlier times if the knee could not be kept immobilized for 2 to 3 weeks. Condylar fractures are uncommon, but when these do occur they are almost always due to direct trauma. The severity of the fracture can range from an undisplaced crack to complete separation of a condyle with marked upward displacement. In the absence of treatment, a displaced fracture is likely to heal out of alignment and osteoarthritis of the knee joint is a



probable consequence. Occasionally a transverse supracondylar fracture combines with a condylar fracture and forms a T-shaped fracture line that splits apart the two condyles.

### Patella

Fractures of the patella may be caused by direct or indirect trauma. Indirect trauma causes an avulsion fracture, usually a clean, transverse separation of the bone, due to the sudden and violent contraction of the quadriceps muscle. In contrast, direct trauma from a fall or a blow onto the patella tends to cause a crack fracture or a comminuted fracture. Undisplaced crack fractures tend to heal without complication because the fragments are held in position by the aponeurosis of the quadriceps muscle, but fractures that involve separation of the fragments and those that are comminuted will produce an irregular articular surface unless surgically repaired, and osteoarthritis is then an obvious sequel.

### Tibia and fibula

Injuries to the knee joint most commonly involve the menisci and ligaments, not bones, and therefore there may be no evidence of trauma other than soft tissue ossification after ligament strain or tear, or avulsion of the tibial spine from injury to the cruciate ligaments. When fractures do occur around lower limb joints they tend to affect the ankle, not the knee. Clinically, the bones forming the ankle are injured more often than any other bone except the distal radius. Isolated fractures of the malleolus of the tibia or fibula are especially common, and occur with or without dislocation of the talus. The usual mechanism of injury for these is either abduction and/or lateral rotation for fractures of the lateral malleolus of the fibula; and adduction for fractures of the medial malleolus of the tibia. Simultaneous fractures of both malleoli are less common. Vertical compression forces can lead to fracture of the anterior margin of the distal tibia, or, if severe, fragmentation of the distal tibial articular surface, the latter injury being prone to osteoarthritis. Fractures and dislocations at the ankle are often complicated by ligament damage, which could

be identifiable in archaeological skeletons due to soft tissue ossification.

Most diaphyseal fractures of the leg involve both the tibia and fibula. If the mechanism of injury is an angular force, it will lead to transverse or short oblique fractures of the shafts at roughly the same level. If the injury is due to a rotational force, spiral fractures will result and will occur at different levels in the two bones. Distal tibial shaft fractures, i.e., above the medial malleolus, are commonly accompanied by proximal fibular shaft fractures. Conservative treatment of tibial shaft fractures is to manually reduce the fracture and to minimize weight-bearing on the limb. Immobilization for 2 to 3 weeks is recommended in cases of stable fractures, but for up to 6 weeks if the injury is likely to be displaced; full union may take as long as 4 months. Malunion is rare in clinical cases but common archaeologically because of the greater likelihood of fractures remaining unreduced and the difficulty of immobilizing the leg. Because it is so close to the surface of the skin, the tibial shaft is the most common site of an open (compound) fracture and hence infection from contamination. Infection can also lead to nonunion. A fibular shaft fracture is not considered serious by most clinical practitioners because it unites readily and is of such little functional importance that surgical removal of a portion of the shaft is not only tolerable but is advocated when the bone acts as a strut, distracting the fragment ends of a tibial fracture and promoting nonunion. Thus, fibular shaft fractures are expected to be rare in the archaeological record but when observed they may be healed with deformity.

Fractures of the tibia at the knee joint are uncommon. Clinically, the most common is fracture of the lateral tibial condyle, caused by a lateral force against the knee such as experienced by football players or by pedestrians struck by a vehicle bumper. If the articular surface is fragmented in the injury then osteoarthritis is a predictable sequel.

### Hand, wrist, foot, and ankle

According to clinical evidence, the irregular bones most commonly fractured are the scaphoid and triquetral in the hand, and the calcaneus in the foot (Adams, 1987). Frac-

ture of the scaphoid tends to occur in young adults, usually due to indirect trauma from a fall onto an outstretched hand. The typical injury is a transverse break through the "waist" of the bone, and should not be confused with a congenitally bipartite scaphoid. Scaphoid fractures are accompanied by a high frequency of complications, including delayed union, nonunion, avascular necrosis, and osteoarthritis. Injury to the triquetral also usually results from a fall, but causes a chip fracture on the dorsal surface of the bone. Almost all calcaneal fractures are caused by a fall from a height onto the heels, such as occurs as an occupational hazard among builders and window cleaners (Wells, 1976) and a result of misadventure among parachutists, hikers, and rock climbers, for example. A fall from a tree, cliff, or roof of a dwelling is a possible cause of such injury in past populations, although it has been suggested that these injuries would be uncommon in falls of less than 4 m (Wells, 1976). The fracture may be observed as a split or crack in the subtalar tuberosity, but more often the articular surface of the calcaneus fails to withstand the stress and results in a crush injury. Fracture lines may radiate to the front and appear also on the calcaneo-cuboid joint. Associated crush fracture of lower thoracic or upper lumbar vertebrae may be noted. The usual complication of calcaneal fracture is osteoarthritis. Fractures of the talus are relatively uncommon.

Metacarpals, metatarsals, and phalanges are common sites of traumatic injury. Metacarpals are often fractured due to longitudinal compression impact such as from boxing. If the fracture line enters the joint then osteoarthritis is a likely complication. The neck and distal shaft of metacarpals also are prone to transverse or oblique fractures, often complicated by displacement. Manual phalanges tend to exhibit spiral or transverse fractures of the shaft or oblique fractures of the base. Comminution is most likely in the distal phalanges. Dislocations of phalanges are mainly due to forced hyperextension, but at least one archaeological example appears to result from forced adduction with associated tearing of the medial collateral ligament of the interphalangeal joint that made reduction impossible and led

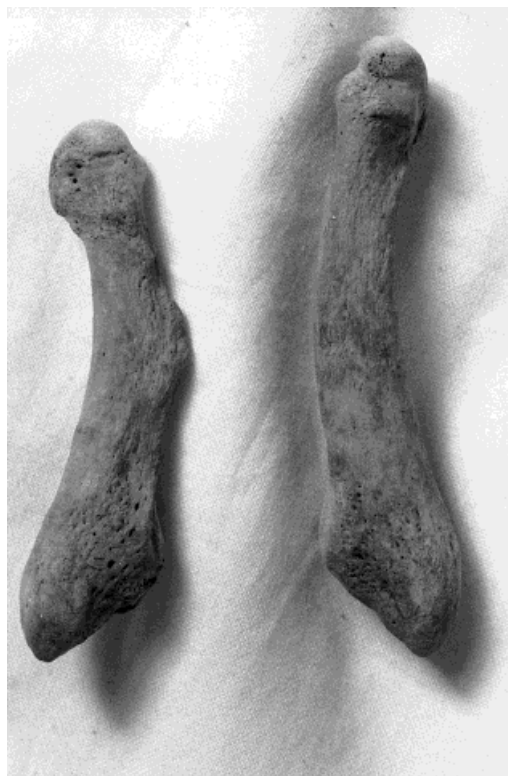

Fig. 14. Healed fracture of the left fifth metatarsal, with the unaffected contralateral element for comparison. Although the fracture line is not clear, the rotation of the head indicates a spiral fracture, probably due to a combined angular/rotational force.

to malalignment of the joint and subsequent ankylosis (Drier, 1992). Metatarsal shafts may exhibit transverse or oblique fractures (Fig. 14). The base of the fifth metatarsal is a common site of avulsion fracture caused by a twisting injury. The pedal phalanges, particularly that of the great toe, often suffer comminuted crushing injuries from direct trauma.

#### INTERPRETING THE ULTIMATE CAUSE OF INJURY

Once the injury has been described, its proximate cause determined, and any complications identified, the ultimate cause of the trauma can be evaluated. This evaluation must consider three types of information: 1) the characteristics of the fracture itself; 2) the skeletal pattern of trauma in the individual and the population; and 3) the

social, culture historical, and/or environmental context of the human remains, including the presence of artifacts. Clinical research has considered the role of many variables in trauma causation (e.g., Agarwal, 1980; Åström et al., 1987; Barber, 1973; Björnstig et al., 1991; Buhr and Cooke, 1959; Busch et al., 1986; Cogbill et al., 1991; Donaldson et al., 1990; Fife and Barancik, 1985; Fife et al., 1984; Garraway et al., 1979; Grimm, 1980; Johansson et al., 1991; Jónsson et al., 1992; Jones, 1990; Knowelden et al., 1964; Madhock et al., 1993; Nilsson et al., 1991; Prince et al., 1993; Ralis, 1986; Sahlin, 1990; Shaheen et al., 1990; Zylke, 1990) and provides valuable aids for the interpretation of fractures in antiquity, particularly with regard to skeletal patterning and the contexts of injury.

The use of the characteristics of the fracture itself to identify the mechanism of injury and point to logical causes of fracture can be illustrated by reference to a particularly problematic interpretation of trauma, that of the "parry" fracture. Although this injury has been described variously as a simple midshaft fracture (Lovejoy and Heiple, 1981), the result of a blow to an upraised arm during a fight (Janssens, 1970), or the fracture of both radius and ulna (Wells, 1964), the term is interpreted by many scholars to identify the involved bone (the ulna), indicate the location of the injury (on the shaft), and imply specific social and cultural circumstances, i.e., interpersonal conflict. A true parry fracture would indeed be caused by a direct blow to the forearm, but a proper diagnosis must rely on descriptions of the fracture location, fracture type, bones involved, apparent direction of force, and evidence of any complications. Although simple transverse fractures of the ulna are conventionally viewed as parry fractures, a consideration of fracture types and mechanisms of injury indicates that a parry fracture could be indicated by either a transverse line or a comminution; the fracture could be closed or open; and the radius could be affected in addition to the ulna. The term "parry fracture" does not appear in the clinical literature on fracture description, etiology, and treatment (e.g., Adams, 1987), and other terms commonly used in orthopedic

medicine should therefore be used to describe relevant injuries. An example is the Monteggia fracture of the ulna with associated dislocation of the proximal radius, described previously in this paper. Although this term describes the type of fracture, it does not specify a cause. In fact, this injury can be caused by a direct blow to the posterior ulnar shaft or by the indirect trauma of a forced pronation injury. A fatigue fracture might also manifest as a simple transverse break, as illustrated by the case of a midshaft ulnar fracture caused by the repeated physical stress of forking manure (Kitchin, 1948). Thus, although the prevalence of "parry fractures" is often reported in paleopathological studies it is not always clear whether all or any of the injuries actually resulted from parrying a blow.

These problems with the diagnosis of parry fractures are compounded in paleopathological interpretations of social order, particularly vis à vis gender relations (for a critique, see Mafart, 1991). Without other supporting evidence, Wood-Jones (1910) ascribed female sex to ancient Nubian skeletons that displayed forearm fractures since he thought the cause of the fractures was spousal abuse by Nubian men armed with heavy staffs. Wells referred to forearm fractures among the ancient Nubians as indicating "short tempers and aggressive conduct" that implied wife beating or a generally low status of women (Wells 1964). His accompanying fracture descriptions, however, refer only to the fact that the injury appeared in the mid- or lower shaft of the ulna, or affected the ulna and the radius. Ulnar fractures among the Cro-Magnon were similarly interpreted to indicate an aggressive nature (Zivanovic, 1982); however, the accompanying photograph and x-ray of one such injury shows a spiral fracture, with rotation in the distal aspect. Spiral fractures, in particular, are unlikely to result from a direct blow, but rather from a twisting, forced pronation injury, such as in a fall.

While features of the fracture itself may identify the mechanism of injury, the skeletal pattern of fractures in an individual may also help to clarify the probable causes of trauma. Clinically, the ulna and radius are fractured more commonly than are any

other skeletal elements, but the cause of injury varies and rarely is due to assault. A comprehensive study of long bone fractures in Medieval Britain also indicates that the radius and ulna are the bones most commonly affected, likely due to falls and other mishaps rather than violence (Grauer and Roberts, 1996). Indeed, fractures of the cranium, ribs, or hands are more likely to indicate trauma due to interpersonal violence than are fractures to the forearm. Injuries that are considered to have a high specificity for a clinical diagnosis of assault are fractures of the skull (especially the nasal and zygomatic bones and the mandible); and posterior rib fractures, vertebral spinous process fractures, and fractures of hand and foot bones, which can result from the direct trauma of punches or kicks. Occasionally the palmar surfaces of the manual phalanges will exhibit healed or unhealed cutmarks, originating as defensive wounds incurred as a victim of a knife or sword attack. Although fractures that pass along suture lines are common on subadult skulls, the exposure of diploë in intersutural perforations is a key indicator of antemortem trauma. In addition, metaphyseal lesions, transverse fractures of the scapular acromion, and sternal fractures are considered indicative of child abuse in clinical cases and may result from shaking forces rather than direct blows (Appleton, 1980; Brismar and Tuner, 1982; Fisher et al., 1990; Fonseca, 1974; Gayford, 1979; Kleinman, 1987; Shepherd et al., 1990). According to clinical practitioners, the most specific finding of physical abuse in both adults and children is multiple injuries at different stages of healing (Maples, 1986; Walker et al., 1997; Wilkinson and Van Wagenen, 1993).<sup>5</sup> Multiple but simultaneous fractures, in contrast, may represent accidental trauma, as demonstrated by the case of a Neolithic flint miner in Belgium who suffered numerous fractures and apparently died of his injuries when the roof of the mine collapsed on top of him (Knowles, 1983).

<sup>5</sup>For further descriptions and discussions of the skeletal evidence for interpersonal conflict, the reader is referred to *Troubled Times: Osteological and Archaeological Evidence of Violence*, edited by D. Martin and D. Frayer and forthcoming from Gordon and Breach publishers.

Patterns of fractures within a population may also be informative. Clinically, older, postmenopausal females have more fractures than do any other age/sex group due to the influence of osteoporosis as a predisposing factor in fracture from minor, often indirect, trauma, and this pattern is paralleled in an early 20th century skeletal collection (Mensforth and Latimer, 1989). When older females are excluded, clinical fracture rates are greatest among individuals younger than 26 years of age and tend to be determined by their activities. Age also influences the skeletal pattern of involvement. Femoral neck fractures, for example, occur commonly in older adults but rarely in children.

Features of the physical environment also have been shown to influence the frequency and nature of trauma. For example, adverse weather conditions (e.g., snow and ice) and irregular landscapes increase fracture risk from falls, while reduced winter daylight hours in northern latitudes increase fracture risk from mishaps due to limited visibility. Decreased sunlight also may impair calcium absorption and lead to fractures secondary to osteoporosis or rickets, and dietary inadequacies of vitamin C or calcium may increase the risk of pathological fractures.

The sociocultural context of injuries must also be considered. Clinical evidence overwhelmingly indicates, for example, that most fractures are due to daily activity rather than interpersonal violence or unusual events. Traditionally, most fractures in females occur in the home while most fractures in males occur at work or during sports, although this trend varies according to country, income level, occupation, and age. High fracture risks exist in occupations that have been generally restricted to men, such as agriculture, mining, forestry, and construction. In developing nations, household work such as carrying water and loads of firewood pose high fracture risks for women, as do many farming activities engaged in by both sexes. Technology-based transportation, either mechanized (e.g., automobiles) or unmechanized (e.g., bicycles and horse-drawn wagons), also carries its own fracture risk. Given circumstances such

as these, the trauma caused by activity or occupation may be indistinguishable from that due to interpersonal violence (Smith, 1996; Wakely, 1996).

Finally, historical records and an understanding of the sociocultural context of the injuries can benefit their interpretation, such as the explanation of fractures due to occupational accident during the 1856 construction of the Grand Trunk Railroad in Canada (Jimenez, 1994). Several cases of interpretation have successfully relied on such information, such as the identification of strangulation from hyoid fractures and of hanging and decapitation from vertebral injuries (Angel and Caldwell, 1984; Waldron, 1996), and the comprehensive analyses of trauma etiology in an aboriginal population of the Canadian northwest coast (Cybulski, 1992), in prehistoric populations of the American midwest (Milner, 1995), and among soldiers of the 14th century battle of Visby (Ingelmark, 1939; Knowles, 1983). Often the most compelling evidence for interpersonal violence lies in the presence of artifacts or other physical evidence of violence. Projectile points embedded in bone or recovered from the abdominal cavity are diagnostic of at least some traumatic events, and may point logically to the cause of other injuries as well (e.g., Bennike, 1985; Jurmain, 1991; Smith, 1996; Walker, 1989; and several papers in Owsley and Jantz, 1994).

### CONCLUSIONS

This review of fracture types and of the proximate and ultimate causes of injury indicates that standardized descriptive protocols can be used to improve paleopathological analysis and interpretation of trauma. These protocols should include identification of the skeletal element(s) involved; the location of the injury; its appearance; and any evidence for complications of the injury. These descriptions thus serve as a basis for inferences about the mechanism of injury, from which social, cultural, or environmental associations may then be examined. Attention to skeletal patterns, biological factors such as age and sex, and variables such as physical and sociocultural environments also improves the diagnostic accuracy of any interpretations. In particular, the traumatic

effects of violence may be difficult to distinguish from those of high-risk activities or occupations solely on the basis of skeletal evidence. Although the actual cause of trauma displayed by an archaeological skeleton may remain unknown, a quantifiable description based on specific terminology, supplemented by photographic and radiographic images of the fracture, and clearly placed in an individual, populational, socio-cultural, and physical context will enable others to evaluate a researcher's interpretation of the injury.

### ACKNOWLEDGMENTS

I thank Carolyn Prins, who selected and evaluated the clinical case studies and who conducted some of the library research; the University of Alberta Hospital, which provided the clinical fracture data; Margaret Judd, who provided helpful discussion and numerous references; Ben Lees, who supplied useful information on firearms; and Scott Haddow, who assisted with printing of photographs. I have also benefitted greatly from discussions with Robert Jurmain and Lynne Kilgore and from suggestions made by the reviewers of this paper. This research was supported by a grant from the Social Sciences and Humanities Research Council of Canada.

### LITERATURE CITED

- Adams JC (1987) *Outline of Fractures*. Edinburgh: Longman.
- Agarwal RP (1980) Pattern of bone injuries in a hill area (Pauri-Garhwal). *J. Indian Med. Assoc.* 74:65-66.
- Alexandersen V (1967) The evidence for injuries to the jaws. In DE Brothwell and AT Sandison (eds.): *Diseases in Antiquity*. Springfield: CC Thomas, pp 623-629.
- Altner PC, Grana L, and Gordon M (1975) An experimental study on the significance of muscle tissue interposition on fracture healing. *Clin. Orthop.* 111:269-273.
- Angel JL (1974) Patterns of fracture from Neolithic to modern times. *Anthropologiai Közlemények* 18:9-18.
- Angel JL, and Caldwell PC (1984) Death by strangulation: A forensic anthropological case from Wilmington, Delaware. In TA Rathbun and JE Buikstra (eds.): *Human Identification: Case Studies in Forensic Anthropology*. Springfield: CC Thomas, pp 168-175.
- Apley AG, and Solomon L (1992) *Concise System of Orthopaedics and Fractures*. Oxford: Butterworths.
- Appleton W (1980) The battered woman syndrome. *Ann. Emerg. Med.* 9:84-91.
- Åström J, Ahlqvist S, Beertema J, and Jónsson B (1987) Physical activity in women sustaining fracture of the neck of the femur. *J. Bone Jt. Surg. [Br.]* 69:381-383.
- Barber HM (1973) Horse-play: Survey of accidents with horses. *Br. Med. J.* 3:532-534.

- Bass WM (1987) *Human Osteology*. 3rd ed. Columbia: Missouri Archaeological Society.
- Bennike P (1985) *Paleopathology of Danish Skeletons*. Copenhagen: Akademisk Forlag.
- Berryman HE, and Haun SJ (1996) Applying forensic techniques to interpret cranial fracture patterns in an archaeological specimen. *Int. J. Osteoarchaeol.* 6:2-9.
- Björnstig U, Eriksson A, and Örnehult L (1991) Injuries caused by animals. *Injury* 22:295-298.
- Blair C (ed.) (1983) *Pollard's History of Firearms*. Middlesex: Country Life.
- Bramblett CA (1967) Pathology in the Darajani baboon. *Am. J. Phys. Anthropol.* 26:331-340.
- Brismar B, and Tuner K (1982) Battered women: A surgical problem. *Acta Chir. Scand.* 148:103-105.
- Buhr AJ, and Cooke AM (1959) Fracture patterns. *Lancet* 1:531-536.
- Buikstra JE, and Ubelaker DH (eds.) (1994) *Standards for Data Collection From Human Skeletal Remains*. Fayetteville: Arkansas Archaeological Survey, Research Series No. 44.
- Bullough PG, and Boachie-Adjei O (1988) *Atlas of Spinal Diseases*. Philadelphia: JB Lippincott.
- Burrell LL, Mass MC, and Van Gerven DP (1986) Patterns of long-bone fracture in two Nubian cemeteries. *Hum. Evol.* 1:495-506.
- Burrows JH (1956) Fatigue infraction of the middle of the tibia in ballet dancers. *J. Bone Jt. Surg. [Br.]* 38:83-94.
- Busch HM, Cogbill TH, Landercasper J, and Landercasper BO (1986) Blunt bovine and equine trauma. *J. Trauma* 26:559-560.
- Butler DF (1971) *U.S. Firearms: 1776-1875*. New York: Winchester.
- Carrero R, and Wayne M (1989) Chest trauma. *Emerg. Med. Clin. North Am.* 7:389-418.
- Cogbill TH, Steenlage ES, Landercasper J, and Strutt PJ (1991) Death and disability from agricultural injuries in Wisconsin: A 12-year experience with 739 patients. *J. Trauma* 31:1632-1637.
- Cohen HR, Becker MH, and Genieser NB (1974) Fatigue fracture in Hare Krishna converts. *N. Y. State J. Med.* 74:1998-1999.
- Cybulski JS (1992) A Greenville Burial Ground. *Archaeological Survey of Canada Mercury Series No. 146*. Hull: Canadian Museum of Civilization.
- Dastugue J, and Gervais V (1992) *Paleopathologie du Squelette Humain*. Paris: Société Nouvelle des Editions Boubée.
- Donaldson LJ, Cook A, and Thomson RG (1990) Incidence of fractures in a geographically defined population. *J. Epidemiol. Community Health* 44:241-245.
- Dreier FG (1992) The palaeopathology of a finger dislocation. *Int. J. Osteoarchaeol.* 2:31-35.
- Fife D, and Barancik JI (1985) Northeastern Ohio trauma study III: Incidence of fractures. *Ann. Emerg. Med.* 3:244-248.
- Fife D, Barancik JI, and Chatterjee BF (1984) Northeastern Ohio trauma study II: Injury rates by age, sex, and cause. *Am. J. Public Health* 74:473-478.
- Filer J (1992) Head injuries in Egypt and Nubia: A comparison of skulls from Giza and Kerma. *J. Egypt. Archaeol.* 78:281-285.
- Fisher EB, Kraus H, and Lewis VL (1990) Assaulted women: Maxillofacial injuries in rape and domestic violence. *Plast. Reconstr. Surg.* 86:161-162.
- Fonseka S (1974) A study of wife-beating in the Camberwell area. *Br. J. Clin. Prac.* 28:400-402.
- Garraway WM, Stauffer RN, Kurland LT, and O'Fallon WM (1979) Limb fractures in a defined population I: Frequency and distribution. *Mayo Clinic Proc.* 54:701-707.
- Gayford JJ (1979) Battered wives. *Br. J. Hosp. Med.* 22:496-503.
- Gill GW (1994) Skeletal injuries of pioneers. In DW Owsley and RL Jantz (eds.): *Skeletal Biology in the Great Plains*. Washington, DC: Smithsonian Institution Press, pp 159-172.
- Grauer AL, and Roberts CA (1996) Paleoepidemiology, healing, and possible treatment of trauma in the Medieval cemetery population of St. Helen-on-the-Walls, York, England. *Am. J. Phys. Anthropol.* 100:531-544.
- Grimm H (1980) Sex differences in the frequency of bone fracture in historic and prehistoric times. In I Schwedezkef, B Chiarelli, and O Necrason (eds.): *Physical Anthropology of European Populations*. The Hague: Mouton, pp 347-349.
- Gurdjian ES (1975) *Impact Head Injury*. Springfield: CC Thomas.
- Gurdjian ES, Webster JE, and Lissner HR (1950) The mechanism of skull fracture. *Radiology* 54:314-339.
- Gustilo RB (1991) *The Fracture Classification Manual*. St. Louis: Mosby.
- Hamperl H (1967) The osteological consequences of scalping. In DR Brothwell and AT Sandison (eds.): *Diseases in Antiquity*. Springfield: CC Thomas, pp 630-634.
- Harkess JW, and Ramsey WC (1991) Principles of fractures and dislocations. In CA Rockwood, DP Green, and RW Bucholz (eds.): *Fractures in Adults*. 3rd ed. Philadelphia: JB Lippincott, pp 1-180.
- Harvey FH, and Jones AM (1980) "Typical" basal skull fracture of both petrous bones: An unreliable indicator of head impact site. *J. Forensic Sci.* 25:280-286.
- Heppenstall RB (1980) Delayed union, nonunion, and pseudoarthrosis. In RB Heppenstall (ed.): *Fracture Treatment and Healing*. Philadelphia: WB Saunders, pp 80-96.
- Hooper R (1969) *Patterns of Acute Head Injury*. London: Edward Arnold.
- Ingelmark BE (1939) *The Skeletons*. In B Thordeman (ed.): *Arms and Armour from the Battle of Wisby, 1361*. Stockholm: Vitterhets Historie Och Antikvitets Akademien, pp 149-209.
- Janssens PA (1970) *Paleopathology*. London: Curwen.
- Jimenez SB (1994) Occupational hazards in 19th-century Upper Canada. In A Herring and L Chan (eds.): *Strength in Diversity*. Toronto: Canadian Scholars, pp 345-364.
- Johansson C, Mellström D, Milsom I, Rundgren Å, and Ekelund P (1991) Prevalence of fractures among 10,000 women from the 1900 to 1940 birth cohorts resident in Gothenberg. *Maturitas* 14:65-74.
- Jones MW (1990) A study of trauma in an Amish community. *J. Trauma* 30:899-902.
- Jönsson B, Gärdsell P, Johnell O, Redlund-Johnell I, and Sernbo I (1992) Differences in fracture pattern between an urban and rural population: A comparative population-based study in southern Sweden. *Osteoporosis Int.* 2:269-273.
- Jurmain RD (1989) Trauma, degenerative disease, and other pathologies among the Gombe chimpanzees. *Am. J. Phys. Anthropol.* 80:229-237.
- Jurmain RD (1991) Paleoepidemiology of trauma in a prehistoric central California population. In DJ Ortner and AC Aufderheide (eds.): *Human Paleopathology: Current syntheses and future options*. Washington, DC: Smithsonian Institution Press, pp 241-248.
- Karlstrom G, and Olerud S (1974) Fractures of the tibial shaft: A critical evaluation of treatment alternatives. *Clin. Orthop.* 105:82-115.
- Kaufman MH, Whitaker D, and McTavish J (1997) Differential diagnosis of holes in the calvarium: Appli-

- cation of modern clinical data to palaeopathology. *J. Archaeol. Sci.* 24:193-218.
- Kelley JO, and Angel JL (1987) Life stresses of slavery. *Am. J. Phys. Anthropol.* 74:199-211.
- Kitchin ID (1948) Fatigue fractures of the ulna. *J. Bone Jt. Surg. [Br.]* 30:622-623.
- Kleinman PK (ed.) (1987) *Diagnostic Imaging of Child Abuse*. Baltimore: Williams and Wilkins.
- Knowlden J, Buhr AJ, and Dunbar O (1964) Incidence of fractures in persons over 35 years of age. *Br. J. Prev. Soc. Med.* 18:130-141.
- Knowles AK (1983) Acute traumatic lesions. In GD Hart (ed.): *Disease in Ancient Man*. Toronto: Clarke Irwin, pp 61-83.
- Larsen CS, Huyn HP, and McEwan BG (1996) Death by gunshot: biocultural implications of trauma at Mission San Luis. *Int. J. Osteoarchaeol.* 6:42-50.
- Liston MA, and Baker BJ (1996) Reconstructing the massacre at Fort William Henry, New York. *Int. J. Osteoarchaeol.* 6:28-41.
- Lovejoy CO, and Heiple KG (1981) The analysis of fractures in skeletal populations with an example from the Libben Site, Ottawa County Ohio. *Am. J. Phys. Anthropol.* 55:529-541.
- Lovell NC (1990) Skeletal and dental pathology of free-ranging mountain gorillas. *Am. J. Phys. Anthropol.* 81:399-412.
- Madhock R, Melton LJ III, Atkinson EJ, O'Fallon WM, and Lewallen DG (1993) Urban vs. rural increase in hip fracture incidence. *Acta Orthop. Scand.* 58:38-42.
- Mafart B-Y (1991) Apport de l'étude des fractures osseuses pour la connaissance des populations anciennes. Actes des 5<sup>e</sup> Journées Anthropologiques, Dossier de Documentation Archéologique no. 14. Paris: Editions du CNRS.
- Mann RW, and Murphy SP (1990) *Regional Atlas of Bone Disease*. Springfield: CC Thomas.
- Maples WR (1986) Trauma analysis by the forensic anthropologist. In KJ Reichs (ed.): *Forensic Osteology*. Springfield: CC Thomas, pp 218-228.
- Mensforth RP, and Latimer BM (1989) Hamann-Todd collection aging studies: Osteoporosis fracture syndrome. *Am. J. Phys. Anthropol.* 80:461-479.
- Merbs CF (1989a) Trauma. In MY Iscan and KAR Kennedy (eds): *Reconstruction of Life From the Skeleton*. New York: Alan R. Liss, pp 161-189.
- Merbs CF (1989b) Spondylolysis: Its nature and anthropological significance. *Int. J. Anthropol.* 4:163-169.
- Merbs CF (1995) Incomplete spondylolysis and healing: A study of ancient Canadian Eskimo skeletons. *Spine* 20:2328-2334.
- Merbs CF (1996) Spondylolysis and Spondylolisthesis: A cost of being an erect biped or a clever adaptation? *Yrbk. Phys. Anthropol.* 39:201-228.
- Miller M, and Miller JH (1979) *Orthopaedics and Accidents*. London: The English Universities Press.
- Milner GR (1995) An osteological perspective on prehistoric warfare. In LA Beck (ed.): *Regional Approaches to Mortuary Analysis*. New York: Plenum, pp 221-244.
- Nilsson R, Löfman O, Berglund K, Larsson L, and Toss G (1991) Increased hip-fracture incidence in the county of Östergötland, Sweden, 1940-1986, with forecasts up to the year 2000: An epidemiological study. *Int. J. Epidemiol.* 20:1018-1024.
- Ortner DJ, and Putschar WGJ (1981) *Identification of Pathological Conditions in Human Skeletal Remains*. Smithsonian Contributions to Anthropology No. 28. Washington, DC: Smithsonian Institution Press.
- Owsley DW, and Jantz RL (eds.) (1994) *Skeletal Biology in the Great Plains: Migration, Warfare, Health, and Subsistence*. Washington, DC: Smithsonian Institution Press.
- Owsley DW, Mann RW, and Murphy SP (1991) Injuries, surgical care, and disease. In S Pfeiffer and RF Williamson (eds.): *Snake Hill: An Investigation of a Military Cemetery from the War of 1812*. Toronto: Dundurn, pp 198-226.
- Paton D (1984) *Notes on Fractures*. London: Churchill Livingstone.
- Perkins G (1958) *Fractures and Dislocations*. London: Athlone Press of the University of London.
- Polson C, Gee DJ, and Knight B (1985) *Essentials of Forensic Medicine*. 4th ed. Toronto: Pergamon.
- Prince RL, Knuiman MW, and Gulland L (1993) Fracture prevalence in an Australian population. *Aust. J. Public Health* 17:124-128.
- Ralis ZA (1986) Epidemics of fractures during periods of snow and ice. *Br. Med. J.* 293:484.
- Roberts C (1991) Trauma and treatment in the British Isles in the Historic Period: A design for multidisciplinary research. In DJ Ortner and AC Aufderheide (eds.): *Human Paleopathology: Current Syntheses and Future Options*. Washington, DC: Smithsonian Institution Press, pp 225-240.
- Roberts C, and Manchester K (1995) *The Archaeology of Disease*. Ithaca: Cornell University Press.
- Sahlin Y (1990) Occurrence of fractures in a defined population: A 1-year study. *Injury* 21:158-160.
- Schultz AH (1937) Proportions, variability and asymmetries of the long bones of the limbs and the clavicles in man and apes. *Hum. Biol.* 9:281-328.
- Schultz AH (1939) Notes on diseases and healed fractures of wild apes. *Bull. Hist. Med.* 7:571-582.
- Schultz RJ (1990) *The Language of Fractures*. 2nd ed. Baltimore: Williams and Wilkins.
- Sevitt S (1981) *Bone Repair and Fracture Healing in Man*. Edinburgh: Longman.
- Shaheen MAE, Bard AA, Al-Khudairy N, Khan FA, Mosalem A, and Sabet N (1990) Patterns of accidental fractures and dislocations in Saudi Arabia. *Injury* 21:347-350.
- Shepherd JP, Shapland M, Pearce NX, and Scully C (1990) Pattern, severity, and aetiology of injuries in victims of assault. *J. R. Soc. Med.* 83:161-162.
- Shermis S (1984) Domestic violence in two skeletal populations. *Ossa* 9-11:143-151.
- Smith MO (1996) 'Parry' fractures and female-directed interpersonal violence: Implications from the late Archaic Period of west Tennessee. *Int. J. Osteoarchaeol.* 6:84-91.
- Stedman TL (1982) *Stedman's Medical Dictionary*, 24th Edn. Baltimore: Williams and Wilkins.
- Steinbock RT (1976) *Paleopathological Diagnosis and Interpretation*. Springfield: CC Thomas.
- Stewart TD (1974) Nonunion of fractures in antiquity, with descriptions of five cases from the New World involving the forearm. *Bull. N. Y. Acad. Sci.* 50:876-891.
- Swan KG, and Swan RC (1989) *Gunshot Wounds: Pathophysiology and Management*. Chicago: Year Book Medical Publishers.
- Ubelaker DH, and Adams BJ (1995) Differentiation of perimortem and postmortem trauma using taphonomic indicators. *J. Forensic Sci.* 40:509-512.
- Unger JM, Gentry LR, and Grossman JE (1990) Sphenoid fractures: Prevalence, sites, and significance. *Radiology* 175:175-180.
- Urist MR, Mazet R, and McLean FC (1954) The pathogenesis and treatment of delayed union and nonunion. *J. Bone Jt. Surg.* 36:931-967.
- Wakely J (1996) Limits to interpretation of skeletal trauma: Two case studies from Medieval Abingdon, England. *Int. J. Osteoarchaeol.* 6:76-83.
- Waldron T (1996) Legalized trauma. *Int. J. Osteoarchaeol.* 6:114-118.

- Walker PL (1989) Cranial injuries as evidence of violence in prehistoric southern California. *Am. J. Phys. Anthropol.* 80:313-323.
- Walker PL, Cook DC, and Lambert PM (1997) Skeletal evidence for child abuse: A physical anthropological perspective. *J. Forensic Sci.* 42:196-207.
- Wells C (1964) *Bones, Bodies and Disease*. London: Thames and Hudson.
- Wells C (1976) Fractures of the heel bones in early and prehistoric times. *Practitioner* 217:214-298.
- Wilkinson RG, and Van Wagenen KM (1993) Violence against women: Prehistoric skeletal evidence from Michigan. *Midcont. J. Archaeol.* 18:190-216.
- Wilson ES, and Katz FN (1969) Stress fracture analysis of 250 consecutive cases. *Radiology* 92:481-486.
- Wood-Jones F (1910) Fractured bones and dislocations. In GE Smith and F Wood-Jones (eds.): *The Archaeological Survey of Nubia Report for 1907-1908. Vol II: Report on the Human Remains*. Cairo: National Printing Dept., pp 293-342.
- Yamigashi M, and Yoshimura Y (1955) The biomechanics of fracture healing. *J. Bone Jt. Surg. [Br.]* 37:1035-1068.
- Zivanovic S (1982) *Ancient Diseases: The Elements of Paleopathology*. New York: Pica.
- Zylke JW (1990) As nation grows older, falls become greater source of fear, injury, death. *JAMA* 263:2021.