

Chapter 4

The changing tides in oesophageal surgery

Walford Gillison FRCS Ed FRCS

Emeritus Consultant Surgeon, Kidderminster General Hospital, Kidderminster, UK and
Honorary Consultant Surgeon, City Hospital, Birmingham, UK

James B Elder MD FRCS Ed Eng & Glasgow

Emeritus Professor and Consultant Surgeon, North Staffordshire Hospitals, Stoke-on-Trent,
University of Keele, Staffordshire, UK

Introduction

“The oesophagus is a difficult surgical field for its inaccessibility, its lack of serous coat, and its enclosure in structures where infection is especially dangerous and rapid.” (Ivor Lewis) ¹.

Most of the oesophagus is situated behind the heart, between the lungs, in a fairly rigid bony cage. Instrumentation and surgical procedures on the oesophagus are relatively recent events compared with other parts of the body. Many patients are frail. Such frailty and absence of modern peri-operative support was the cause of so little progress taking place until half way through the 20th century.

With the benefit of hindsight the evolution of oesophageal surgery is made easier by looking at four important milestones or time-zones.

Milestones in oesophageal surgery

First milestone: before general anaesthesia in 1846

Earliest endeavours before ‘Ether Day’ in 1846 were mainly on the cervical oesophagus. The situations were desperate: one can imagine the fear,

the pain and the fortitude required of the patients at that time, despite the help of liberal doses of laudanum and alcohol. Frequently the patient was held down, possibly strapped to a hard operating table, with the single-minded surgeons of the day gritting their teeth to achieve the goal as quickly as possible. It is no wonder the operating theatres were placed as far from the wards as practicable. As Nuland ² wrote: “It took a particular kind of man to do this work..... he is not the kind of man or woman who would be a surgeon of this century.”

Surgery in that time was limited to instrumental pushing or pulling foreign bodies, dilating both benign and malignant strictures, or opening the oesophagus through the neck.

Second milestone: 1846 to the advent of thoracotomy until 1913

Before thoracotomy, access to the oesophagus from above or below the mediastinum was limited. Theodor Billroth, the father of gastrointestinal surgery, at one stage said: “Surgery should halt at the pleura!”

Ingenious reconstructions were tried, using rubber tubes, skin tubes, skin grafts, or later, lengths of large or small intestine illustrated later.

Johann von Mikulicz-Radecki (Figure 1), referred to as von Mikulicz, was determined to solve the problem of fatal pneumothorax when the chest cavity was opened, deliberately or otherwise.



Figure 1. Johann von Mikulicz-Radecki (1850-1905). Reproduced with permission from the *Académie de Médecine, Paris, France*.

He appointed his pupil Ferdinand Sauerbruch to research in the laboratory a means of avoiding it. Sauerbruch realised that if the relatively negative pressure in the pleural cavity could be reproduced outside the chest, surgical intervention should be possible. After several trials and tribulations, he succeeded during a public demonstration in 1904³.

The chambers were difficult to seal against leakage, the costs were high and the working environment uncomfortable. Fortunately, following the pioneer work of Brauer and Petersen⁴ and others, positive pressure endotracheal ventilation provided an alternative and safer method of providing anaesthesia. Sauerbruch was not amused and advised against positive pressure endotracheal anaesthesia! It took a very short time before he lost that argument.

The third milestone: advent of thoracotomy

In 1913, Torek⁵ performed the first successful transthoracic resection with the intention of restoring swallowing outside the chest at a later date. Others attempted to emulate him with varying success.

Later, Rowbotham and Magill's⁶ endotracheal tube devised in 1921 permitted access to the chest interior. Surgeons were gradually entering the chest cavity, opening or repairing the oesophagus, but after resection the majority restored continuity outside the rib cage.

The fourth milestone: after 1938

In 1938, Marshall's successful transthoracic resection⁷ combined with immediate anastomosis, changed oesophageal surgery forever. When muscle relaxants, blood transfusion and antibiotics arrived in the 1940s, the oesophagus could more safely be resected and restored in this manner. The Copenhagen polio epidemic⁸ in 1952 stimulated development of long-term ventilation which further involved anaesthetists, as well as intensive and critical care units. Endotracheal tubes permitted 'one-lung anaesthesia' allowing one lung to collapse on the operated side while the other lung continued to absorb the anaesthetic gases. Plastic cannulas transformed intravenous therapy, and the explosion of laparoscopic and endoscopic surgery in the last 25 years has made a huge surgical impact.

Common oesophageal disorders

Foreign body impaction

Conservative treatment

In 1889 the *Journal of Medical Progress* quoted the "Potato Cure" by a Dr. Cameron at a meeting of the Imperial Society of Physicians in Vienna. He cited several patients with impacted foreign bodies, who were fed by mashed potato, in order to propel the bolus into the stomach.

Hochenegg and Billroth at the same meeting agreed. This might be questioned, as this method would only work in mild obstructions, and in the event of failure would only complicate the solution.

Blind extraction

Johannes Arculanus in 1493⁹, designed a flexible multi-perforated leaden tube for extraction of impacted foreign bodies which might be caught in its perforations. About the same time, Ambroise Paré devised leather tubes, osiers (willow wands) and swans' quills to dispel boluses. After these, flexible lead or silver probes and whalebone probes were used. They were understandably called 'sounds' especially if the foreign body was metallic.

About a century later, Guilemus Fabricius Hildanus designed a perforated silver tube, about 75cm in length with a small sponge at its tip, for retrieving or pushing objects through to the stomach. Hieronymus Fabricius from Aquapendente (Wilhelm Fabry) confirmed that if an impacted object in the oesophagus could not be extracted up through the mouth, it was reasonable to push it distally into the stomach. Furthermore, he once covered a similar tube with sheep intestine to reduce friction to be retained *in situ* for feeding purposes. He also used thin waxed tapers, hence 'bougies' (French for waxed candle) to push obstructing objects into the stomach.

Open operation

According to Meade¹⁰, Habicot in 1620 saved a young boy from death by asphyxiation, who had swallowed a bag of coins which impacted in the upper oesophagus. He first performed an emergency tracheotomy; later, an assistant passed a sound by mouth to the obstruction. Habicot squeezed the bag of coins safely into the stomach without opening the oesophagus. Over a century later, Guttani, according to Goursault from Limoges, removed an impacted bone from the cervical oesophagus in 1738. He wisely laid the wound open to allow delayed healing. Therefore, in the 16th and 17th centuries, some surgeons were conscious of the risks of infection, and that fistulas would close in the absence of distal obstruction.

Cheever¹¹, in 1867, was the first American to perform a successful oesophagotomy for impacted foreign body. He noted seven oesophagotomies had been reported in France, five in England, and one each in Belgium, Italy and India. Cheever's foreign body was an impacted fish-bone in the oesophagus which had stuck below the cricoid cartilage for three days despite repeated attempts to remove it endoscopically.

It was hoped a posterolateral extrapleural route for surgical access to the thoracic oesophagus would reduce the risk of empyema. In 1924, Enderlen¹² of Heidelberg did succeed in such an attempt; however, most contemporaries thought it too dangerous.

Visual extraction

Successful treatment was related to the advances in endoscopy and instruments of retrieval. The reader is recommended to an excellent detailed review by Edmondson¹³ for the broader picture. Endoscopic removal replaced most operative measures because general and topical anaesthesia gradually became safer and more comfortable.

Upper gastrointestinal endoscopy is conveniently divided into three eras: the rigid, semi-flexible and fiberoptic eras.

The rigid endoscope era (1805-1932)

Adolf Kussmaul, father-in-law to Vincenz Czerny, was driven by the discovery that emptying of the stomach in pyloric stenosis produced excellent but temporary relief. He realised that seeing the interior of the oesophagus and stomach was crucial. He extended the advances by Bozzini's lichteiter and Desormeux' cystoscopes, which were mainly of benefit for seeing the pharynx, vagina or bladder, to looking further. In 1868¹³, he got a glimpse of the oesophagus but was hindered by poor light and no suction. He once saw a tumour of the oesophagus at the level of the tracheal bifurcation with an instrument similar to that shown in Figure 2.

He established, thanks to a co-operative sword swallower, the important principle that both the oesophagus and part of the stomach could be examined with a straight instrument.

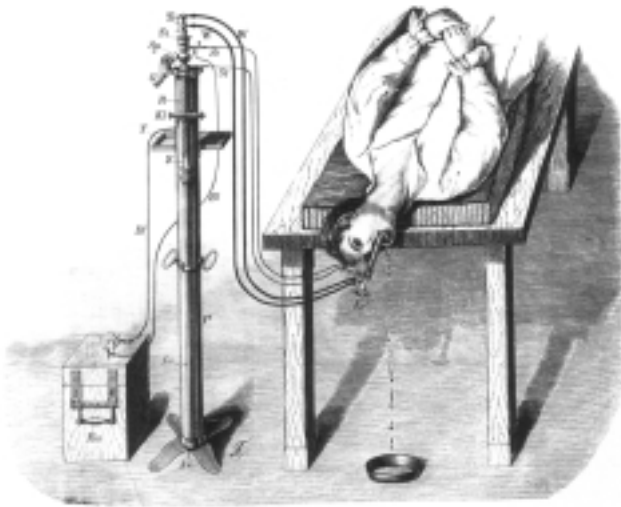


Figure 2. First oesophagoscopy examination. *Reproduced from Phillip Bozzini and Endoscopy in the 19th century. By H.J. and M.A. Reuter, with collaboration by D. Loenicker. Max Nitze Museum, Stuttgart, 1988.*

Progress continued when Leiter, a technician, collaborated with Mikulicz using electric light sources and straight tubular endoscopes.

Von Hacker¹⁴ first successfully removed a foreign body through an oesophagoscope in 1898. As oesophagoscopes were being developed globally, increasing patient comfort and safety, adequate light, adequate suction and clear views made oesophagotomy less necessary.

Doyens such as Chevalier Jackson (Figure 3) perfected examination and retrieval of foreign objects, performing biopsies and occasionally, he saw part of the stomach using straight instruments. An accolade to Jackson was made by Edmondson¹³ who said no contemporary was able to see as much, nor perform endoscopy so safely. Rigid oesophagoscopes are occasionally required to retrieve foreign bodies today.

The semi-flexible (Schindler) era (1932-1957)

Schindler, an expert with rigid equipment, devised with Wolf an endoscope which was able to visualise most of the stomach as well as the oesophagus after several attempts (Figure 4). Such instruments were



Figure 3. Chevalier Jackson (1865-1958). *Reproduced with permission from the Wellcome Library, London.*



Figure 4. Schindler semi-flexible endoscope (Down Bros. London). *Reproduced with permission from B. Braun Medical Ltd.*

easier to introduce, safer to use and could have camera attachment. After setting up teaching centres around Munich in Germany, he was seized during a Nazi purge in Munich because he was Jewish, but thanks to his non-Jewish wife and his American colleagues, he was released to perform a lecture tour on endoscopy in America, and wisely decided to remain.

The fiberoptic era (since 1957)

Basil Hirschowitz utilised advances in the physics of light-bending glass fibres until he could examine his own gastric interior. Now the proximal duodenum and the whole stomach could be seen, and side-viewing equipment allowed the duodenum and biliary tree to be inspected and cannulated. Fiberoptic colonoscopy followed soon after.

Perforation and rupture

Instrumental damage is still the commonest cause of oesophageal rupture today. Management and survival depend on the speed of diagnosis and the extent of the damage. Spontaneous rupture is more rare an event.

No surgical intervention was possible when the famous Dutch physician Hermann Boerhaave (Figure 5) attended the gourmand, the Grand Admiral of Holland, Baron de Wassenaer in 1723.

A fine account has been given by Liebermann-Meffert and colleagues¹⁵: "Three days earlier the patient had taken part in what he called a light meal from the following menu:

Veal Soup with herbs.
Boiled lamb with cabbage.
Fried sweetbread (pancreas) and spinach.
Duck.
Two larks.
Compôte of apples.
Dessert.
Pears, Grapes, Sweetmeats.
Beer and Moselle.

He went out riding after this repast, but at 10.30pm he suffered intense pains in the stomach. Despite several doses of his favourite emetic, vomiting

produced no relief. Desperately he tickled his throat with a feather which caused even greater pain which spread round his left chest.

After careful examination of both patient and his urine, Boerhaave believed the patient was dehydrated despite the huge fluid intake; so poultices, blood letting, oral sweet almond oil and enemata were tried with no relief before the patient died.

Autopsy showed surgical emphysema all over his torso, his intestines were full of air, despite an empty stomach and the left chest full of fluid smelling of roast duck. Both the patient's emetic solution and Boerhaave's almond oil were floating on the surface. Above the hiatus was a ragged tear in the left wall of the pleura communicating with a cavity between two completely disrupted ends of the previously healthy oesophagus."

Norman Barrett¹⁶ performed the first successful operative repair in 1947. Menguy in 1971 repaired a huge tear in the thoracic oesophagus and protected his suture line with a loop cervical oesophagostomy




Figure 5. Hermann Boerhaave (1668-1738). Reproduced with permission from the Académie de Médecine, Paris, France.

above and fed the patient by gastrostomy until the oesophagus was proved to have healed later ¹⁷.

Wise surgeons soon learned to look for other injuries: blunt injuries to the thoracic oesophagus were often too ragged to suture, so T-tubes used by Abbott and colleagues ¹⁸, with temporising cervical oesophagostomies were used, or restoration using the stomach or colon later. For distal obstruction or tumour, the case for immediate oesophagectomy was justified by Seybold, Johnson and Leary ¹⁹ in 1950, and Blalock ²⁰ in 1957.

Damage by noxious acids and caustics

Postlethwait found in nearly 4000 poison ingestions that only 5.7% developed permanent stenoses. Most accidental strictures occur in children. About 60% in his study were due to lye (sodium hydroxide) ingestion ²¹. Some medications, such as potassium chloride, caused localised stricture especially in motility disorders. Ingestion of caustics left in wine bottles by retreating troops in battle proved devastating weapons.

Acute stages

The knowledge of the site and extent of the stricture was crucial in order to save some of these desperate cases. Prompt skilled endoscopy was often paramount; likewise, care for respiratory complications, relief of pain, and rehydration were critical. If surgical intervention was not indicated, Constanzo and colleagues ²² splinted the lumen with a nasogastric tube to feed the patient and prevent complete fibrosis.

The treatment options with acute necrosis were:

- ◆ transhiatal oesophagectomy ²³ (vide infra) if the stomach were spared;
- ◆ diversion by cervical oesophagostomy, with washing and drainage of the contaminated mediastinum and peritoneum;
- ◆ replacement with pedicled colon if stomach was unavailable. Yudin ²⁴ published a most remarkable series reported in 1944 of 88 resections followed by colonic substitution with only two deaths;
- ◆ pedicled or free jejunal graft ²⁵, if localised to the neck or lowermost oesophagus, described in the cancer section below.

Late stages

The clinician had to look out for, anticipate and treat if necessary:

- ◆ reflux oesophagitis from shortening of the longitudinal muscle pulling the cardia through the hiatus;
- ◆ hard, resistant, fibrotic strictures. Tucker ²⁶, in 1924, employed string dilatations threaded from mouth to preliminary gastrostomy, until most fibrotic narrowing ceased. Tucker realised that retrograde dilatation by the gastrostomy was often safer in tough late strictures;
- ◆ occasionally strictures resistant to dilatations had to be resected, as described later in this chapter;
- ◆ malignant (usually squamous) change occurring approximately 24 years later. Kiviranta ²⁷ found increased frequency of dilatations an ominous sign.

Chevalier Jackson, who had a huge reputation for dilating oesophageal strictures, fought for 20 years to get caustics clearly labelled and out of reach of children ²⁸. It eventually became law by statute in the US in 1927.

Damage by reflux of noxious digestive juices (gastro-oesophageal reflux)

Hiatal hernia and gastro-oesophageal reflux

Diaphragmatic hernias

Ambroise Paré ²⁹ in the 16th century, described autopsy findings of two patients with traumatic diaphragmatic hernia in his book *Oeuvres complètes*. Bright ³⁰ from Guy's Hospital in London reported the phenomenon in 1836. Bowditch ³¹, 17 years later, suggested that it should be corrected or repaired. In 1912, Scudder ³² from Boston reported on 53 surgical attempts at reduction and repair of all types of hiatal hernia. He recorded a survival of seven in 11 thoracic repairs, but only seven survived out of 42 abdominal

repairs! There was no mention of associated abdominal disease.

Sliding hiatal hernias

Everything changed when Allison³³ drew attention in 1951 to reflux symptoms being different from other abdominal conditions. Without the aid of manometry, Allison believed simple anatomical repair alone was sufficient to cure reflux; he deserves credit for admitting it was insufficient later. Before laparoscopic surgery, surgeons had heated arguments for and against abdominal or thoracic access. The advantages of the abdominal approach included:

- ◆ treatment of coexisting peptic ulcer or gallbladder disease;
- ◆ alleged fewer disturbances of the left lung;
- ◆ a potentially painless scar.

Advantages of the thoracic approach included:

- ◆ direct access to a badly inflamed lower oesophagus;
- ◆ better access in obese patients;
- ◆ incarcerated herniated stomach reduction.

The principles, whatever the route, included restoration of original anatomy, a thorough cleaning of the hiatal area, with preservation of the vagus nerves and spleen.

Some of the commoner anti-reflux operations are described below.

Classical Nissen fundoplication

Rudolf Nissen (Figure 20) discovered an anti-reflux procedure by chance, following a resection of the cardia for oesophageal ulcer in 1936, which he described in 1937³⁴. He fashioned the oesophagus into the fundus of the stomach, similar to the valve of a Witzel gastrostomy (Figure 3, Chapter 6). To his delight, he found this patient had no reflux symptoms after 16 years. Other patients without this valve developed oesophagitis.

Initially, he added a gastropexy, but discarded it later. However, after the 1937 experience, he

recreated a new valve by wrapping a tongue of intact stomach near the cardia, which he called a 'fundoplication'. The stages are shown in Figure 6.

The principles of Nissen's anti-reflux operation were:

- ◆ sub-costal incision, though most surgeons used an upper midline incision;
- ◆ division of the short gastric vessels, but his assistant Rossetti tried to avoid it. The spleen was preserved if possible;
- ◆ thorough clearance behind the restored abdominal oesophagus;
- ◆ three or four non-absorbable sutures inserted transversely from the fundus on the left to the plicated fundus on the right of the oesophagus. These included the anterior wall of the lower oesophagus to prevent the oesophagus retracting upward from the plication. His unit later reduced the number of sutures to one or two;
- ◆ Nissen seldom repaired the hiatus as he believed that the bulk of the plication was too large to enter the chest. He declared that should this postoperative event take place, the 'wrap' would still act as a reflux barrier even in the chest.

However, Mansour and colleagues³⁵ found some prolapsed plications through the hiatus developed gastric ulceration above the diaphragm. Many agreed with Polk and Zeppa³⁶ in 1969 who routinely repaired the diaphragm.

There is no doubt that the Nissen fundoplication or 'wrap' has been a very successful anti-reflux barrier. It has been too successful in some patients, causing occasional dysphagia and 'gas-bloat'. The latter could cause inability to belch or vomit, and socially embarrassing flatulence. It is because the principle of Nissen's fundoplication is applicable to laparoscopic surgery that many surgeons have modified the 'wrap' to reduce the chances of gas bloat. These modifications include that of Donahue³⁷ who devised a 'floppy' 360° fundoplication, and DeMeester's³⁸ shortened version. The Lind³⁹ and Toupet⁴⁰ partial fundoplications are very similar. Watson's⁴¹ fundoplication of only 120° was even less of a wrap.

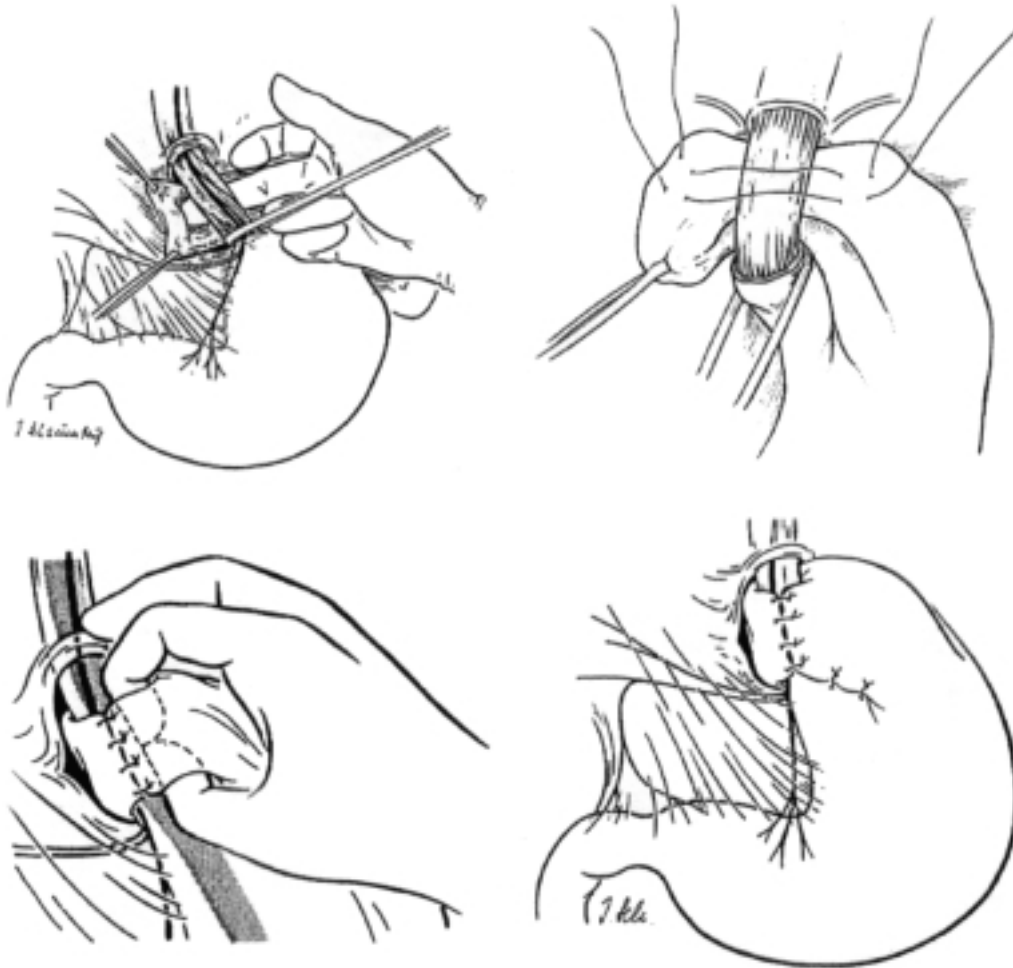


Figure 6. Classical Nissen fundoplication by his first assistant Mario Rossetti. Reproduced with permission from Elsevier Science Inc. *Surgery of the Oesophagus*. Jamieson GG, Ed. Churchill Livingstone, 1988: 250-1.

DeMeester's total fundoplication was short, all short gastric vessels were divided, and the 2cm wrap placed between the oesophagus and the posterior vagal trunk. Like Donahue's wrap, there was space between it and the oesophagus, which incorporated a # 60 bougie during plication. If the cardia could not be brought into the abdomen, he would open the chest to gain more oesophageal length, or change to a Collis-Nissen anti-reflux operation described below.

Tom DeMeester

During the US-Vietnam War, DeMeester was conscripted into the American armed forces. In

charge of healthy troops he had time on his hands. Acid reflux measured by pH recordings above the cardia encountered by people such as Spencer⁴² was recent news. How much and how often was reflux abnormal? DeMeester was able to test symptomatic and asymptomatic volunteers over 24 hours. The response of the airmen for the reward of an extra week's annual leave by swallowing a pH probe for 24 hours resulted in a deluge of volunteers! He found asymptomatic troops refluxed less than 5% of a day, but most symptomatic airmen refluxed for longer periods. Separately, this test became a useful yardstick in the investigation of chest pain⁴⁴.



Figure 7. Ronald H.R. Belsey (contemporary).
Reproduced from the editor's private collection.

Lucius D. Hill III employed a reversed partial fundoplication⁴⁵; his gastropexy was constructed by anchoring the plication to the median arcuate ligament in front of the aorta.

Belsey's 'Mark IV' partial fundoplication⁴³

Ronald Belsey (Figure 7) devised a transthoracic approach which was a partial fundoplication⁴² in the vertical plane, unlike Nissen's horizontal plication. Belsey found his fourth version was reproducible and easily taught to trainees⁴⁶.

Other diverse anti-reflux procedures

Angelchik prosthesis⁴⁷

Jean Pierre Angelchik once assisted a urological colleague who was operating on a patient with urinary incontinence. The procedure required a silicone gel-filled U-shaped prosthesis to be slung around the bladder neck. Angelchik regarded gastro-oesophageal reflux as an example of gastric incontinence, so he designed a similar prosthesis to

surround the cardia. The procedure was easily performed either by open or laparoscopic means. Angelchik's prosthesis encircled the cardia before being tied. It worked well in some, though by no means in all patients. Firm fibrosis around the collar, and migration to above and below the diaphragm reduced its popularity. According to Durrans and colleagues⁴⁸, an unacceptable 17.1% of prostheses had to be removed within 15 months. More serious complications since has caused the operation to be abandoned.

Diversion of gastric and duodenal juices from the stomach

Oesophagitis and oesophageal ulcers have been known to be related to digestive juices since the time of Quincke⁴⁹ in 1879. The acid-peptic element of reflux material has been known since Winkelstein⁵⁰ in 1935. Studies on pH have shown acid reflux coinciding with oesophageal pain or heartburn described by Tuttle and Grossman⁵¹ in 1958.

Bile and pancreatic juices were evaluated in animal and patient studies. Royston and colleagues⁵² applied the principle of diversion of duodenal contents away from the oesophagus in patients. They employed the Roux-en-Y gastrojejunostomy and added a vagotomy to protect the jejunum from stomal ulceration (Figure 8). Washer and colleagues⁵³ showed in 53 severe reflux-strictered patients relief for many could be obtained, with no mortality, by Roux-en-Y duodenal diversion. They, therefore, demonstrated that before the advent of firm fibrosis, reflux oesophagitis could be reversed by depleting duodenal juice from the gastric chyme.

Though successful, diversion procedures and vagotomy are rarely used today because a small number of patients became severely affected by a gastric 'dumping' syndrome, a rare complication notoriously hard to treat. Should the vagotomy be incomplete, stomal ulceration and its complications would follow⁵⁴.

Early laparoscopic operations

As in other surgical procedures, the principles in laparoscopic surgery are the same as used in open surgery. Failure to adhere to these principles has courted disaster.

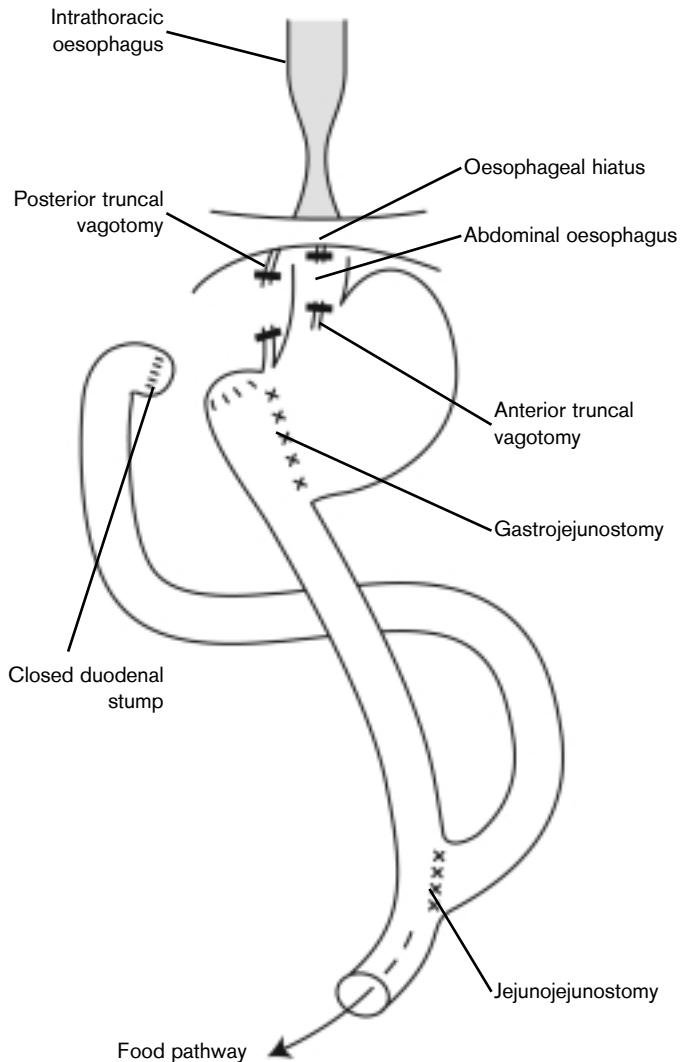


Figure 8. Duodenal juice diversion by Roux-en-Y.

In 1991, Dallemagne and associates⁵⁵ in Belgium and Geagea⁵⁶ in Canada, published their early findings using a minimal invasive approach to anti-reflux surgery.

Initial conversion rates were high: 25% in Belgium, and 10% in Canada, respectively. Today, conversion rates are below 5%. Both groups agreed that the cardia must be brought below the hiatus. The Belgians usually divided the short gastric vessels, but the Canadians usually did not. Just as in cholecystectomy, minimal invasive surgery was less painful and had a shorter hospital stay. The author of Chapter 7, Bernard Launois, informed the authors of this chapter of a rare death after one laparoscopic

repair. However, he also said 10% of the total pharmaceutical budget of Australia is spent on reflux medication. Laparoscopic anti-reflux surgery compared with long-term medical treatment has resulted in surgery being offered across the globe.

Oesophageal strictures

Reflux strictures were a huge problem before modern anti-ulcer drugs became available. Strictured gullets were historically treated in the same way as malignant strictures. They could be treated by the following:

- ◆ dilatation with or without anti-reflux surgery;
- ◆ gastric tubes;
- ◆ whole stomach replacements;
- ◆ jejunal interposition;
- ◆ free vascularised jejunal grafts;
- ◆ colon replacements;
- ◆ vagotomy, antrectomy and Roux-en-Y diversion.

Dilatations with or without anti-reflux surgery

Retrograde dilatation

Before quality instruments with good suction and light, oesophageal dilatation was first paradoxically safer by digital or instrumental means below the diaphragm via a gastrostomy. According to Holmes⁵⁷, in 1883 von Bergmann first published a retrograde dilatation of an oesophageal stricture. The following year he reported the work of Professor Loreta from Bologna University, who had dilated both oesophageal and pyloric strictures by this route. In 1890, Robert Abbe⁵⁸ from New York gained access by a gastrostomy from below and a cervical oesophagostomy from above, to establish safe and repeatable dilatations. Dilatation began with gum elastic bougies; recurrent strictures were split by a 'see-saw' action using the string between the cervical and gastric stomata. In 1894, von Hacker¹⁴ employed a system of graded steel balls attached to fine strings retrieved from a gastrostomy to enable retrograde dilatation. He strongly warned about the ease of instrumental perforation immediately proximal to the stricture.

Prograde dilatation

Dilators evolved according to available endoscopes, the advent of anaesthesia or sedation, and facilities of X-Ray screening for difficult cases. These are (some are illustrated in Figure 9):

- ◆ Negus and Jackson rigid dilators;
- ◆ Moloney mercury-filled flexible tubes;
- ◆ the Eder-Puestow system, incorporating guidewires and threaded olives⁵⁹;
- ◆ Celestin graded plastic dilators mounted on guidewires;
- ◆ more modern balloon-mounted dilators which reduced the need for radiological screening.

by his American colleagues initially, until Jiannu⁶¹ and others around 1912 to 1914, succeeded. Gavrilu⁶² in 1975, added several hundred cases from Romania.

Gastric tubes, lesser curvature

Gastric tubes could also be fashioned from the lesser curvature to make a 'neo-oesophagus'. Collis created a tube or 'neo-oesophagus' out of the lesser curvature known as the Collis gastroplasty (Figure 10)⁶³. It relieved dysphagia but was ineffective against reflux.

Others realised Collis' gastroplasty was worth pursuing provided reflux was controlled. The Collis-Nissen operation emerged although neither Collis nor

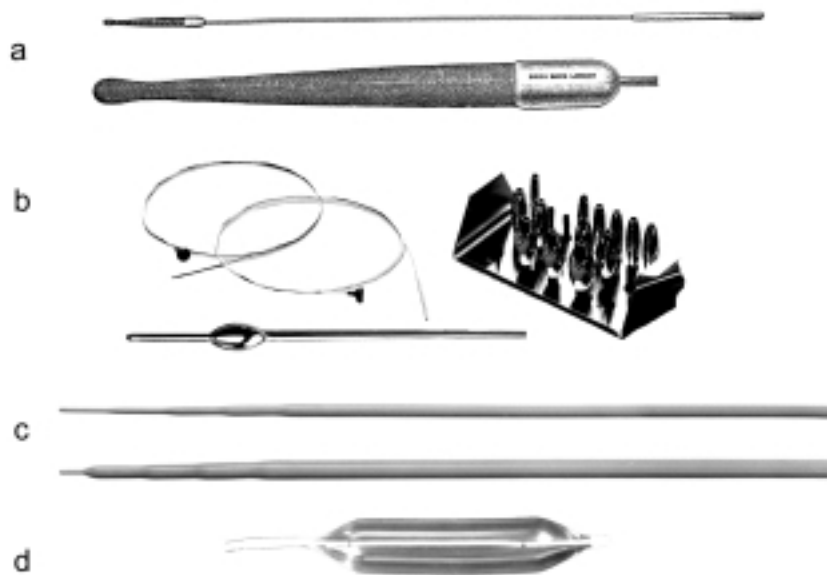


Figure 9. Some of the dilators in historical practice. a) Classical gum-elastic dilator devised by Chevalier Jackson (Down Bros London). *Reproduced with permission from B. Braun Medical Ltd.* b) Eder-Puestow system using staff, guidewire and graded olives. *Reproduced with permission from Olympus-KeyMed Ltd.* c) Graduated Celestin dilators. *Reproduced with permission from LR Celestin FRCS.* d) Typical endoscopically inserted balloon dilator. *Reproduced with permission from Olympus-KeyMed Ltd. (Judy Moss. Medical Photography Dept, Musgrove Park Hospital).*

Gastric tubes, greater curvature

Beck and Carrel⁶⁰ in 1905 described how a greater curvature tube could be used to replace the thoracic oesophagus from animal studies, but Beck was ignored

Nissen ever actually performed this operation! Henderson⁶⁴ in 1977, and Orringer⁶⁵ in 1978 proved it not only relieved dysphagia but also reduced reflux (Figure 11).

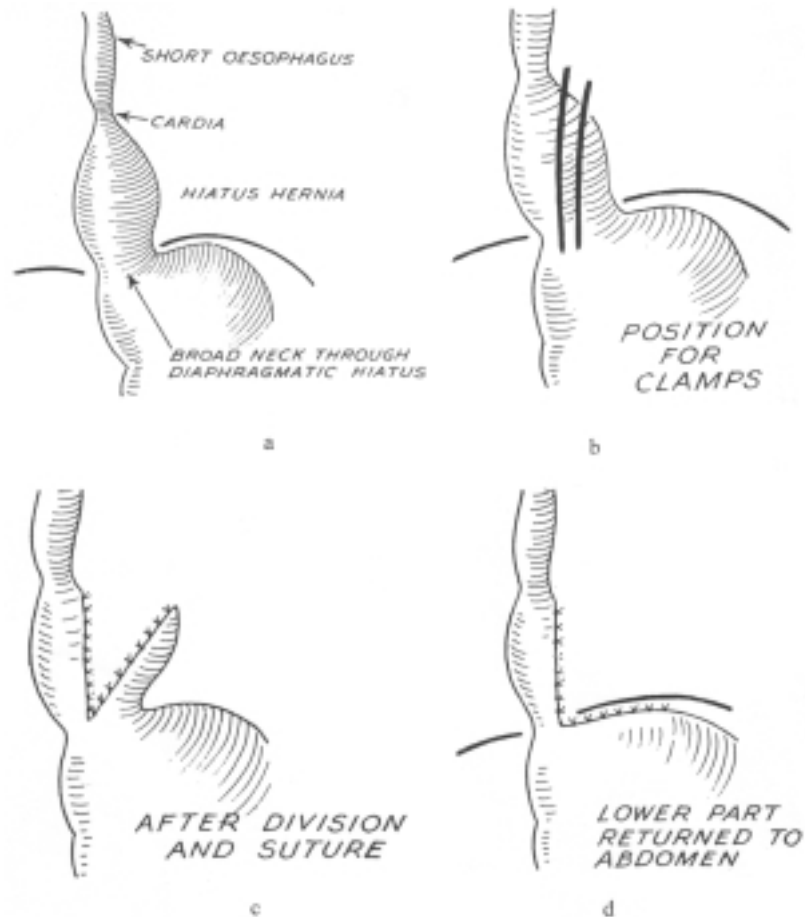


Figure 10. Original Collis gastroplasty. Reproduced with permission from the BMJ Publishing Group. Collis JL. *Gastroplasty*. *Thorax* 1961; 16: 197-9.

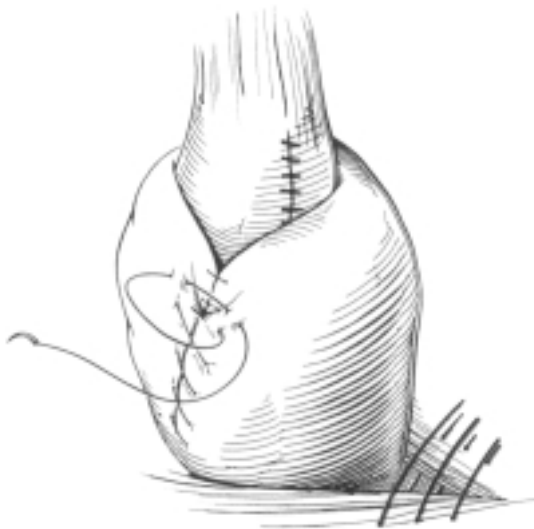


Figure 11. Collis-Nissen gastroplasty by Mark Orringer MD. Reproduced with permission from Elsevier Science. *Surgery of the Oesophagus*. Jamieson GG, Ed. Churchill Livingstone, 1988: 332.

The stages of the operation are summarised as follows:

- ◆ dilatation of the stricture;
- ◆ left thoracotomy with wide clearance around the cardia, preserving the vagus nerves and spleen;
- ◆ stapling of the 'neo-oesophagus' beside a large indwelling tube;
- ◆ fundoplication around the 'neo-oesophagus' to prevent reflux.

Orringer added a drainage procedure if either vagal nerve were cut or stretched, or if dense adhesions from previous surgery were present. This operation for a shortened oesophagus is still popular amongst thoracic surgeons today.

Whole stomach replacement

Kirschner⁶⁶ was the first to demonstrate that a mobilised stomach could reach the neck and beyond, provided it was nourished by the right gastric vessels. Figure 12 also shows his drainage of the redundant oesophagus to a jejunal loop below the stricture.

Jejunum

César Roux⁶⁷ from Lausanne, (Figure 13) achieved a huge step forward in 1907, when he resected a lye stricture of a young child mobilising a pedicled segment of jejunum from the stomach seen in Figure 14. The girl was fed by gastrostomy until the jejunal conduit was connected four years later.

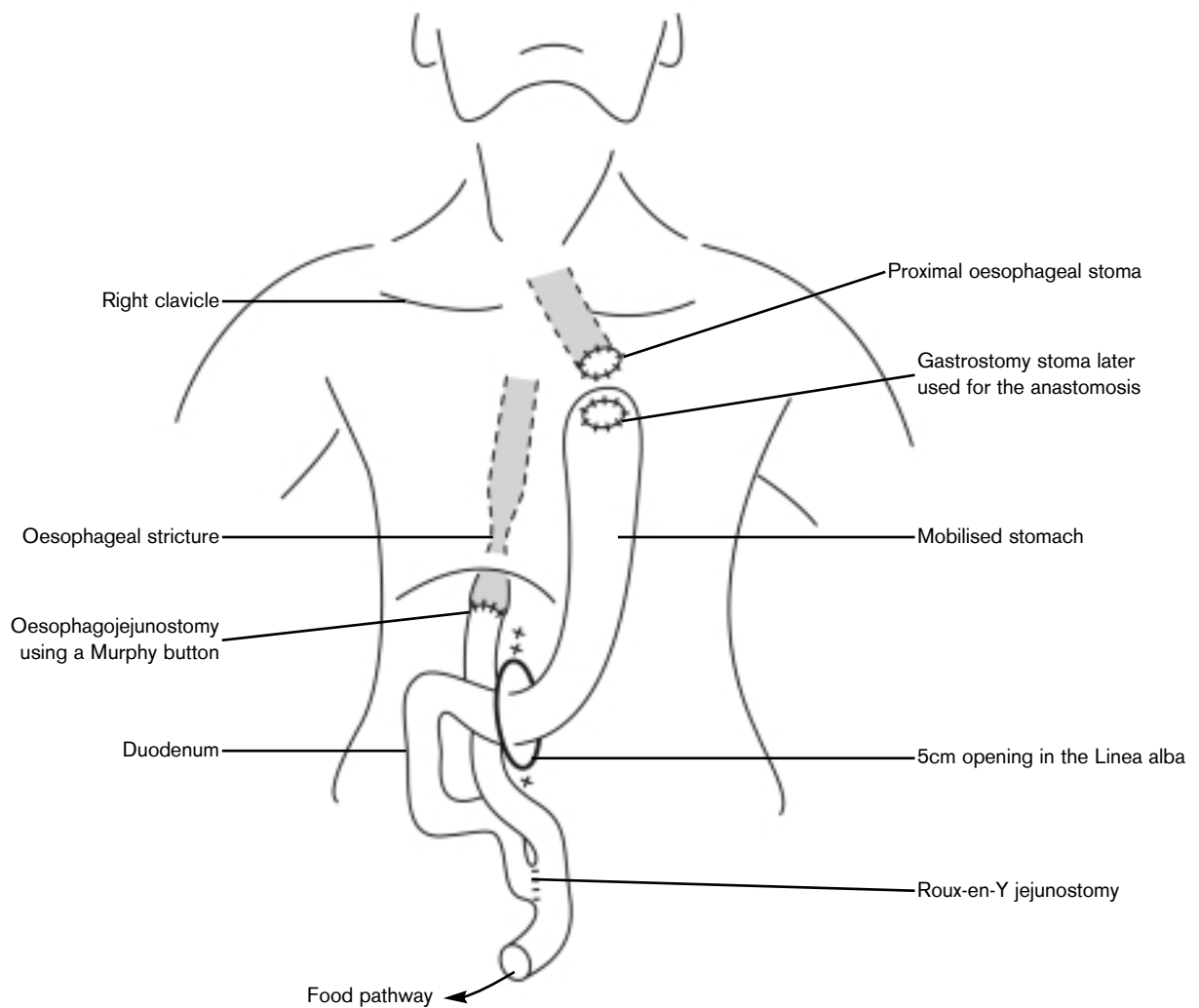


Figure 12. Kirschner's oesophageal replacement using whole stomach.



Figure 13. César Roux of Lausanne (1857-1934). Reproduced with permission from the *Institut d'Histoire de la Médecine et de la Santé, Lausanne, Switzerland.*

Colon replacement

In 1911, Kelling⁶⁸ was on one occasion trying to perform a jejunal conduit to bypass a mid-oesophageal cancer, but found the mesentery too short to reach the cervical oesophagus. He was forced to insert a segment of transverse colon within a subcutaneous tunnel over the sternum. Though this was viable and the principle was established, the patient died from an unrelated cause before swallowing could be restored. Vulliet⁶⁹ succeeded in replacing a benign stricture with a length of colon. He used temporary vascular clamps on the vessels before resection and Roith⁷⁰ employed the right colon to bypass a stricture 13 years later. Subsequently, Belsey⁷¹ and others used the left colon for benign stricture on a regular basis.

Achalasia of the cardia

(Greek 'chalis' = relaxation, therefore 'achalasis' = failure to relax.)

The treatment of this disease was controversial in the early days, because the cause was not understood until the middle of the 20th century.

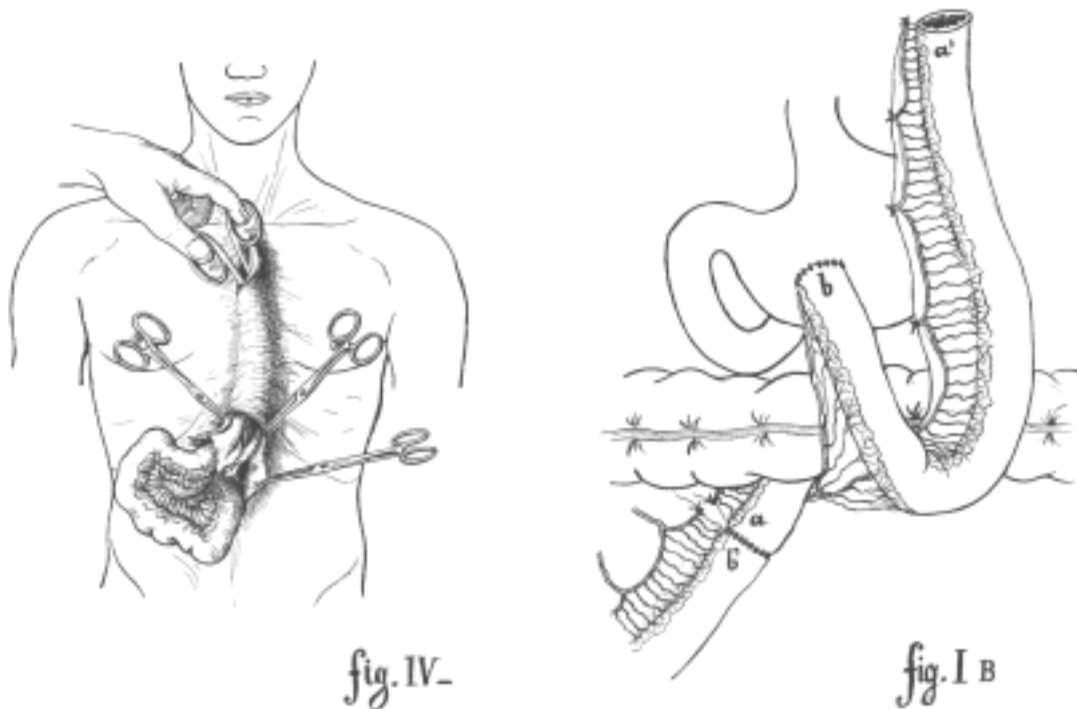


Figure 14. Roux's subcutaneous jejunal conduit. Reproduced with permission from the *Institut d'Histoire de la Médecine et de la Santé, Lausanne, Switzerland.*

Yet over 300 years ago, Thomas Willis, a founding member of the future Royal Society of London, believed the dysphagia was due to absent or poor relaxation of the muscles around the gastro-oesophageal junction. Kittle ⁷² quotes Willis' description in 1679 very graphically: "The patient otherwise healthful enough, was wont, very often, to cast up whatsoever he had eaten He would eat until the Oesophagus was filled up to the throat, nothing sliding down to the Ventricle (stomach), he cast up raw or crude whatsoever he had taken in I prepared an instrument for him like a rod of a whale bone with a little round button of sponge fixed to the top of it." He then started a series of dilatations with this probang for the patient whenever the dysphagia returned. Neither the clinical description, nor the treatment could have been bettered. The patient was able to swallow over the following 15 years thanks to Willis' expert repeated dilatations. According to Meade ¹⁰ Willis implied the correct explanation when he wrote that: "..... the mouth of the stomach always being closed, either by tumour or palsie, and nothing could be admitted into the Ventricle (stomach) unless it was violently opened."

Historical treatments

As dilatations were not universally successful, other methods of relieving the dysphagia had to be tried. 'Spasm' was believed the cause for a long time, but it was von Mikulicz ⁷³ who perpetuated the misnomer of 'cardiospasm'. The explanation was not realised until 1888 when an American, Max Einhorn ⁷⁴, and the German, Meltzer ⁷⁵, independently suggested that 'spasm' of the cardia was not correct. According to Hertz ⁷⁶ in 1915, Perry from the US and Sir Arthur Hurst from the UK coined the term 'achalasia' (failure of relaxation). Treatments included:

- ◆ forceful retrograde dilatation (Mikulicz-Schloffer) ⁷⁷;
- ◆ oesophagostomy (Zaaijer) ⁷⁸;
- ◆ oesophagogastrostomy (Heyrovsky) ⁷⁹;
- ◆ cardioplasty (Wendel) ⁸⁰;
- ◆ myotomy at the junction (Heller) ⁸¹.

Gottstein ⁸², in 1904, suggested a procedure resembling Ramstedt's procedure, but it was Ernst Heller ⁸¹ (Figure 15) in 1913, that actually put it into

practice. Heller planned to do a cardioplasty such as that devised by Heyrovsky, but at operation he found the mega-oesophagus grossly thickened and difficult. He described the oesophagus as big as "a chimney of a kerosene lamp!" He performed an anterior extramucosal myotomy parallel to the long axis of 8cm in length, which he covered with a strip of netting to prevent leakage from such a long myotomy, and did a similar myotomy posteriorly.



Figure 15. Ernst Heller (1877-1964). *Reproduced from the editor's private collection.*

The patient suffered from a postoperative pneumonia, from which he recovered, but was eating solid food on the eighth day. Steichen and associates ⁸³ reported that the same patient was eating well eight years later!

The complications of cardioplasty and oesophagogastrostomy were elegantly described by Barrett and Franklin ⁸⁴ in 1949. Relief of severe dysphagia would be dramatic for three to six months and then a new dysphagia, often accompanied by anaemia caused by bleeding followed because of severe reflux oesophagitis. Conversion to myotomy rescued many of these patients.

Cardiomyotomy caught on quickly. Berg in America in 1918, followed by Rowlands in the UK in 1920 achieved success without the punishing postoperative reflux that followed the cardioplasties, and the subsequent results across the world were well recorded by Ellis and associates ⁸⁵.

Many have found a single anterior seromyotomy performed laparoscopically has been satisfactory following Pinotti's ⁸⁶ publication.

Oesophageal cancer

Cancer of the cervical oesophagus

First attempts at resection were made on the cervical oesophagus, because of its relative accessibility. In 1877, Czerny ⁸⁷ (Figure 16) under Billroth did the first resection in a patient. At that time there was no attempt at restoring continuity, so the patient was left with a proximal cervical stoma and a distal thoracic oesophageal opening for feeding purposes. He reported: "In a case of annular carcinoma of the esophagus which caused a stricture that would not admit an esophageal sound I resected a 6cm piece of the entire wall of the esophagus, and sutured the lower end into the neck." The patient died three months later from local recurrent disease occluding the lower stoma.

Billroth ⁸⁸ himself resected a larger cervical oesophageal cancer including the larynx and thyroid two years later. The patient died six weeks later from mediastinitis from perforation during dilatation for feeding tube insertion. According to Mikulicz ⁸⁹, by 1885 Billroth had completed nine cervical resections with five deaths; the four survivors lived between three and 12 months. Mikulicz ⁹⁰ successfully excised a cervical oesophageal tumour and restored continuity with a skin tube. His patient survived for 11 months, quite remarkable for those days.

Wilfred Trotter ⁹¹ from London must have been congratulated for dogged perseverance in 1925, when he resected a cervical carcinoma. Below is the order of events:

- ◆ preliminary gastrostomy and dental clearance;
- ◆ skin flap based from the right side of the neck,




Figure 16. Vincenz Czerny (1842-1916). *Reproduced with permission from the Wellcome Library, London.*

placed behind the mobilised oesophageal tumour and sutured to the left neck;

- ◆ oesophageal tumour resected and the ends left open, similar to Czerny;
- ◆ continuity with the skin flap delayed by the need for node dissection on the left, dilatation of the lower stoma, then radiotherapy to local recurrences;
- ◆ finally, the skin tube was joined to each end of the oesophagus.

Death occurred ten years later from cordoma of the sacrum; the new oesophagus was perfect at autopsy.

A revolutionary technique was introduced in 1959 by Seidenburg and Hurwith ²⁵ involving microvascular expertise. A short segment of jejunum was taken from the abdomen and two anastomoses made between the internal jugular vein, and the superior thyroid artery with the mesenteric vessels. Following this, the pharynx above and the thoracic oesophagus below were joined after the vascular connection.

Remaining oesophagus

Von Ach ⁹² (1913) in Munich, Germany, performed a blunt transhiatal resection for mid-oesophageal cancer, via the neck and abdomen without restoring continuity, leaving a cervical oesophagostomy and a feeding gastrostomy. This could be described as two-thirds of a transhiatal oesophagectomy. This patient survived.

In 1913, Franz Torek made history with his transpleural resection ⁵.

Here were the stages in this historic operation:

- ◆ a preliminary gastrostomy was constructed for nourishment;
- ◆ the left chest opened, many pleural adhesions divided, and by pushing the aortic arch forward, he was able to divide oesophageal arterial branches and free the upper oesophagus;
- ◆ he carefully preserved as many vagus nerves as possible, because Sauerbruch had told him division of the vagal branches meant instant death!;
- ◆ the healthy oesophagus was divided well above the tumour and brought out of the neck, to be tunnelled to the left second intercostal space;
- ◆ the lower stump was invaginated into the stomach after removal of the tumour, retreating from the pleural cavity without drainage;
- ◆ the ribs were approximated with strong silk, the muscles with catgut and the skin with interrupted silk sutures;
- ◆ on the eighth postoperative day a rubber tube connected the cervical oesophagus to the gastrostomy permitting swallowing from mouth to stomach.

The tumour was a squamous carcinoma with node involvement. Surgery ended here because the patient refused any more treatment, but his rubber 'neo-oesophagus' worked perfectly well for 13 more years!

Torek never had an opportunity to repeat this operation, but must have been chagrined to listen to Garlock ⁹³ present three identical resections later. Worthy of comment was the achievement of von Ach who changed from his transhiatal method to Torek's method (according to Meyer ⁹⁴), on one occasion resecting a tumour in one hour and 25 minutes! Despite Torek's publicity, there were few successes. Ochsner

and DeBakey ⁹⁵ reported 17 survivors out of 58 published Torek resections, with a worrying mortality of 70%.

Rovsing ⁹⁶ in 1926 was extremely aware of the dangers of infection, so he avoided colonic tubes ^{69, 70}. Having observed from contrast studies that both peristaltic and anti-peristaltic tubes of stomach ^{60, 66, 68} and intestine tend to become passive or inert after a month, illustrated by Torek's 'rubber oesophagus', he succeeded several times with a staged procedure with minimal contamination of the peritoneum. He started with a feeding gastrotomy, next a cervical oesophagostomy, then he inserted a long skin tube close to the stomata buried under an ante-thoracic flap, before finally joining the skin tube ends to the oesophageal and gastrostomy stomata.

Grey Turner ⁹⁷ from Newcastle-upon-Tyne (UK) successfully emulated Rovsing's procedure with a mid-thoracic resection. The patient swallowed well after 206 days! By the end of his surgical career Turner had completed 25 resections. The operability rate was 44% and the mortality 40%. There were three long-term survivors.

While the rest of the surgical world was staying outside the chest, a remarkable Japanese surgeon paved the way for future advance. In 1933, Ohsawa ⁹⁸ from Kyoto published a series started in 1925 using the whole stomach for replacement. He performed a transpleural resection with immediate anastomosis successfully in eight out of 19 resections. He did not require Sauerbruch's chamber, underwater seal drainage, or positive pressure endotracheal ventilation.

The year of 1938 heralded the beginning of transpleural resections of the cancer followed by immediate oesophago-gastric anastomosis across the globe. Marshall ⁷ in Boston first, followed by Adams and Phemister ⁹⁹ in Chicago successfully resected mid-thoracic cancers this way. Marshall's patient had node metastases and recovery was complicated by wound dehiscence, but the patient survived for nearly a year.

Adams and Phemister succeeded using general anaesthesia without an endotracheal tube, after opening the chest through the bed of the resected eighth rib. They crushed the left phrenic nerve believing that the diaphragm should be rested. Next the oesophagus and stomach were mobilised through

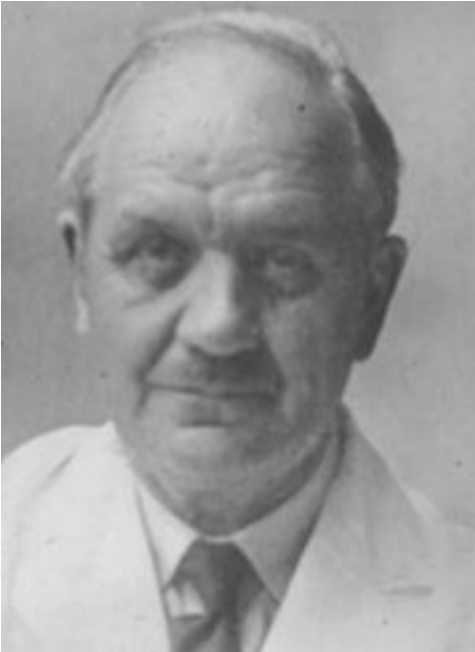

Figure 17. Ivor Lewis (1895-1982).
Courtesy of Mr. Gareth Morris-Stiff MB, BCh MD FRCS.

the enlarged hiatus and at least 10cm of oesophagus and 5cm of stomach were resected with the tumour. The gastric fundus was anchored to the posterior wall of the mediastinum before performing the anastomosis in two layers of interrupted linen. The diaphragm was closed below the anastomosis and a mushroom catheter was used as a gastrostomy feeding tube, while a De Pezzar catheter was used as an intercostal drain. The skin incision was closed with silk, and oral feeding commenced at 14 days. The first patient lived for ten years, despite coeliac node involvement.

Many contemporaries were reluctant to follow, and continued other routes for restored swallowing for some years until Ivor Lewis¹ (Figure 17) published seven operations evolving from Torek procedures to his two-incision operation in 1946:

- ◆ patients 1-3. These were left or right-sided Torek procedures with one 30-day death;
- ◆ patients 4 and 5. One-staged oesophago-gastrectomy via a left thoracotomy. One patient died on the table from a pneumothorax and pulmonary embolism;
- ◆ patients 6 and 7. Staged procedures using a vertical abdominal (left paramedian) incision followed by a right thoracotomy resecting the tumour and joining the oesophagus to the stomach by an oesophagogastrostomy shown in Figure 18. Both patients did well. He finished his career by doing the operation in one session afterwards. This is known today as the 'Ivor Lewis' approach and is the most used approach in the UK.

Up to 1940 the mortality after operative treatment for this disease was high and according to Ochsner and De Bakey⁹⁵, it ranged between 59-101 deaths in 191 resections. However, Sweet¹⁰⁰ in 1948, had a reduced mortality of 16.5% in 181 resections. After World War II was over, anaesthesia improved, antibiotics and safer blood transfusions helped to improve the outcome all over the world. Table 1 below shows the mortalities in expert hands between 1954 and 1959. Nakayama¹⁰¹ showed the combination of early diagnosis, slim patients and vast skilful experience could produce an enviably low mortality.

Table 1. Mortality of oesophageal cancer¹⁰¹.

Department	Year of publication	Resections	Mortality %
Garlock	1954	75	33
Sweet	1954	Middle third 120	25
		Lower third 167	12
Nakayama	1959	953	Extrathoracic 5.8 Intrathoracic 15

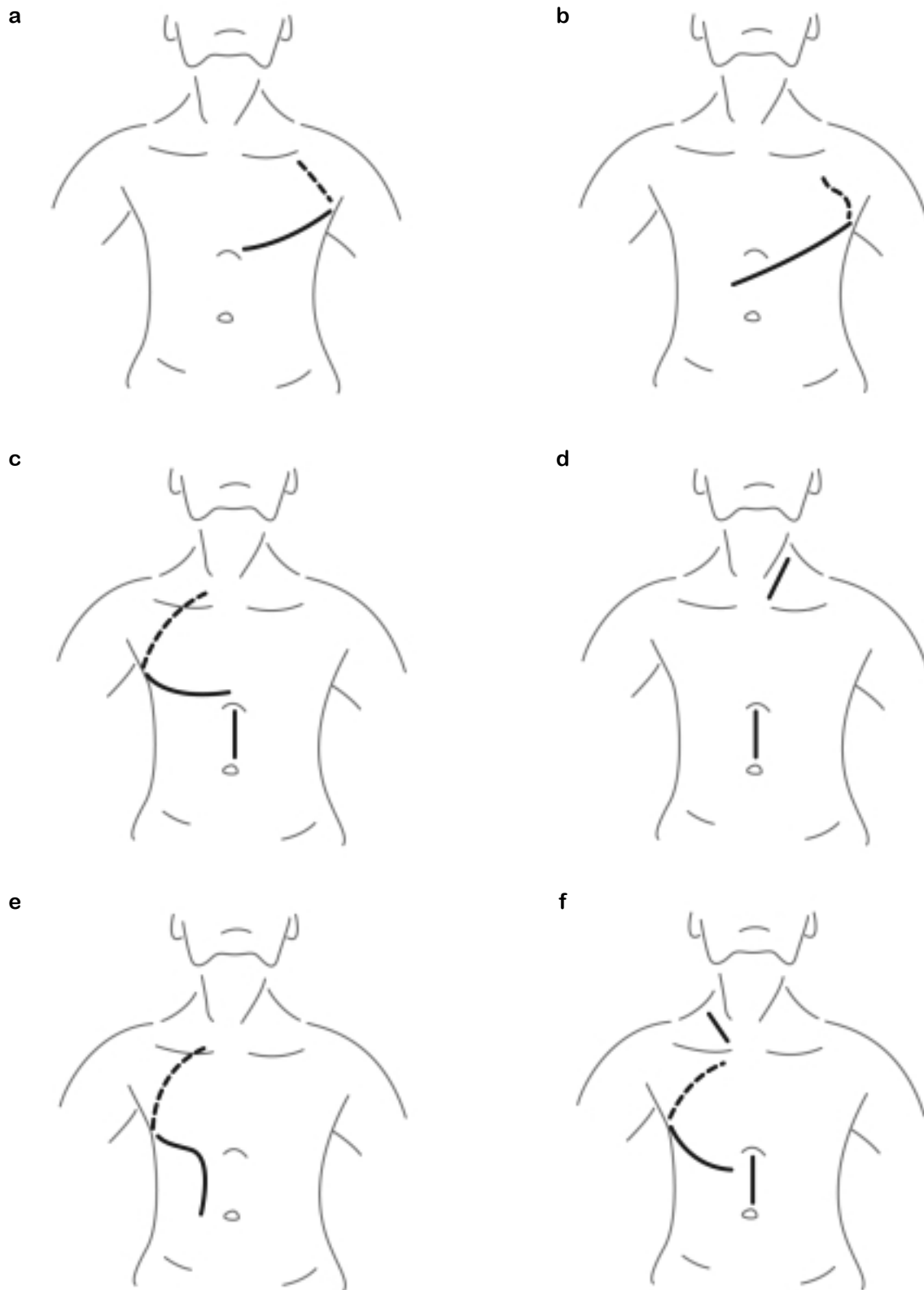


Figure 18. Common incisions for oesophagectomy. a) Left thoracic (Sweet). b) Left thoraco-abdominal (Collis-Belsey). c) Abdominal and right thoracic (Lewis). d) Transhiatal (Orringer). e) Right thoraco-abdominal (Nakayama and Wastell). f) Three stage (McKeown and Hennessey).

Churchill and Sweet¹⁰² were usually comfortable with a left thoracotomy alone. They improved access to the stomach by opening the diaphragm, preserving the phrenic nerve. Garlock, Belsey and Collis and many others used the thoraco-abdominal route. Nakayama used a right thoraco-abdominal incision for middle third cancers and left thoraco-abdominal for lower third cancers in 1976.

McKeown¹⁰³ modified the Ivor Lewis approach, by adding a right cervical incision as a third stage. Matthews¹⁰⁴, in 1987, added a neck incision to the left thoraco-abdominal incision, gaining good access for the anastomosis in the neck. Most of these incisions are shown in Figure 18.

In 1988, Orringer²³ from Michigan extended von Ach's operation⁹² by the same approach from the abdomen and neck, but completed the anastomosis in a similar fashion as performed by McKeown, after drawing up the stomach through the posterior mediastinum where the oesophagus used to lie. He described this as a 'transhiatal' oesophagectomy. His mortality was very low (6%) and the five-year survival rate was 22% in 130 patients. The hope for fewer respiratory complications was not realised. Wong¹⁰⁵ regarded it a palliative operation, and since the advent of thoracic epidural anaesthesia, the case for avoiding thoracotomy was no longer justified. Both he and Nakayama acquired huge series because of the increased prevalence of squamous cancer of the oesophagus in the Far East.

Cancer of the cardia

Arguments have taken place for years about this tumour. Is it an oesophageal tumour growing downwards, or a gastric tumour growing upwards? It is indeed an enigma, especially when it is large. According to Meyer⁹⁴, von Hacker first combined the two as a single entity, long before knowledge of the *Helicobacter* organism.

Friedrich Voelcker¹⁰⁶, another Billroth pupil, successfully resected a carcinoma of the cardia via an abdominal incision, after considerable downward traction on the oesophagus. The result was like an upside-down Billroth I anastomosis.

Barrett¹⁰⁷ coined the term 'congenital short oesophagus', because he defined the oesophagus as lined only by squamous epithelium. Cedric Bremner¹⁰⁸ showed in animal studies that if the lower sphincter was destroyed, the columnar epithelium extended proximally, so a 'columnar-lined oesophagus' was not congenital but an acquired condition.

In recent years there has been a realisation that the columnar-lined oesophagus is prone to malignant change. Van der Burgh and colleagues¹⁰⁹ studied a group of patients who had established Barrett changes, and while they found a 30 to 40 times increased risk of cancer, they found widespread screening detected only one cancer in 180 patient years, therefore proving too costly. Because 10% of Western populations have some reflux disorder, surveillance of the minority with Barrett's oesophagus had the advantage of monitoring changes from dysplasia to cancer and a chance of cure.

Pioneers in palliation of malignant disease

Most oesophageal cancers have presented late over the centuries. Parts of the world have programmes to detect early tumours, but certainly in the Western Hemisphere, inoperable tumours all too frequently are encountered. Options for palliation have been:

- ◆ repeated dilatations;
- ◆ radiotherapy;
- ◆ laser canalisation;
- ◆ diathermy destruction;
- ◆ alcohol injections;
- ◆ chemotherapy;
- ◆ intubations.

Historically, surgical pioneers have been involved in intubation. The authors are aware of at least ten types of tubes to enable swallowing. Materials such as decalcified ivory¹¹⁰, stretched de Pezzar catheters¹¹¹, silicone rubber¹¹² and assorted plastic tubes^{113, 114} have been used.

In 1885, Charters Symonds¹¹⁵ was concerned about the indignity of saliva overspill for good terminal care. He stented tumours with a boxwood funnel in

4 The changing tides in oesophageal surgery

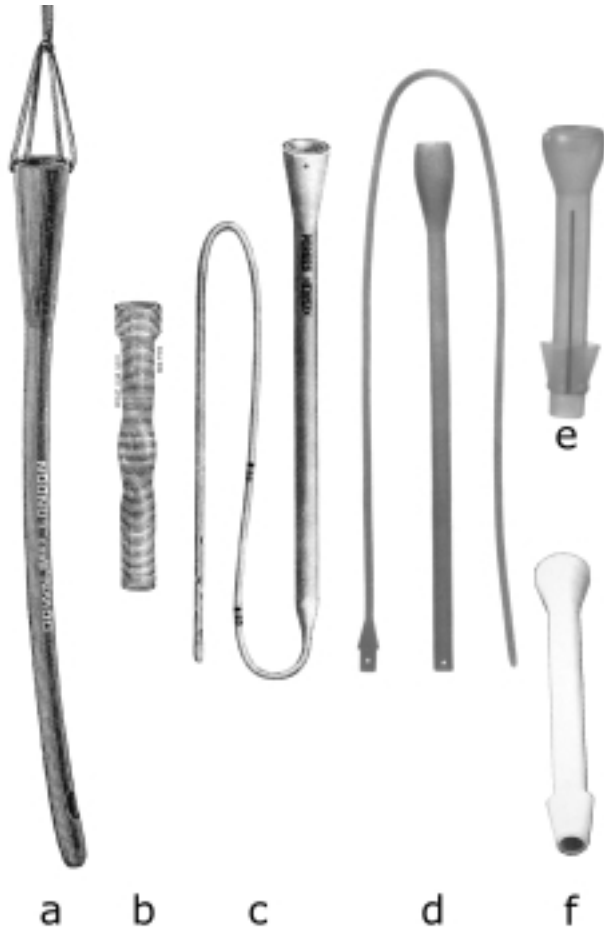


Figure 19. Assorted stents used in the palliation of oesophageal cancer. a) Symonds string suspended gum-elastic (initially boxwood) tube (Down Bros. London). b) Souttar coiled steel spiral tube inserted endoscopically (Down Bros. London). c) Mousseau-Barbin Neoplex tube placed by traction via gastrotomy (Down Bros. London). a) b) & c) Reproduced with permission from B. Braun Medical Ltd. d) Celestin oval polythene tube reinforced by nylon spiral placed by traction as above. e) Celestin skirted tube to deter up or down displacement inserted endoscopically. d) & e) Reproduced with permission from L.R. Celestin FRCS. f) Atkinson silicone rubber tube inserted endoscopically. Reproduced with permission from Olympus-KeyMed Ltd. (Judy Moss. Medical Photography Dept, Musgrove Park Hospital).

order to administer fluid and morphine by stomach tube. In 1927, Henry Souttar endoscopically inserted his funnelled wire tube with a spiralled stem to be gripped by the tumour when in place ¹¹⁶ (Figure 19). If displaced it could be cleaned, sterilised and reused!

In 1956, Roger Celestin ¹¹⁷ as a trainee was dissatisfied with stiff plastic tubes which often eroded through the oesophagus. After chewing and swallowing numerous breakfasts down tubes of varying diameters, he discovered an internal diameter of 11mm was the minimum diameter to permit normal food into the stomach apart from the adhesive qualities of fish. His latex-funnelled tube incorporated a stiff nylon spiral (Souttar's principle) and an added radio-opaque strip. His early tubes were inserted at operation by traction, later endoscopically by pulsion. Celestin did not advocate his tube for benign strictures, not only prey to digestive enzymes, but also prone to more reflux. Expandable stents came into use since 1993 ¹¹⁸. Despite their greater cost, they were found to have a lower mortality and morbidity according to Jethwa and colleagues ¹¹⁹.

Conclusions

The tides have turned since the second half of the 20th century. Most foreign bodies are removed in minutes by non-surgical endoscopists, using better equipment without general anaesthesia.

Except for small uncomplicated perforations, knowledge of the options described in the chapter is still required and to be applied with urgency. The same urgency is required for damage to the oesophagus by noxious substances.

Gastro-oesophageal reflux still requires surgical attention. Some governments are aware that early effective laparoscopic surgery makes better economic sense than long-term medication. Proton pump inhibitors, safe dilatation and timely anti-reflux surgery have all reduced the number of tough reflux strictures today.

Achalasia remains uncommon, but is easily managed by balloon dilatation in the frail and laparoscopic myotomy for the robust; very few require open surgery.

Despite some surveillance programmes of columnar-lined or 'Barrett's oesophagus' patients today, most cancers are diagnosed far too late in the Western Hemisphere. It is still not understood why carcinoma of the lower third and cardia has trebled in the last 20 years. Topical ablation of the Barrett epithelium by laser is still under revue. Minimal invasive surgery of established cancer shows no advantage over open oesophagectomy so far.

There is now no room for prima donnas in oesophageal surgery; curative surgical treatment emerges from effective teamwork. This team includes radiologists, oncologists, anaesthetists, dedicated nurses, as well as the technically gifted heirs of our surgical pioneers.

Biographical footnote on Rudolf Nissen




Figure 20. Rudolf Nissen (1896-1981).
Reproduced with permission from the Nissen family and Professor Liebermann-Meffert.

This remarkable man was one of three children born in Neisse, which was situated in Prussia after 1742 before becoming part of Germany. (This town is now part of Poland since the end of World War II). His father Franz was a busy surgeon, so all the children were brought up in a hectic surgical atmosphere in his father's hospital, and it was no surprise that Rudolf followed in the family tradition.

His school education was mainly in the classics in a strict Catholic school, with little exposure to modern languages. He was an artist, a peace lover and adored his native countryside.

When he left school aged 17 he joined the Army in World War I. Though attached to a casualty station he himself succumbed to several injuries, the worst being severe lung contusion. At the end of that war he entered formal medical studies in Marburg and

Breslau (now Wroclaw in Poland.). After six months in internal medicine, he spent a year studying pathology under Professor Ludwig Aschoff in Freiburg.

Aged 25 he found himself at the University Hospital in Munich on the surgical staff under the newly arrived Professor Ferdinand Sauerbruch, who soon noticed the high quality of research and hard work from this young trainee. Sauerbruch took Nissen into his entourage when promoted to work in the elite Charité Hospital in Berlin. During this critical period Nissen performed several 'firsts':

- ◆ in 1930, he performed the first successful pulmonary lobectomy for tuberculosis;
- ◆ in 1931, he performed the first successful pneumonectomy for a chronic lung abscess sequel to a car accident;

- ◆ in 1933, he performed the first surviving total colectomy with ileorectal anastomosis for familial polyposis, without ileostomy.

With his metaphorical star in the ascendant, he was absolutely horrified by the surrounding political unrest, the economic unrest, and the anti-Semitic behaviour of the National Socialist Party under Adolf Hitler. As his mother was Jewish he resigned his post with a heavy heart partly because of the political atmosphere inside and outside the University Hospital, and partly because not even the celebrated Sauerbruch could guarantee protection. He married his wife Ruth on May 24th 1933.

Sauerbruch supported his successful application to the post of Head of Surgery in Istanbul. This is where in 1937 he made the discovery of his famous anti-reflux junction between the oesophagus and the residual stomach resembling a Witzel gastrostomy. His five-year contract ended in 1938. He did not renew this as it was obvious that another world war was imminent. He emigrated to America in 1939, and at first his German nationality created difficulty in gaining surgical appointments.

In America he became a research fellow under Edward Churchill in the famous Massachusetts General Hospital, where he worked tirelessly on his research and his command of the English language. In 1941 he was appointed to the Jewish and Maimonides Hospitals in Brooklyn, New York, to be followed by an academic appointment in the Long Island College of Medicine. He became an American citizen. By this time his reputation had escalated and he had acquired a clientele of famous patients such as Albert Einstein.

At the end of World War II he declined several chairmanships in Germany, but because of both clinical and research possibilities, and the bonus of being able to resume speaking and writing in his native language, he accepted the Headship of the Department of Surgery in Basle, Switzerland. He did not remain in an 'Ivory Tower' in Basle, but welcomed all surgical colleagues and trainees around him to integrate postgraduate surgical education throughout the canton (province). Furthermore, he became a Swiss citizen, and settled permanently in Basle.

He abhorred unnecessary chatter in the operating theatre; he was a meticulous technician and combined this with shrewd clinical judgement. It was during the late '50s and early '60s he perfected his famous fundoplication with his bright young colleague Mario Rossetti. At first it was combined with gastropexy, but that was abandoned as unnecessary. The majority of modern anti-reflux surgical operations today, especially laparoscopic operations, are modified from the original Nissen-Rossetti fundoplication illustrated in this chapter.

He was a world surgeon not just in the political sense because of his German, Turkish, American and finally Swiss citizenships, but because of his international surgical reputation. He retired in 1967 to continue private practice for a short time, but more especially to complete the writing of the books and articles on his life's work. He was loyal to his staff at all levels and especially to the residual band of co-trainees who had also worked for Sauerbruch. He visited the latter once in 1948. He continued his love of poetry and the classics and, while physically capable, his love of skiing and hiking in his cherished Swiss mountains.

Dorothea Liebermann-Meffert MD FACS
Walford Gillison FRCS

References

- Lewis I. The surgical treatment of carcinoma of the oesophagus, with special reference to a new operation for growths in the middle third. *Br J Surg* 1946; 34: 18-31.
- Nuland SB. The past is prologue: surgeons then and now. *J Am Coll Surg* 1998; 186(4): 457-65.
- Sauerbruch F. Über die Ausschaltung der schädlichen Wirkung des pneumothorax bei intrathorakalen Operationen. *Zentralb Chir* 1904; 31: 146-9.
- Brauer L, Petersen P. Ueber eine wesentliche Vereinfachung der künstlichen Atmung nach Sauerbruch. *Z Physiol Chem* 1904; 41: 299-302.
- Torek F. The first successful case of resection of the thoracic portion of the oesophagus for carcinoma. *Surg Gynec Obstet* 1913; 16: 614-7.
- Rowbotham ES, Magill IW. Anaesthetics in the plastic surgery of the face and jaws. *Proc Roy Soc Med (Anes)* 1921; 14: 17-27.
- Marshall SF. Carcinoma of the esophagus: successful resection of the lower end of esophagus with re-establishment of esophageal gastric continuity. *Surg Clin N Am* 1938; 18: 643-8.
- Lassen HCA. A preliminary report on the 1952 epidemic of poliomyelitis in Copenhagen. With special reference to the treatment of acute respiratory insufficiency. *Lancet* 1953; 1: 37-41.
- Modlin IM. *A Brief History of Endoscopy*. Milano: Arti Grafiche Pizzi, 1999: xi.
- Meade RH. *History of Thoracic Surgery*. Springfield, Illinois, USA: Charles C. Thomas, 1961.
- Cheever DW. *Two cases of oesophagotomy for removal of foreign bodies*. Boston: James Campbell, 1867.
- Enderlen E. Ein Beitrag zur Chirurgie des hinteren Mediastinum. *Dtsch Z Chir* 1901; 61: 441-95.
- Edmondson JM. History of the instruments for gastrointestinal endoscopy. *Supplement to Gastrointestinal Endoscopy* 1991; 37: 2: S27-S56.
- Hacker von V. Erfahrung über die Entfernung von Fremdkörpern mittelst der Oesophagoskopy. (mit Demonstration der entfernten Fremd Körper.) *Vehr Dtsch Ges Chir* 1898; 27: 144-8.
- Liebermann-Meffert D, Brauer RB, Stein HJ. Boerhaave's syndrome: the man behind the syndrome. *Diseases of the Esophagus* 1997; 10: 77-85.
- Barrett NR. Report of a case of spontaneous perforation of the esophagus successfully treated by operation. *Br J Surg* 1947; 35: 218-9.
- Menguy R. Near-total oesophageal exclusion by cervical oesophagostomy and tube gastrostomy in the management of massive esophageal perforation: report of a case. *Ann Surg* 1971; 173: 613-6.
- Abbott OA, Mansour KA, Logan WD Jr., et al. Atraumatic so-called spontaneous rupture of the esophagus. *J Thorac Cardiovasc Surg* 1970; 59: 67-83.
- Seybold WD, Johnson MA III, Leary WV. Perforation of the esophagus. *Surg Clin N Am* 1950; 30: 1155-83.
- Blalock J. Primary esophagectomy for instrumental perforation of the esophagus. *Am J Surg* 1957; 94: 393-7.
- Postlethwait RW. Colonic interposition for esophageal substitution. *Surg Gynecol Obstet* 1983; 156: 377-82.
- Constanzo J, Noirclerk M, Jouglard J, et al. New therapeutic approach to corrosive burns of the upper gastrointestinal tract. *Gut* 1980; 21: 370-5.
- Orringer MB. Transhiatal esophagectomy without thoracotomy for carcinoma of the thoracic esophagus. *Ann Surg* 1984; 200: 282-90.
- Yudin S. The surgical construction of 80 cases of artificial esophagus. *Surg Gynecol Obstet* 1944; 78: 561-85.
- Seidenburg B, Hurwith AJ. Immediate reconstruction of the cervical oesophagus by a re-vascularised jejunal segment. *Ann Surg* 1959; 149: 162-71.
- Tucker G. Cicatricial stenosis of the esophagus, with particular reference to treatment by continuous string, retrograde bougienage with the author's bougie. *Ann Otol Rhinol Laryngol* 1924; 3: 255-87.
- Kiviranta VK. Corrosion carcinoma of the esophagus: 381 cases of corrosion and nine cases of corrosion carcinoma. *Acta Otolaryngol (Stockh)* 1952; 42: 89-95.
- Jackson C. Esophageal stenosis following caustic alkalis. Necessity for the compulsory labelling by Grocers. *JAMA* 1907; 55(22): 1857-8.
- Paré A. *Labor improbus omnia vincit*. Translated from JP Malgaignes. Oeuvres Complètes. Paris 1840. Springfield, IL: Charles C. Thomas, 1960.
- Bright K. Account of a remarkable misplacement of the stomach. *Guy's Hosp Rep* 1836; 1: 598-603.
- Bowditch HI. *A treatise on diaphragmatic hernia*. Jewett Thomas and Co., 1853 (from the Library of ED Churchill MD).
- Scudder CL. A case of non-traumatic diaphragmatic hernia operation and recovery. *Trans Am Surg Assoc* 1912; 30: 428-47.
- Allison PR. Reflux esophagitis: sliding hernia and anatomy of repair. *Surg Gynec Obstet* 1951; 92: 419-31.
- Nissen R. Die transpleurale Resektion der Kardia. *Dtsch Zeitschr Chir* 1937; 249: 311-6.
- Mansour KA, Burton HG, Miller JI, et al. Complications of intrathoracic Nissen fundoplication. *Ann Thorac Surg* 1981; 32: 173-8.
- Polk HC Jr, Zeppa R. Fundoplication for complicated hiatal hernia. *Ann Thorac Surg* 1969; 7: 202-10.
- Donahue PE, Bombeck CT. The modified Nissen fundoplication: reflux prevention without gas-bloat. *Chir Gastroenterol* 1977; 11: 15-22.
- DeMeester TR, Attwood SEA. Gastroesophageal reflux disease, hiatus hernia, achalasia of the esophagus and spontaneous rupture. *Maingot's Operations*. Volume I, 9th edition. Schwartz SI, Ellis H, Eds. Norwalk, Connecticut, USA: Appleton & Lange, 1989; section v: 513-45.
- Lind JF, Burns CM, MacDougal JT. Physiological repair hiatus hernia - manometric study. *Arch Surg* 1965; 91: 233-6.
- Toupet A. Technique d'oesophago-gastroplastie avec phrénogastropexie appliquée dans la cure radicale des hernies hiatales et comme complément de l'opération d'Heller dans les cardiospasmes. *Mem Acad Chir* 1963; 89: 394-409.

41. Watson A, Jenkinson LR, Ball CS, Barlow AP, Norris TL. A more physiological alternative to total fundoplication for the surgical correction of resistant gastro-oesophageal reflux. *Br J Surg* 1991; 78: 1088-94.
42. Spencer J. Use of prolonged pH recording in gastro-oesophageal reflux. *Br J Surg* 1968; 55: 864-8.
43. Baue AE, Belsey RH. The treatment of sliding hiatus hernia and reflux esophagitis by the Mark IV technique. *Surgery* 1967; 62: 396-404.
44. DeMeester DR, Johnson LF. The evaluation of objective measurements of gastroesophageal reflux and their contribution to patient management. *Ann Surg* 1976; 56: 39-53.
45. Kramer SJM, Aye RW, Hill LD. The Hill Repair: A Definitive Anti-reflux Procedure. In: *Surgery of the Esophagus, Stomach and Small Intestine*, 5th edition. Wastell C, Nyhus LM, Donahue PE, Eds. Boston: Little, Brown and Company, 1995; chapter 17: 215-8.
46. Belsey RHR. Personal communication.
47. Angelchik JP, Cohen R. A new surgical procedure for the treatment for gastro-esophageal reflux and hiatal hernia. *Surg Gynec Obstet* 1979; 148: 246-8.
48. Durrans D, Armstrong CP, Taylor TV. The Angelchik anti-reflux prosthesis - some reservations. *Br J Surg* 1985; 72: 525-7.
49. Quincke H. Ulcus oesophagei ex digestionem. *Dtsch Arch Klin Med* 1879; 24: 72-80.
50. Winkelstein A. Peptic oesophagus: a new clinical entity. *JAMA* 1935; 104: 906-9.
51. Tuttle SG, Grossman MI. Detection of gastro-esophageal reflux by simultaneous measurement of intraluminal pressure and pH. *Am J Physiol* 1958; 33: 225-7.
52. Royston CMS, Dowling BL, Spencer J. Antrectomy with Roux-en-Y anastomosis in the treatment of peptic oesophagitis with stricture. *Br J Surg* 1975; 62: 605-7.
53. Washer GF, Gear MWL, Dowling BL, Gillison EW, Royston CMS, Spencer J. Randomised prospective trial of Roux-en-Y duodenal diversion versus fundoplication for severe reflux oesophagitis. *Br J Surg* 1984; 71: 181-4.
54. Herrington JL, Sawyers JL. Rebound acid secretion after duodenal diversion. In: *Surgery of the Esophagus, Stomach, and Small Intestine*, 5th edition. Wastell C, Nyhus LM, Donahue PE, Eds. Boston: Little, Brown and Company, 1995; chapter 43: 542-4.
55. Dallemagne B, Weerts JM, Jahaes C, Markiewicz S, Lombard R. Laparoscopic Nissen fundoplication: preliminary report. *Surg Laparosc Endosc* 1991; 1: 138-43.
56. Geagea T. Laparoscopic Nissen fundoplication: preliminary report of ten cases. *Surg Endosc* 1991; 5: 170-3.
57. Holmes T. On operative dilatation of the orifices of the stomach. *Br Med J* 1885; February 21: 372-3.
58. Abbe R. Relief of oesophageal stricture by a string saw. *Ann Surg* 1893; 17: 489-90.
59. Yamamoto H, Hughes RW Jr, Schroeder KW, Viggiano TR, DiMagno EP. Treatment of benign esophageal stricture by Eder-Puestow or balloon dilators: a comparison between randomized and prospective nonrandomized trials. *Mayo Clin Proc* 1992; 67: (3) 228-36.
60. Beck C, Carrel A. Demonstrations of specimens illustrating a method of formation of a pre-thoracic esophagus. *Ill Med J* 1905; 7: 461.
61. Jiannu A. Gastrostomie und Ösophagoplastik. *Dtsch Z Chir* 1912; 118: 383-90.
62. Gavriliiu D. Aspects of esophageal surgery. *Curr Prob Surg* 1975; 12 (10): 1-64.
63. Collis JL. Gastroplasty. *Thorax* 1961; 16: 197-99.
64. Henderson RD. Reflux control following gastroplasty. *Ann Thorac Surg* 1977; 24: 206-12.
65. Orringer MB. Combined Collis gastroplasty-Nissen fundoplication operation for reflux oesophagitis. *Surgical Rounds* 1978; 1: 10-9.
66. Kirschner M. Ein neues Verfahren der Oesophagoplastik. 44th congress of the German Surgical Society, April 9th, 1920: 606-63.
67. Roux C. L'Oesophago-jéjuno-gastrotomie, nouvelle opération pour rétrécissement infranchissable de l'oesophage. *Semaine Méd (Paris)* 1907; 27: 37-40.
68. Kelling G. Oesophagoplastik mit Hilfe des Quercolon. *Zentralbl Chir* 1911; 38: 1209-12.
69. Vulliet TH. De l'oesophagoplastie et de ses diverse modifications. *Sem Med* 1911; 31: 529-30.
70. Roith O. Die einzeitige antethorakale Oesophagoplastik aus dem Dickdarm. *Zentralbl Chir* 1923-1924; 183: 419-23.
71. Belsey RHR. Reconstruction of the oesophagus with the left colon. *J Thorasc Cardiovasc Surg* 1965; 49: 33-55.
72. Kittle CK. The History of Esophageal Surgery. In: *Surgery of the Esophagus, Stomach, and Small Intestine*, 5th edition. Wastell C, Nyhus LM, Donahue PE, Eds. Boston: Little, Brown and Company, 1995: 35.
73. Mikulicz von JV. Small contributions to surgery of the alimentary tract. (1) Cardiospasm and its treatment. (2) Peptic ulcer of the jejunum. (3) Operative treatment of severe forms of invagination of the intestine. (4) Operations on malignant growths of the large intestine. *Boston Med Surg J* 1903; 148: 608-11.
74. Einhorn M. A case of dysphagia with dilatation of the oesophagus. *Med Rec* 1888; 34: 751-3.
75. Meltzer SG. Ein Fall von Dysphagie nebst Bemerkungen. *Berl Klin Wochenschr* 1888; 25: 140-2.
76. Hertz AF. Achalasia of the Cardia. *Q J Med* 1915; 8: 300-8.
77. Mikulicz von JV. Zur Pathologie und Therapie des Cardiospasmus. *Dtsch Med Wochenschr* 1904; 30: 17 and 50.
78. Zaaijer JH. An address on the surgery of the oesophagus and lungs. *Lancet* 1929; 1: 909-14.
79. Heyrovsky H. Casuistik und Therapie der idiopathischen Dilatation der Speiseröhre. Oesophagofastroanastomose. *Arch Klin Chir* 1913; 100: 703-5.
80. Wendel W. Zur Chirurgie des Oesophagus. *Archiv Klin Chir* 1910; 93: 311.
81. Heller E. Extra-muköse Cardiaplastik beim chronischen Cardiospasmus mit Dilatation des Oesophagus. *Mitt Grenzgeb Med Chir* 1914; 27: 141-9.
82. Gottstein G. Die operative Behandlung des Cardiospasmus. *Zentralbl Chir* 1904; 31: 1362-4.
83. Steichen FM, Heller E, Ravitch MM. Achalasia of the esophagus. *Surgery* 1960; 47: 846-76.
84. Barrett NR, Franklin RH. Concerning the unfavourable late results of certain operations performed in the treatment of Cardiospasm. *Br J Surg* 1949; 37: 194-202.

85. Ellis FH, Kiser JC, *et al.* Esophagomyotomy for esophageal achalasia: experimental, clinical, and manometric aspects. *Ann Surg* 1967; 166: 640-56.
86. Pinotti HW. First development of cardiomyotomy by video-laparoscopy: a new perspective in the achalasia treatment. *ISDE News* 1991; 10: 8.
87. Czerny V. Neue Operation. *Zentralbl Chir* 1877; 4: 433-4.
88. Billroth T. Total Extirpation des Ganzenoesophagus vom Pharynx bis Sternum; ein total Extirpation de Ganzenlarynx mit des GanzenSchildruse. *Vehr Deutch Ges Chir* 1879; 8: 7-9.
89. Mikulicz-Radecki J von. Über eine eigenartige symmetrische Erkrankung der Thränen - und Mundspeicheldrüsen, in Beiträge zur Chirurgie. *Festschr fur T Billroth*. Stuttgart, 1892: 610-30.
90. Mikulicz-Radecki J von. Ein Fall von Resection des carcinomatösen Oesophagus mit plastischem Ersatz des excidirten Stückes. *Prag Med Wochenschr* 1886; 11: 93-4.
91. Trotter W. (Reported by Pilcher R.) Carcinoma of the cervical oesophagus. *Lancet* 1937; 1: 73-6.
92. Ach V. Beitrage zur Oesophaguschirurgie. *Munch Med Wochenschr* 1913; 60: 1115-17.
93. Garlock JH. The surgical treatment of the thoracic esophagus. *Surg Gynec Obstet* 1938; 66: 534-8.
94. Meyer W. Resection of cardia for carcinoma. *Ann Surg* 1915; 62: 693-709.
95. Ochsner A, De Bakey M. Surgical aspects of carcinoma of the esophagus. *J Thorac Surg* 1941; 10: 401-55.
96. Rovsing T. The technique of my method of ante-thoracic oesophagoplasty. *Surg Gynecol Obstet* 1926; 43: 781-4.
97. Turner GG. Excision of the thoracic oesophagus for carcinoma with construction of an extra-thoracic gullet. *Lancet* 1933; 2: 1315-16.
98. Ohsawa T. The surgery of the oesophagus. *Jpn Chir* 1933; 10: 682-91.
99. Adams WE, Pheister DB. Carcinoma of the lower thoracic esophagus. *J Thorac Surg* 1938; 7: 621-32.
100. Sweet RH. Late results of surgical treatment of carcinoma of the esophagus. *JAMA* 1954; 155: 422-5.
101. Nakayama, K. Erfahrungen bei etwas 3000 Fallen von Esophagus and Kardiocarcinoma. *Langenbeck Arch Klin Chir* 1960; 295: 81-90.
102. Churchill ED, Sweet RH. Transthoracic resection of tumours of the stomach and esophagus. *Ann Surg* 1942; June: 897-917.
103. McKeown KC. The surgical treatment of carcinoma of the oesophagus. *Proc Roy Soc Med* 1974; 67: 5389-95.
104. Matthews HR, Steel A. Left-sided subtotal oesophagectomy for carcinoma. *Br J Surg* 1987; 87: 1115-17.
105. Wong J. Transhiatal oesophagectomy for carcinoma of the thoracic oesophagus. *Br J Surg* 1986; 73: 89-90.
106. Voelcker F. Ueber extirpation der Cardia wegen Carcinoms. *Verh Dtsch Ges Chir* 1908; 37: 126.
107. Barrett NR. Chronic peptic ulcer of the oesophagus and esophagitis. *Br J Surg* 1950; 38: 175-82.
108. Bremner CG, Lynch VP, Ellis FH. Barrett's esophagus: congenital or acquired? An experimental study of esophageal mucosal regeneration in the dog. *Surgery* 1970; 68(1): 209-16.
109. Van der Burgh A, Dees J, Hop WCJ, van Blankenstein M. Oesophageal cancer is an uncommon cause of death in patients with Barrett's oesophagus. *Gut* 1996; 39: 5-8.
110. Leroy, d'Etoilles De. *Lavacherie de L'Oesphagotomie*. Bibliothèque Nationale de Bruxelles, Bruxelles, 1845.
111. Guisez J. L'Intubation caoutchouée oesophagienne. *Presse Méd* 1914; 22: 85-8.
112. Atkinson M, Ferguson R. Fiberoptic endoscopic palliative intubation of inoperable oesophagogastric neoplasms. *Br Med J* 1977; 1: 266-7
113. Mackler SA, Mayer RM. Palliation of esophageal obstruction due to carcinoma with a permanent intra-luminal tube. *J Thorac Cardiovasc Surg* 1954; 28: 431.
114. Mousseau MM, Le Forrestier J, Barbin J, Hardy M. Place de intubation a demeure dans letraitement palliatif du cancer de l'oesophage. Society National Francais de Gastro-Enterology, Séance du 11 Mars 1956. *Arch Mal Appardia* 1956; 45: 208-14.
115. Stebbing GF. Sir Charters Symonds, KBE, MS, FRCS. *Guys Hospital Report* 1933; 83: 259-64.
116. Souttar HS. A method of intubating the oesophagus for malignant stricture. *Br Med J* 1924; 1: 782-3.
117. Celestin LR. Permanent intubation in inoperable cancer of the oesophagus and cardia. A new tube. *Ann Roy Coll Surg* 1959; 25: 165-70.
118. Knyrim K, Wagner HJ, Bethge N, Keymling M, Vakil NA. Controlled trial of an expansile metal stent for palliation of esophageal obstruction due to inoperable cancer. *New Engl J Med* 1993; 329: 1302-7.
119. Jethwa P, Lala A, Powell J, *et al.* A regional audit of iatrogenic perforation of tumours of the oesophagus and cardia. *Aliment Pharmacol Ther* 2005; 21: 479-84.

