

Seconda Lezione: Interpretare il dolore

14 / 03 / 2018



Sorrow, 1882
V. Van Gogh

Levis est dolor qui loquitur, magnus muta

Lieve è il dolore che parla...Il grande dolore è muto.



Lucio Anneo Seneca (Corduba 4 a.C. – Roma 65 d. C)

Pain

“An unpleasant sensory and emotional experience associated with actual or potential tissue damage or described in terms of such damage”

IAPS, APS, 2003

- Pain is always a subjective experience;
- Everyone learns the meaning of “pain” through experiences (usually injuries) in early life;
- Pain is a significant cause of stress

Various types of pain

Somatic pain: caused by the activation of pain receptors in the skin or deeper tissues (musculoskeletal tissues)

Visceral pain: caused by activation of pain receptors (e.g., infiltration, compression, stretching) of the thoracic, abdominal or pelvic viscera

Neuropathic pain: caused by injury to the nervous system (e.g., a tumor compressing nerves or the spinal cord, or cancer actually infiltrating into the nerves or spinal cord)

Acute vs. chronic pain

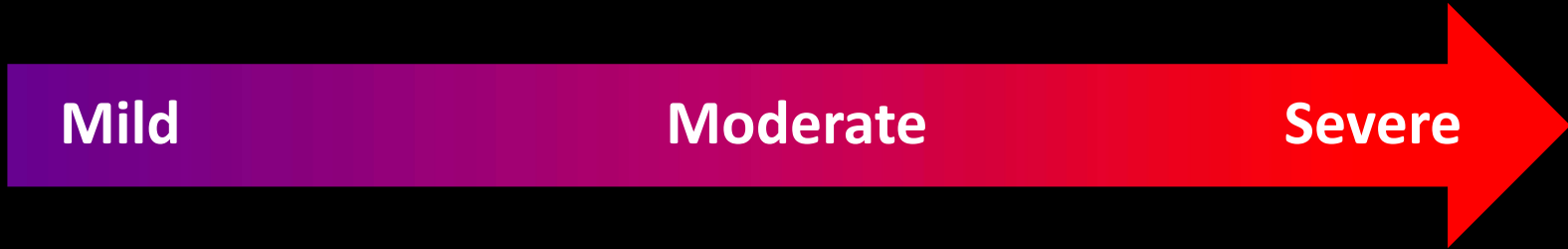Acute pain:

- short-lasting (up to 'several days')
- clinically associated with diaphoresis and tachycardia
- increasing in intensity over time, or it can occur intermittently (**episodic or intermittent pain**)
- usually related to a discreet event for onset: e.g., post-operative, post-trauma, etc...

Chronic pain:

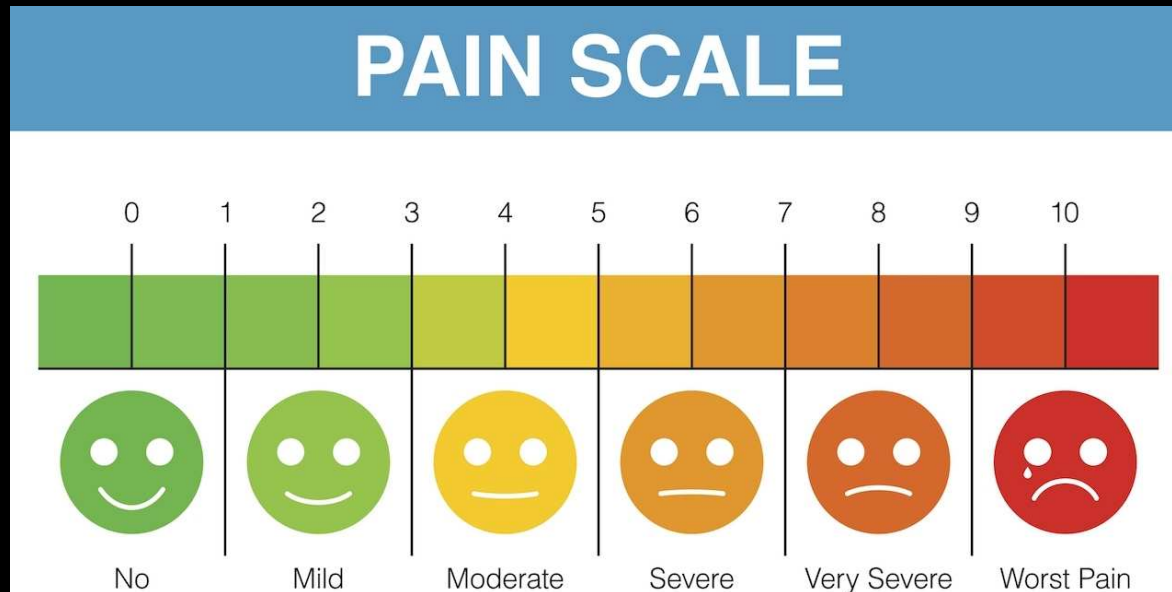
- long-term (> 3 months)
- more subjective (less characterized than acute pain)
- more commonly associated with psychological distress
- usually affects a patient's quality of life

Pain: How do we measure it ?



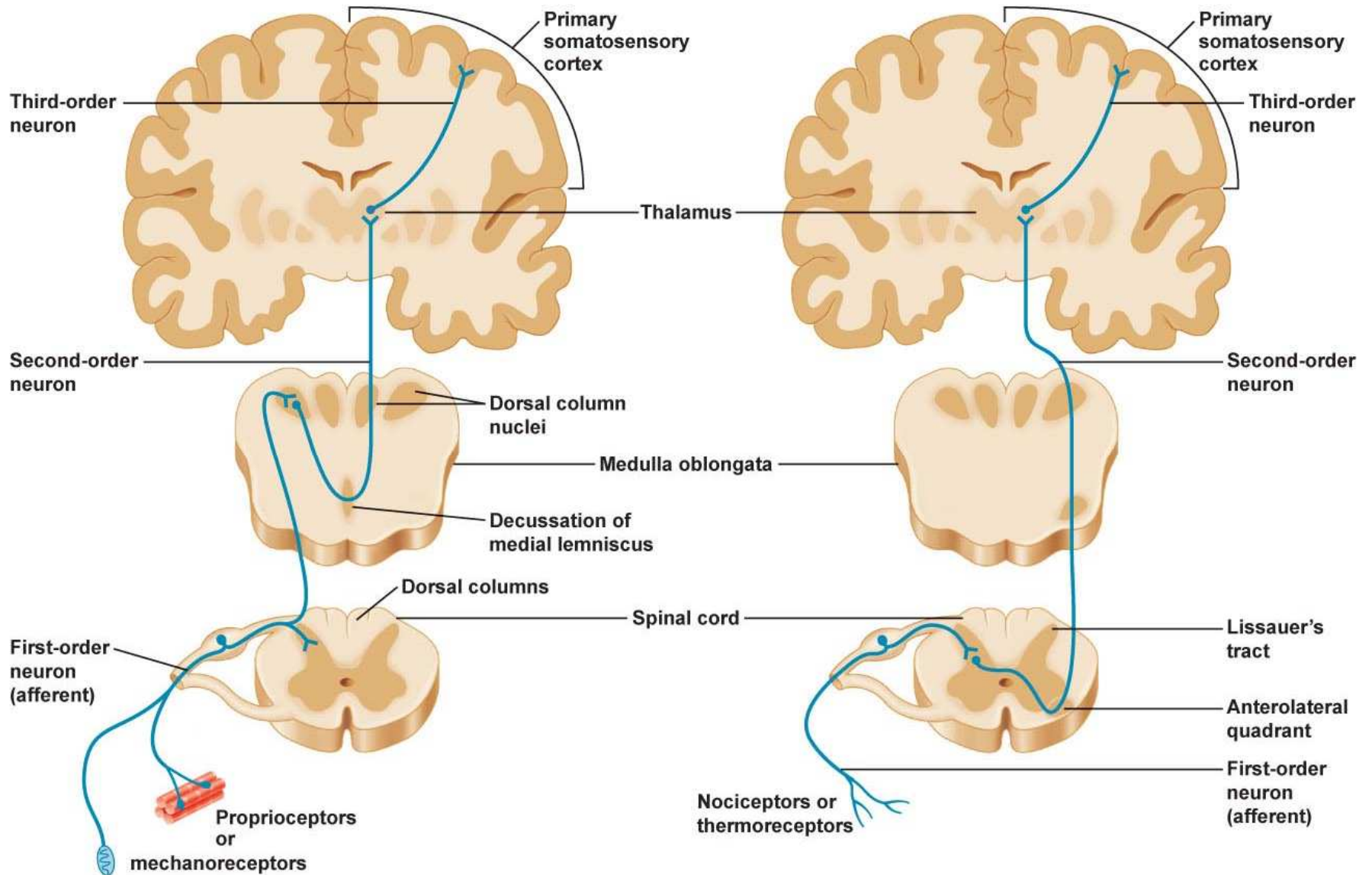
zero

max



General features

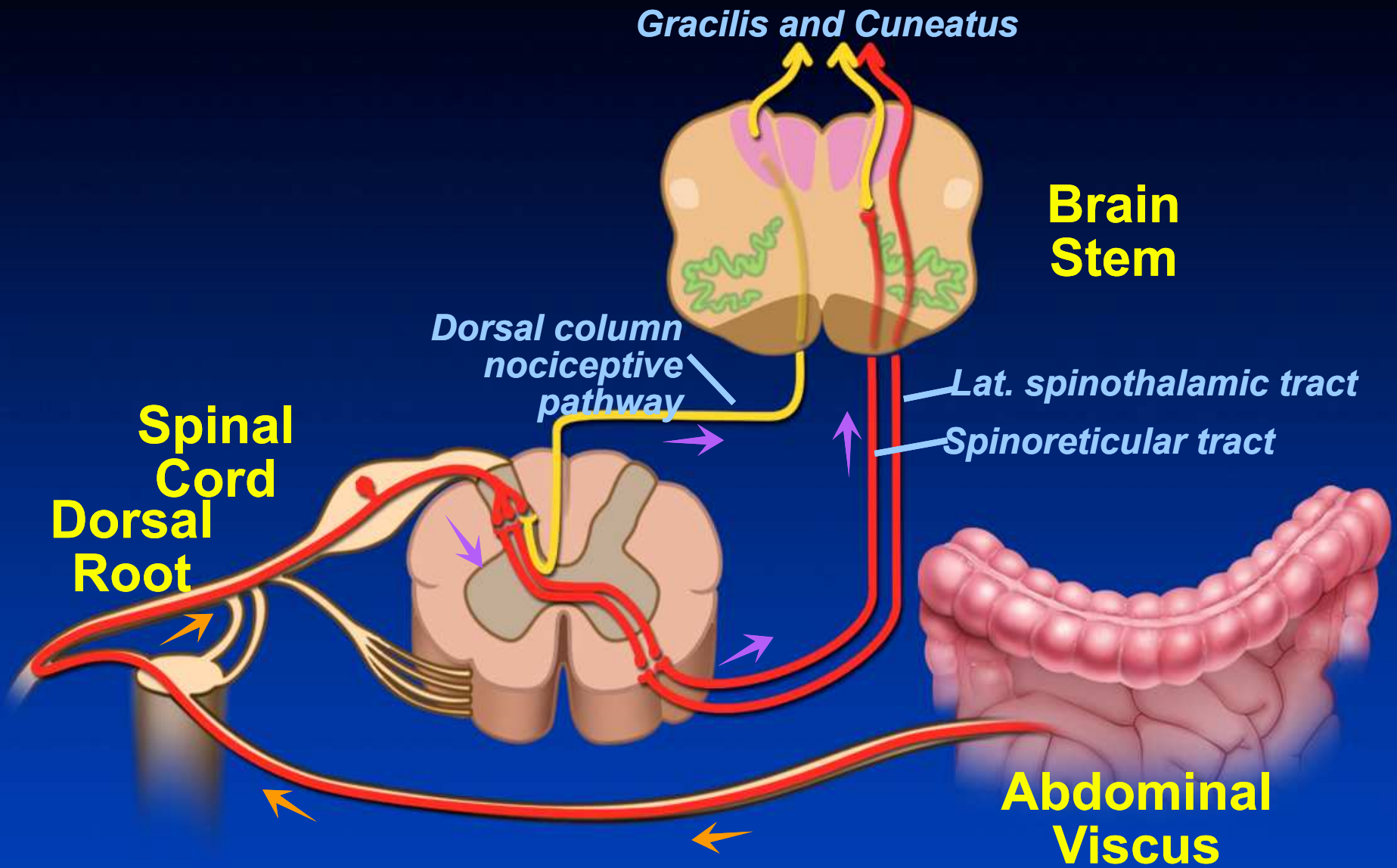
Pain pathways



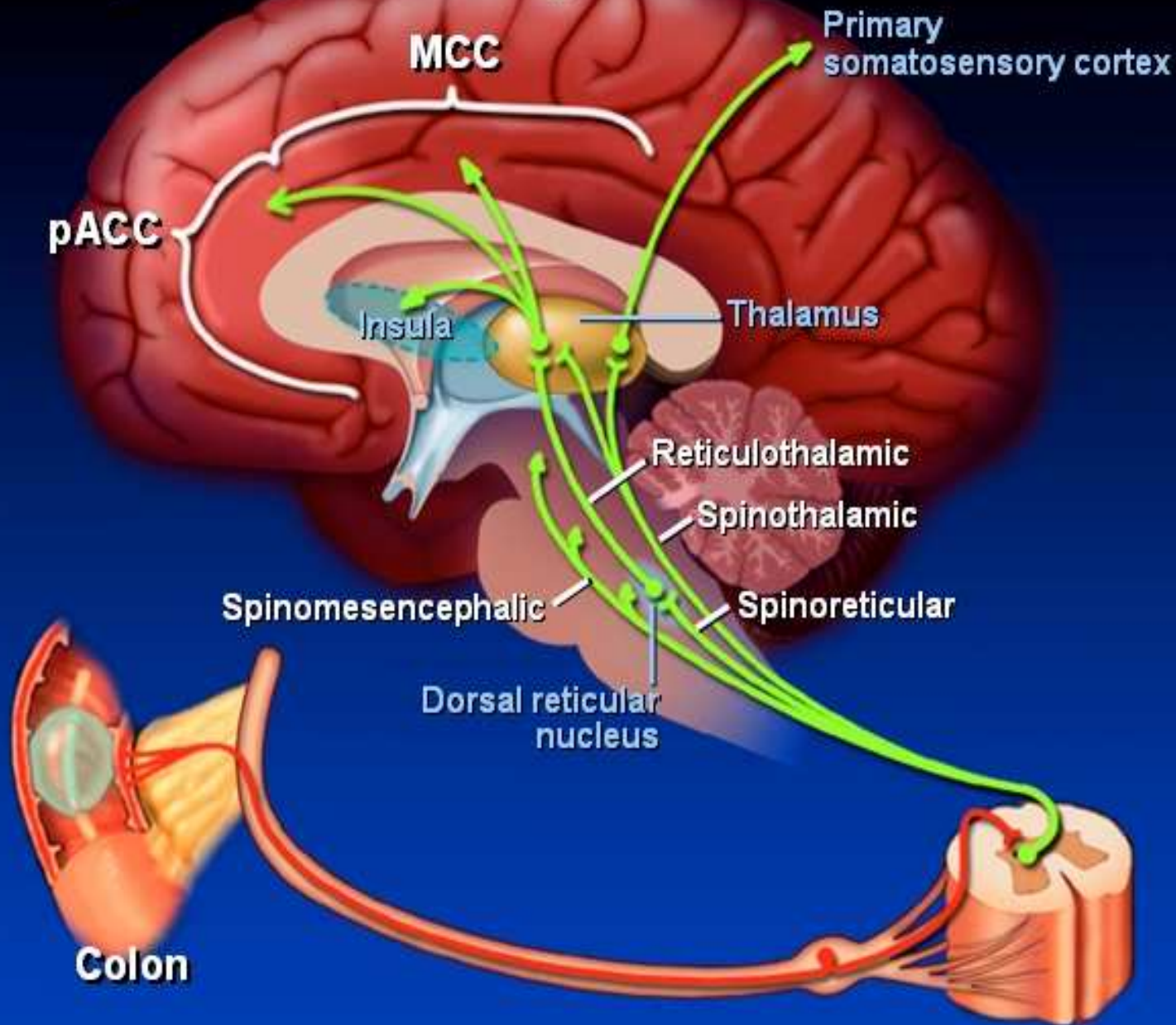
(a) Dorsal column–medial lemniscal pathway

(b) Spinothalamic tract

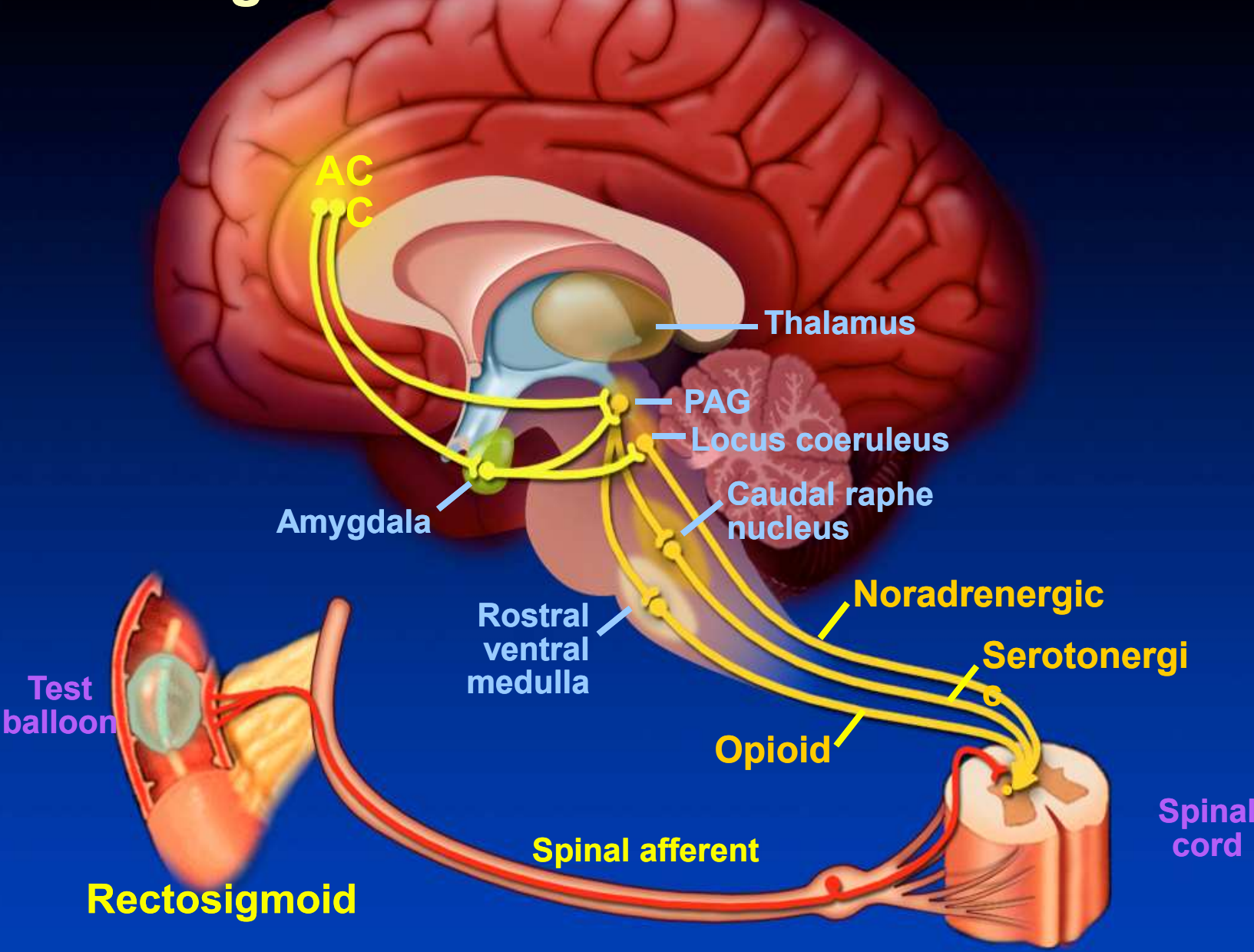
Processing of Sensory Signals in Spinal Cord, Brain Stem, and Brain



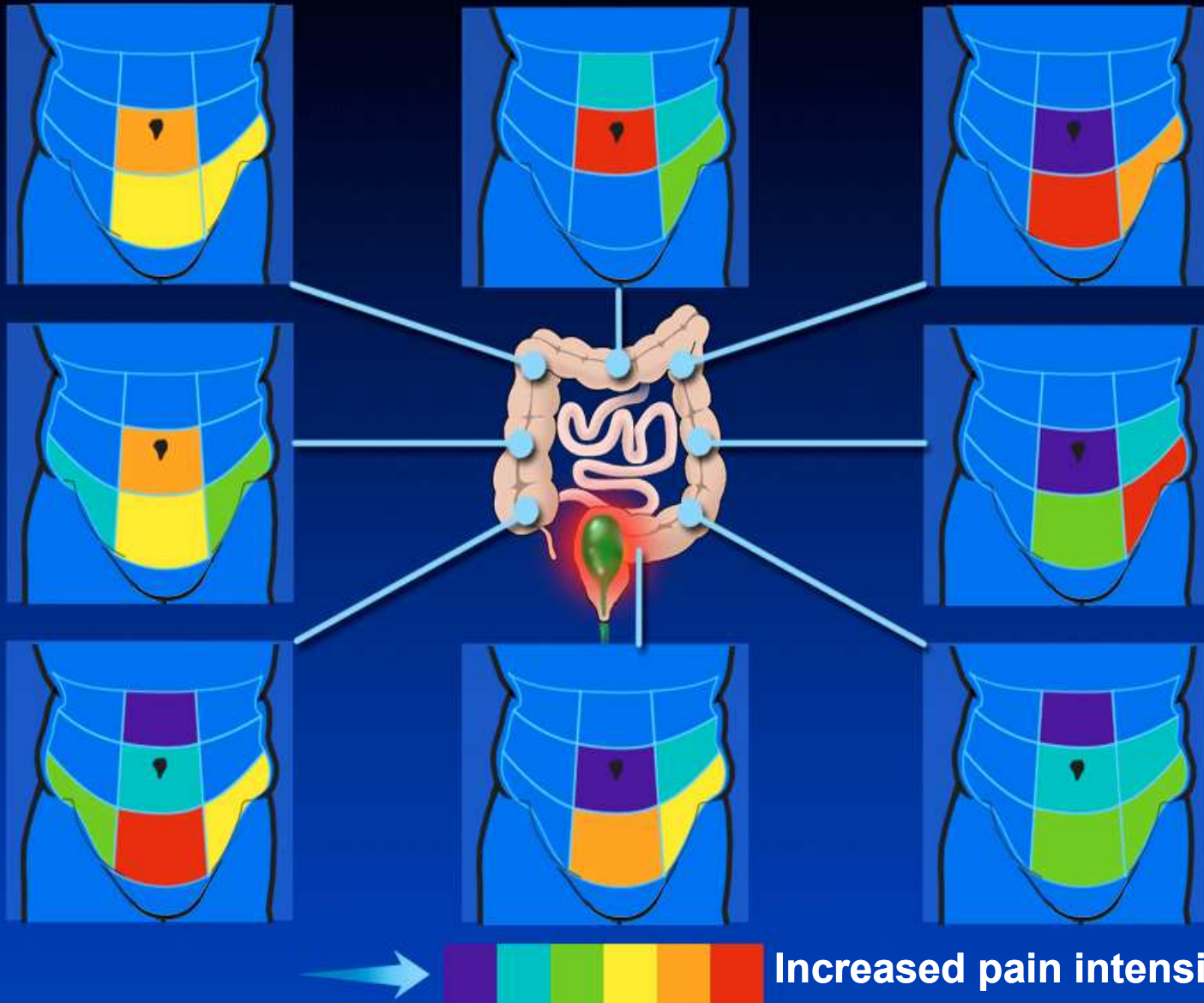
Ascending Visceral Pain Pathway



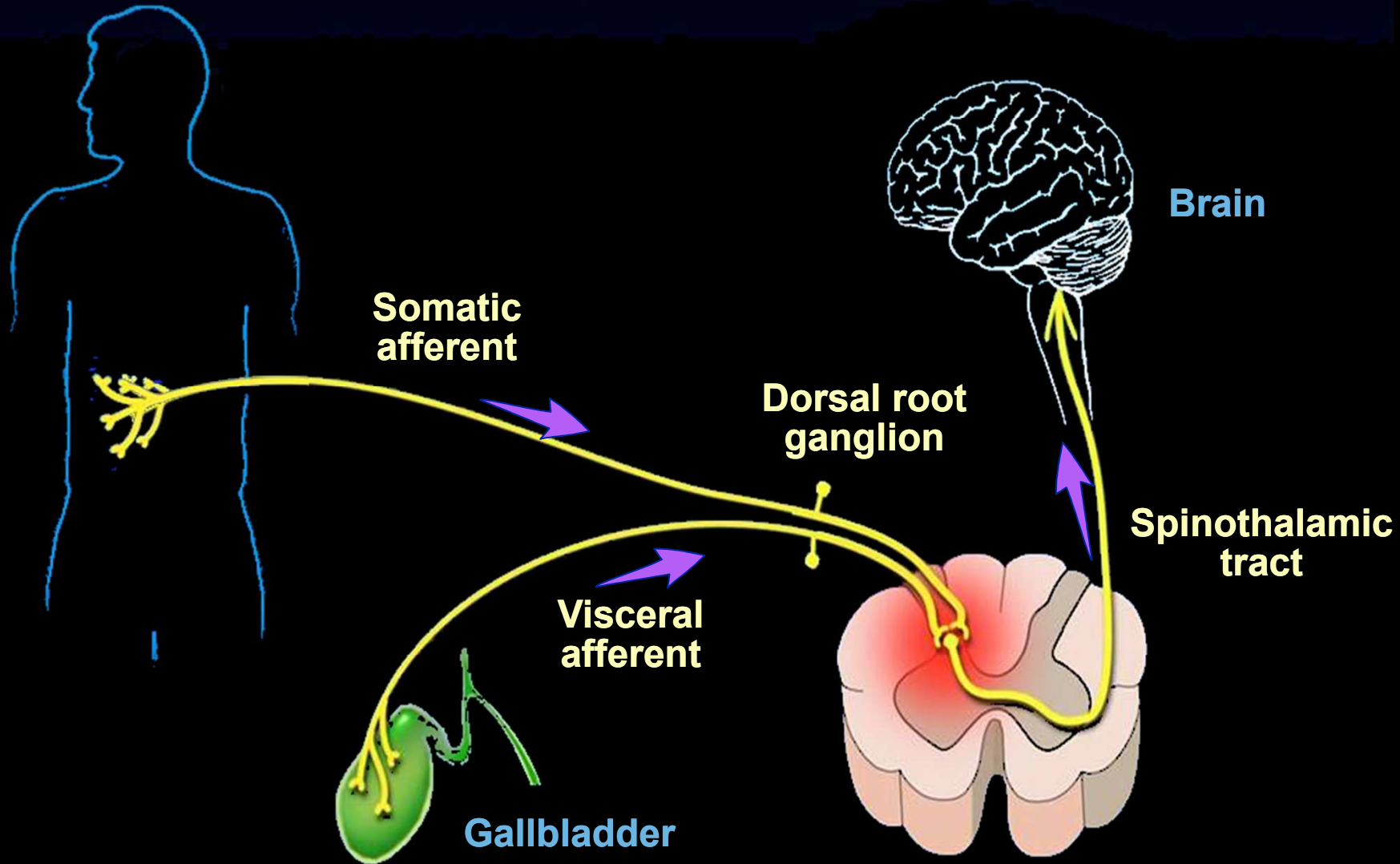
Descending Pain Modulation



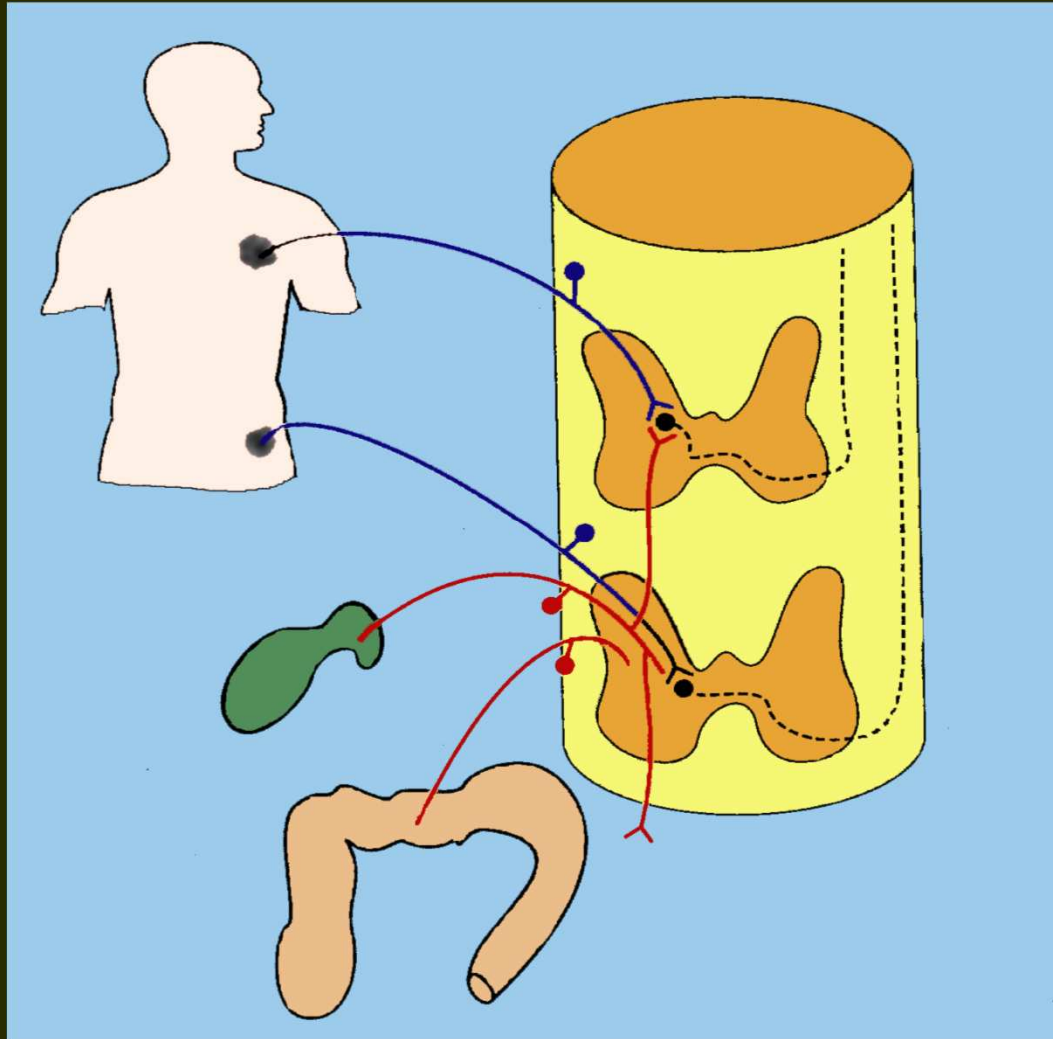
(Colonic) Referred Pain



Convergence of Somatic and Visceral Afferents in the Spinal Cord

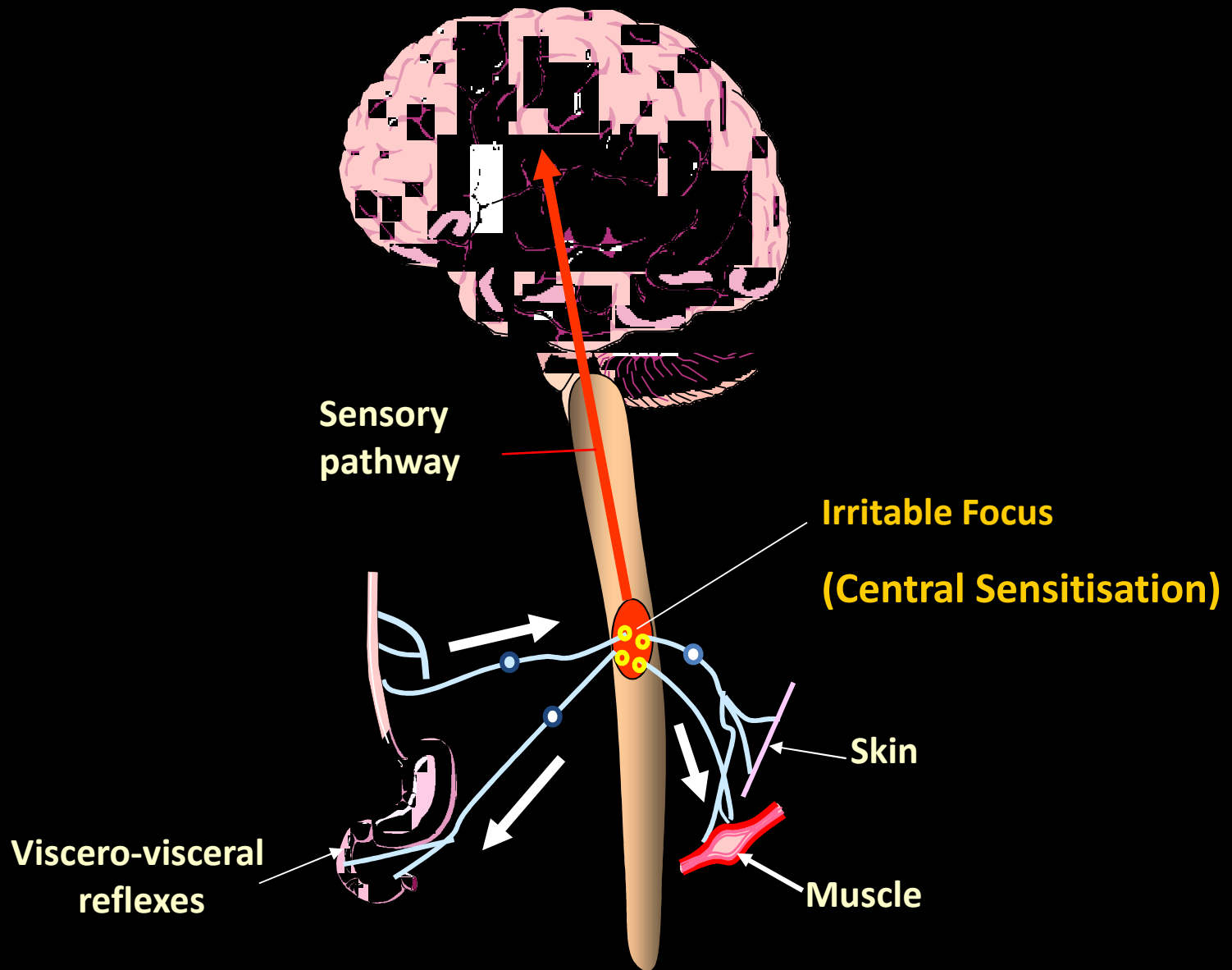


Divergence of Somatic and Visceral Afferents in the Spinal Cord



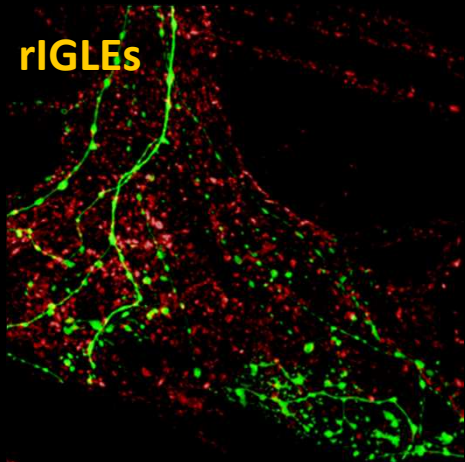
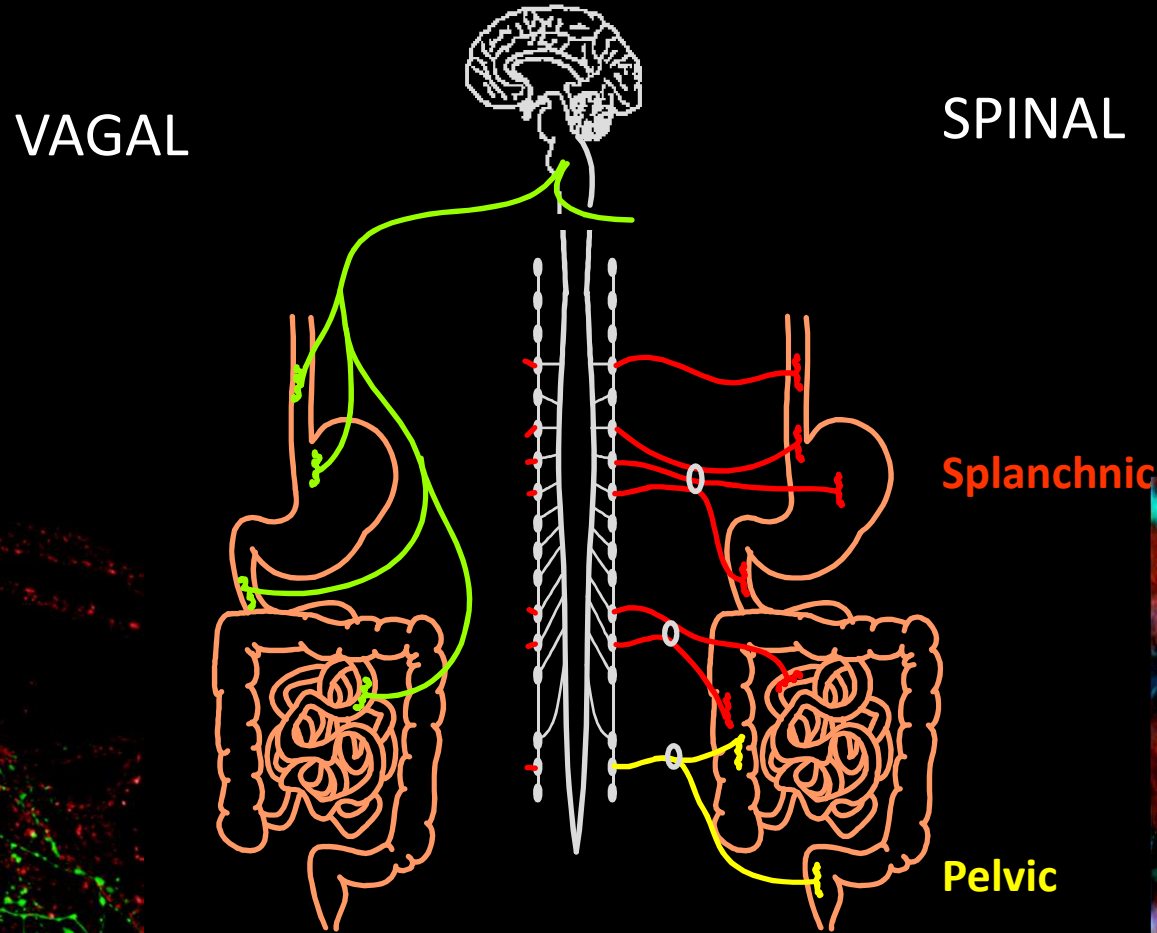
(Wolf et al. 1965)

Mackenzie's Interpretation of the mechanisms of visceral pain and related reflexes (1909)

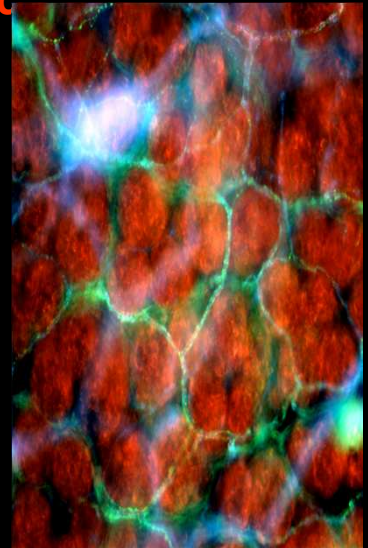


Mechanism(s) of visceral pain

Pathways of visceral sensations

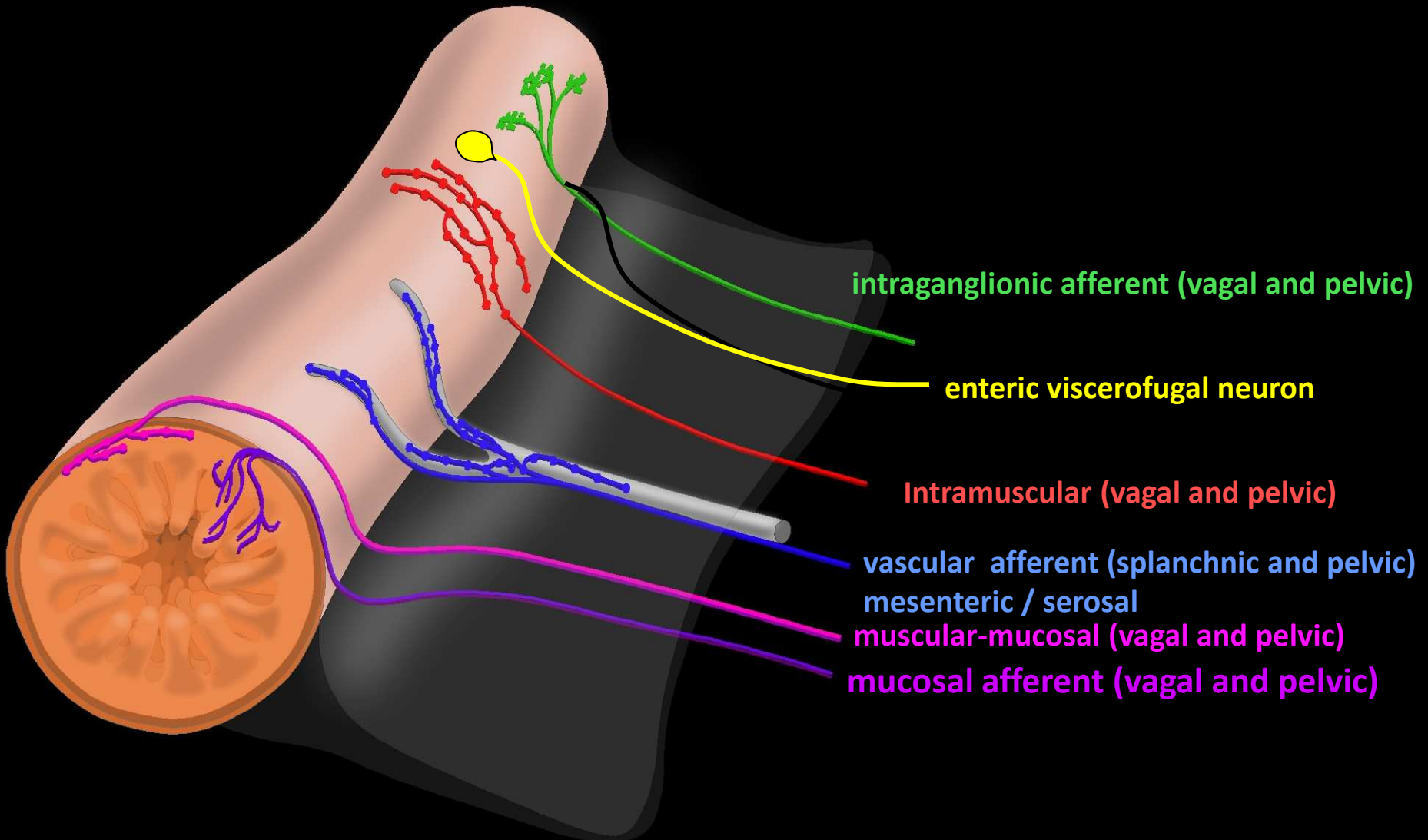


Low-threshold vagal mechanoreceptor



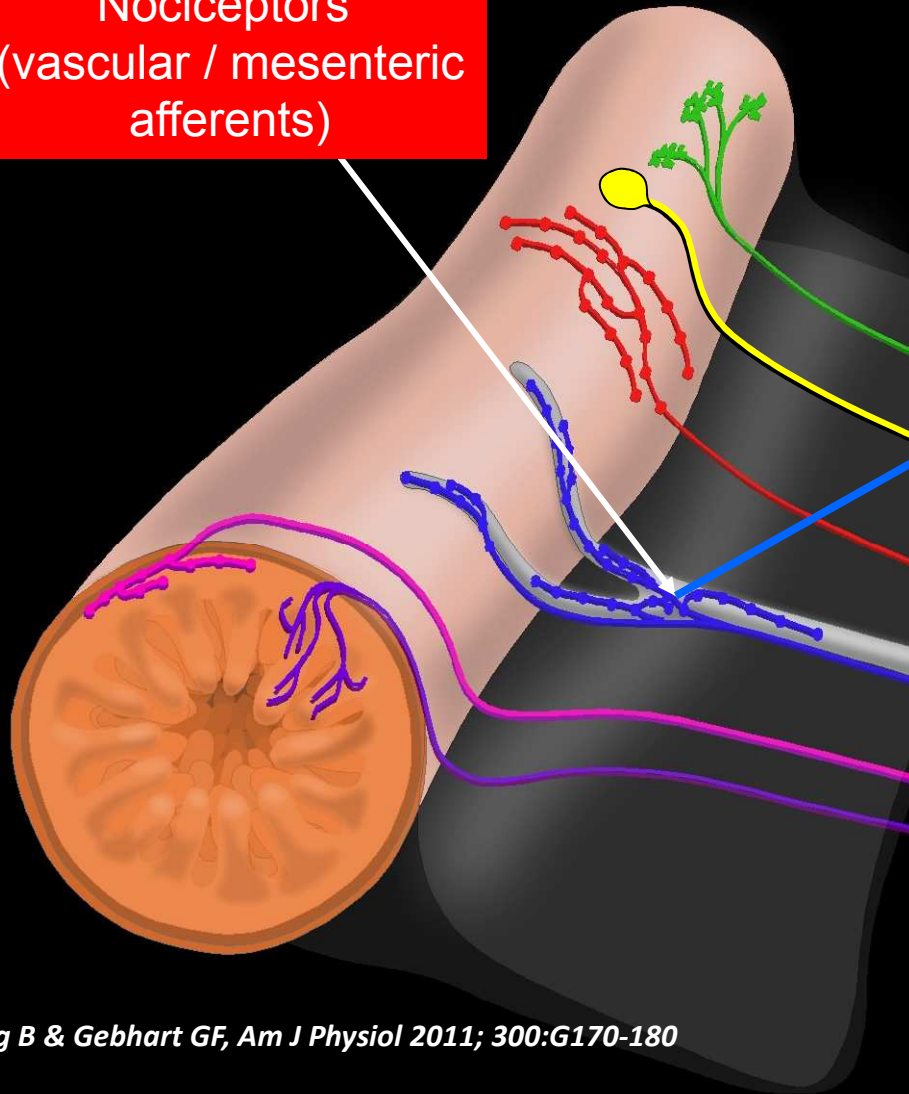
Muscular-mucosal afferent

Types of afferents in the gut

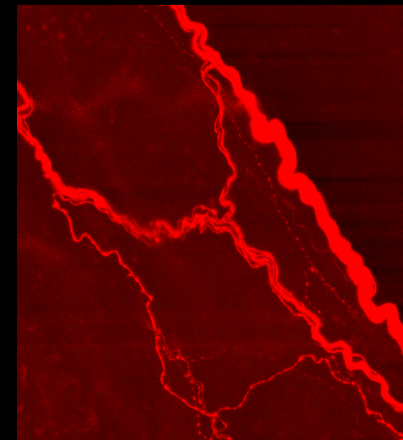


Vascular / mesenteric afferents act as nociceptors of the gut

Nociceptors
(vascular / mesenteric
afferents)



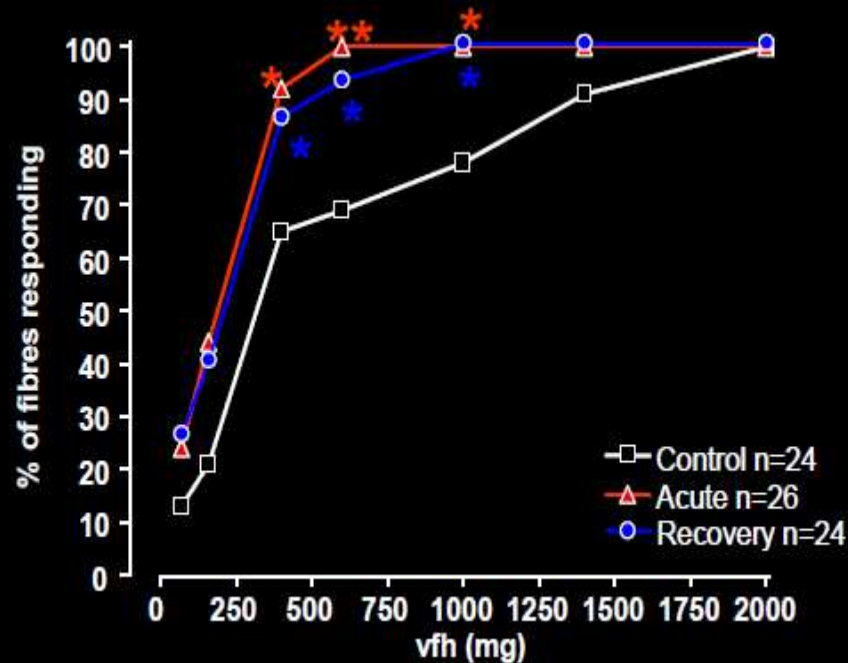
- Many are 'silent nociceptors'
- Modulated by inflammation
- Activation evokes vasodilation



Feng B & Gebhart GF, *Am J Physiol* 2011; 300:G170-180

Song X et al., *Gastroenterology* 2009; 137:274-284

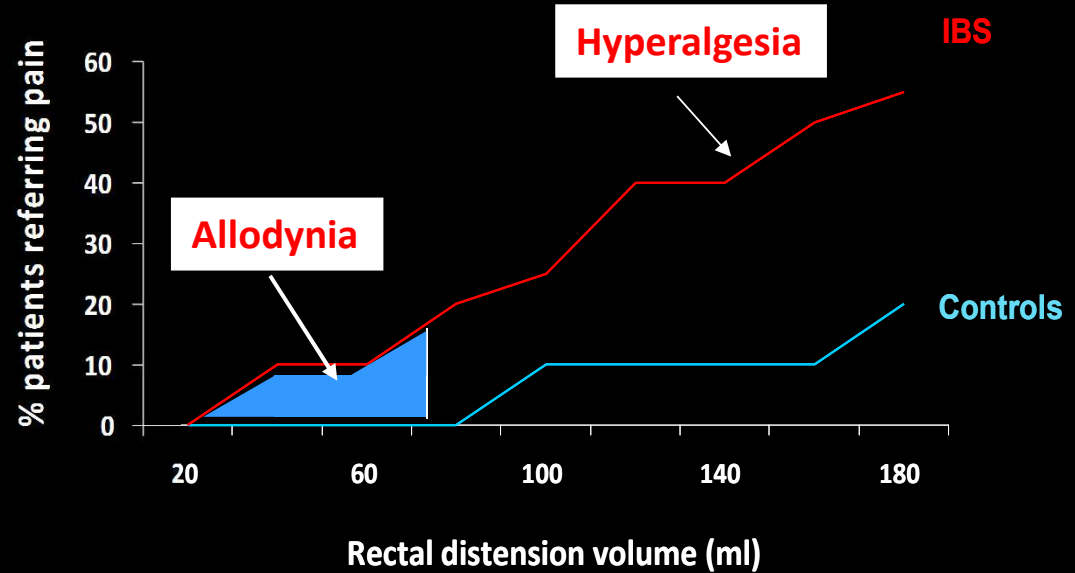
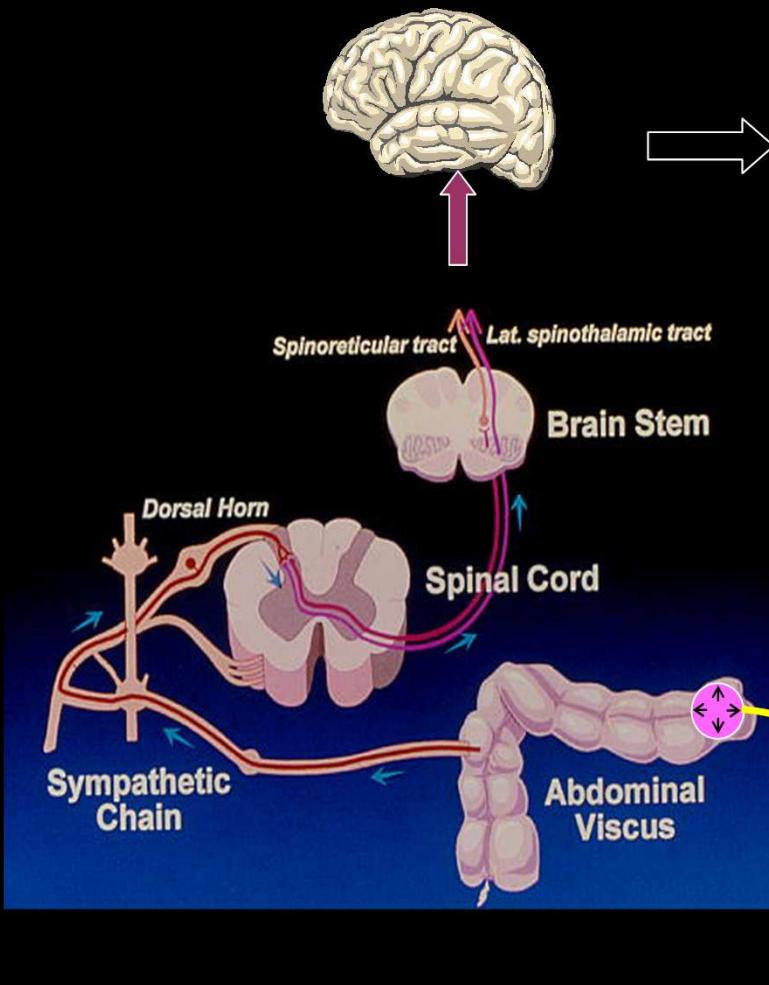
Visceral hypersensitivity evoked by serosal (splanchnic) afferents in a mouse model of colitis



- Low-threshold mechanosensory fibers → not involved
- High-threshold (nociceptors) → acute and chronic (recovery) hypersensitivity

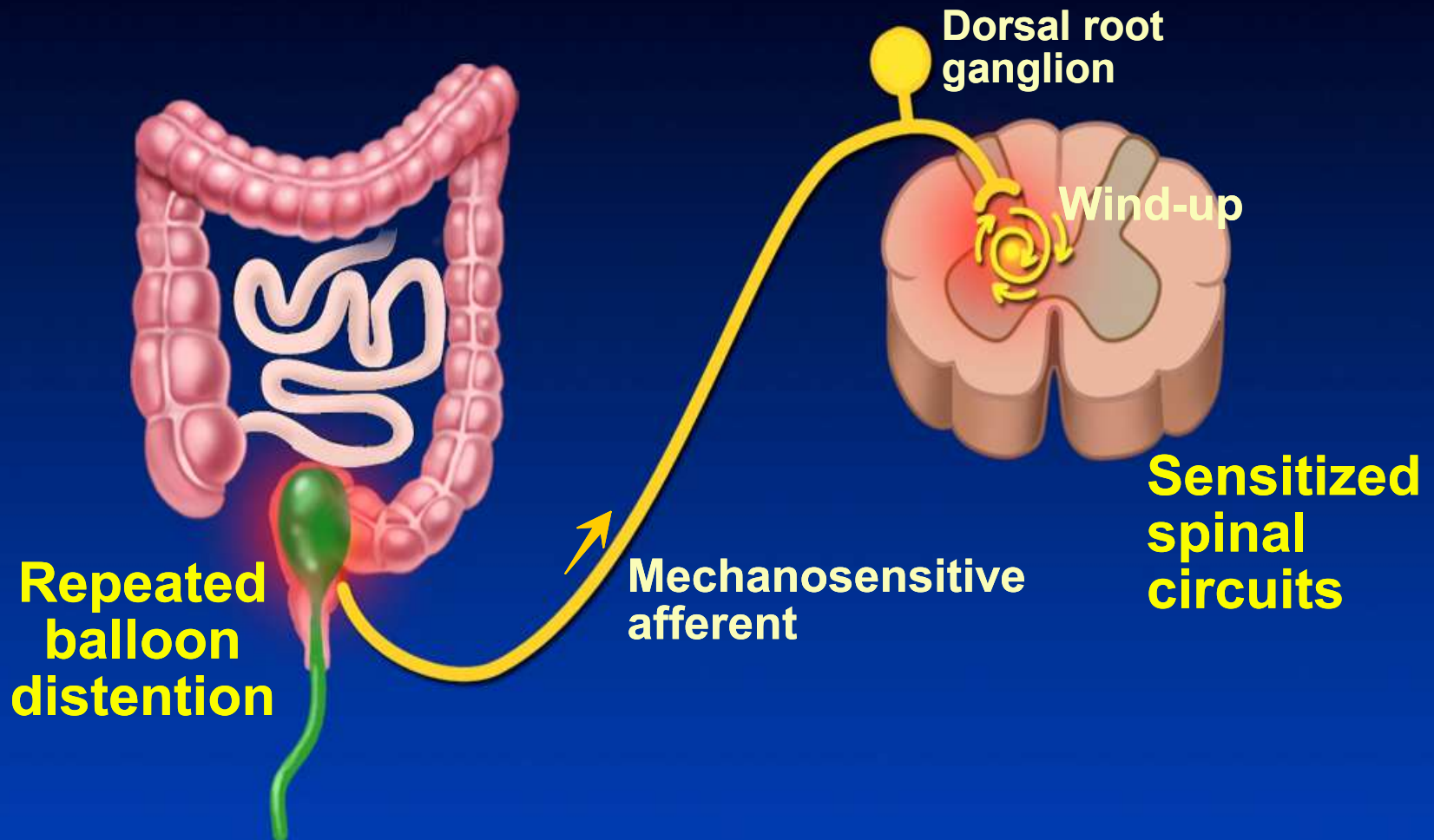
Hypersensitivity in the clinical setting

Visceral hypersensitivity in IBS

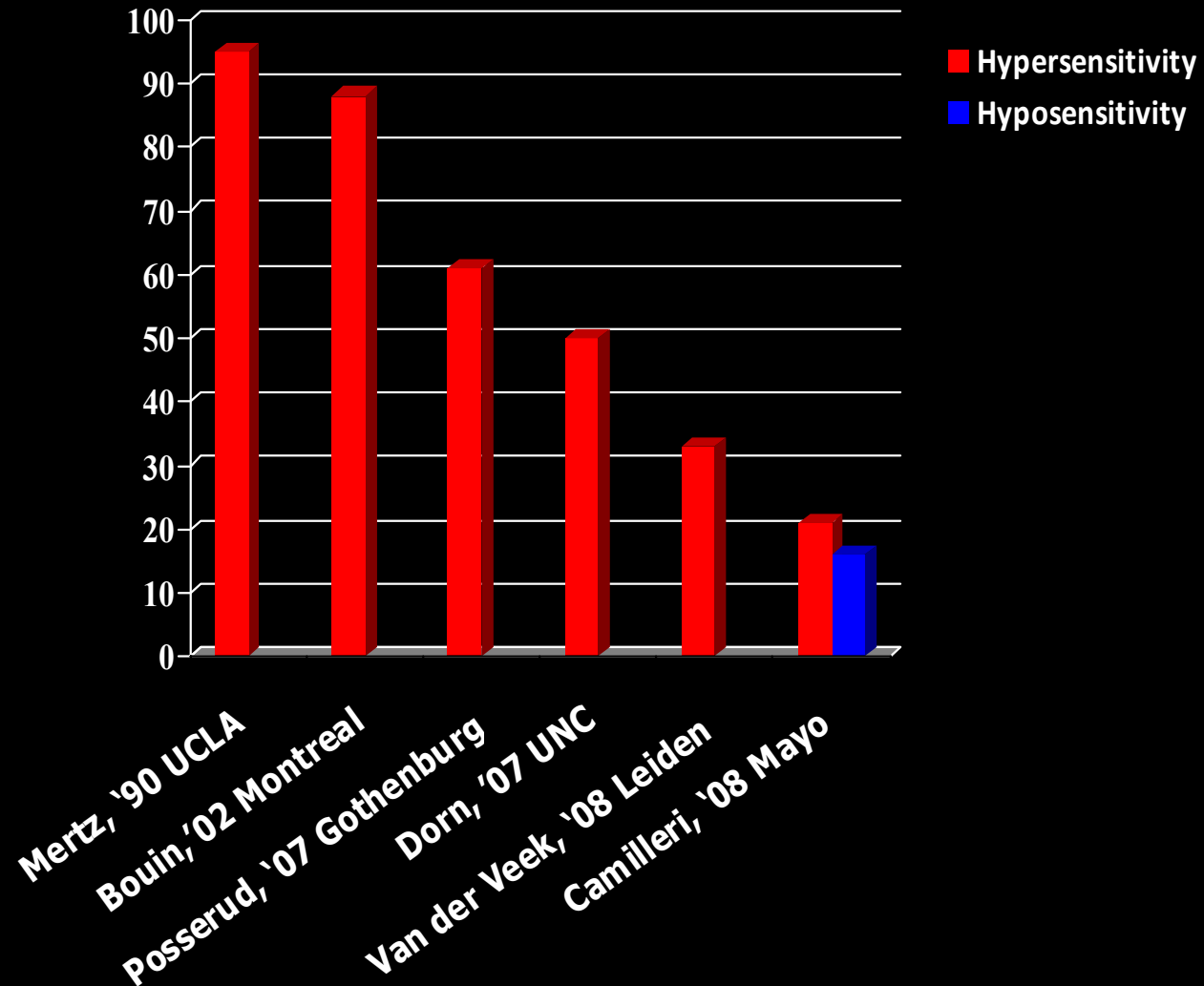


Whitehead W.E., et al., *Dig Dis Sci* 1980; 25(6):404-1

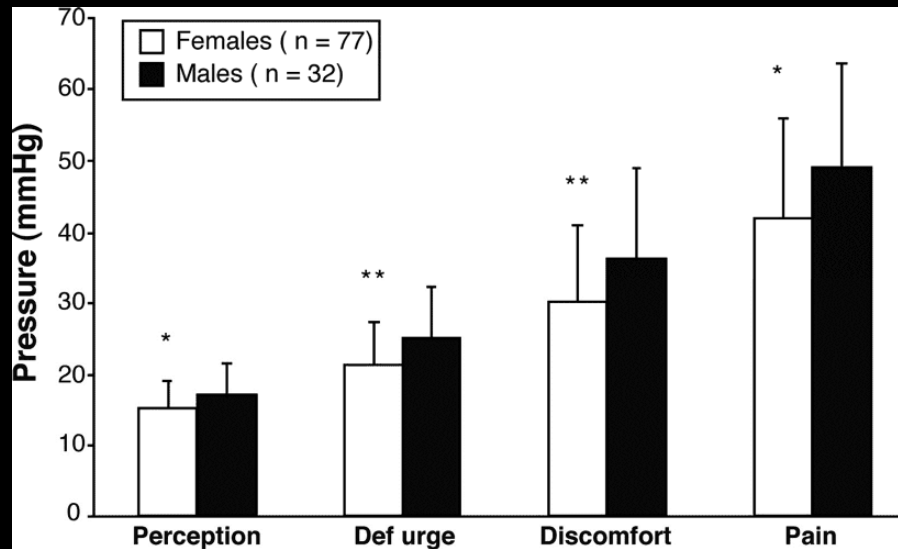
Repetitive Stimulation Sensitizes the Spinal Cord



Prevalence of rectal hypersensitivity in IBS

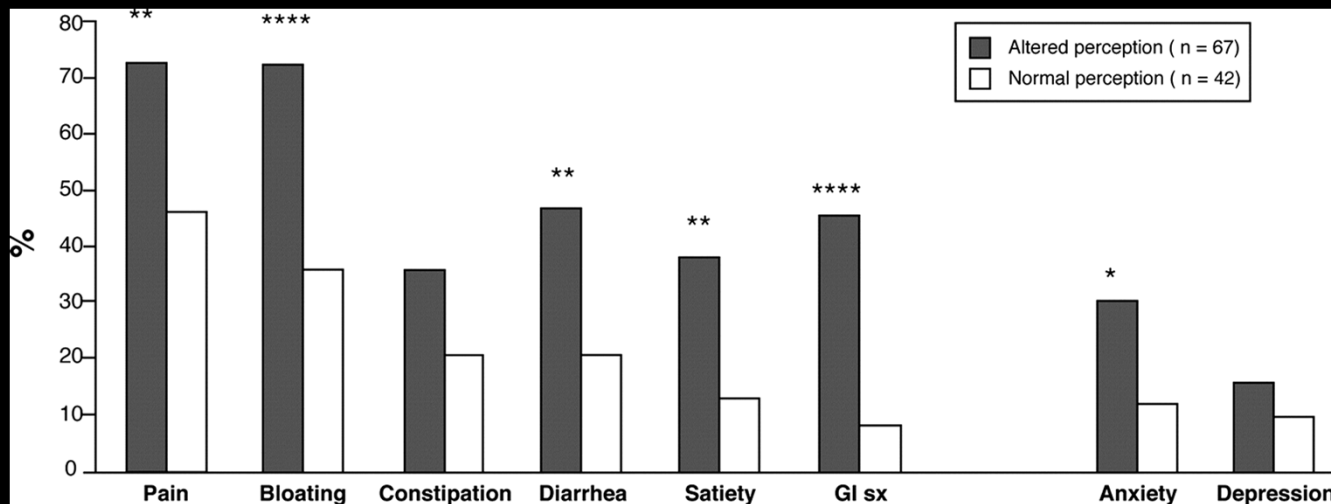


Female with IBS show more hypersensitivity than male pts



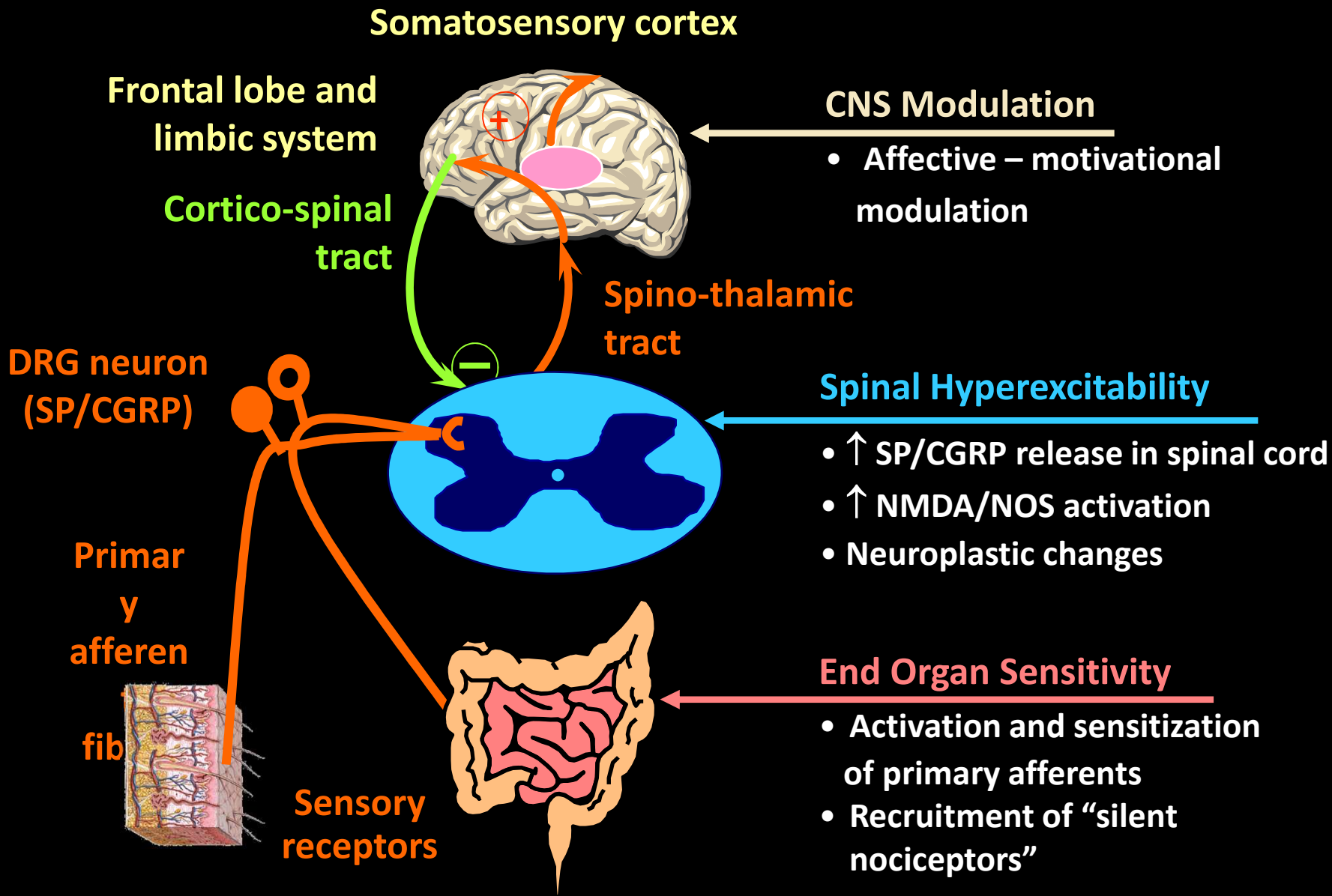
*Posserud I., et al., Gastroenterology
2007;133: 1113-23*

Altered perception is associated with symptom severity in IBS

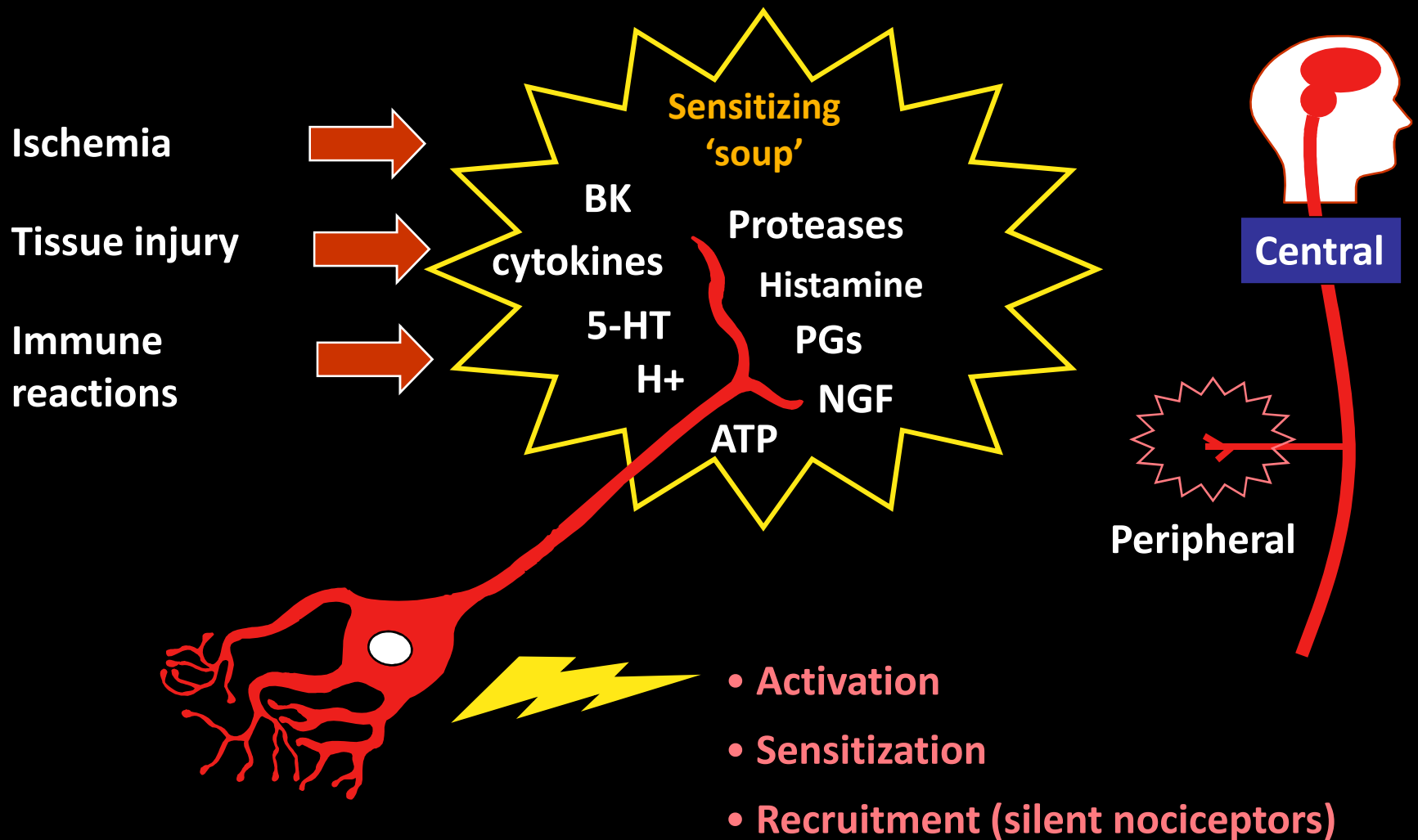


Mechanisms and sites of hypersensitivity

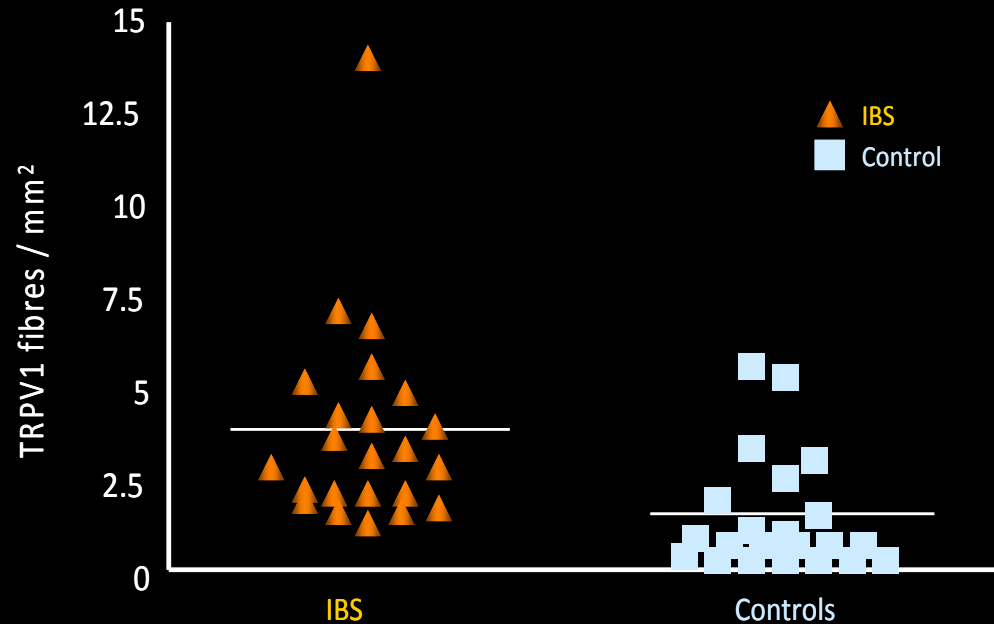
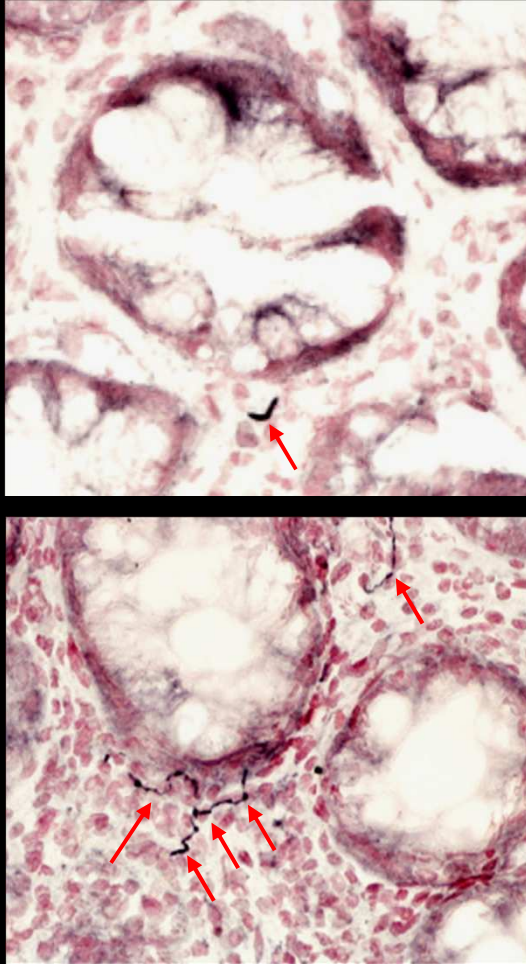
Mechanisms of visceral hypersensitivity



Mechansims of Altered Afferent Sensitivity

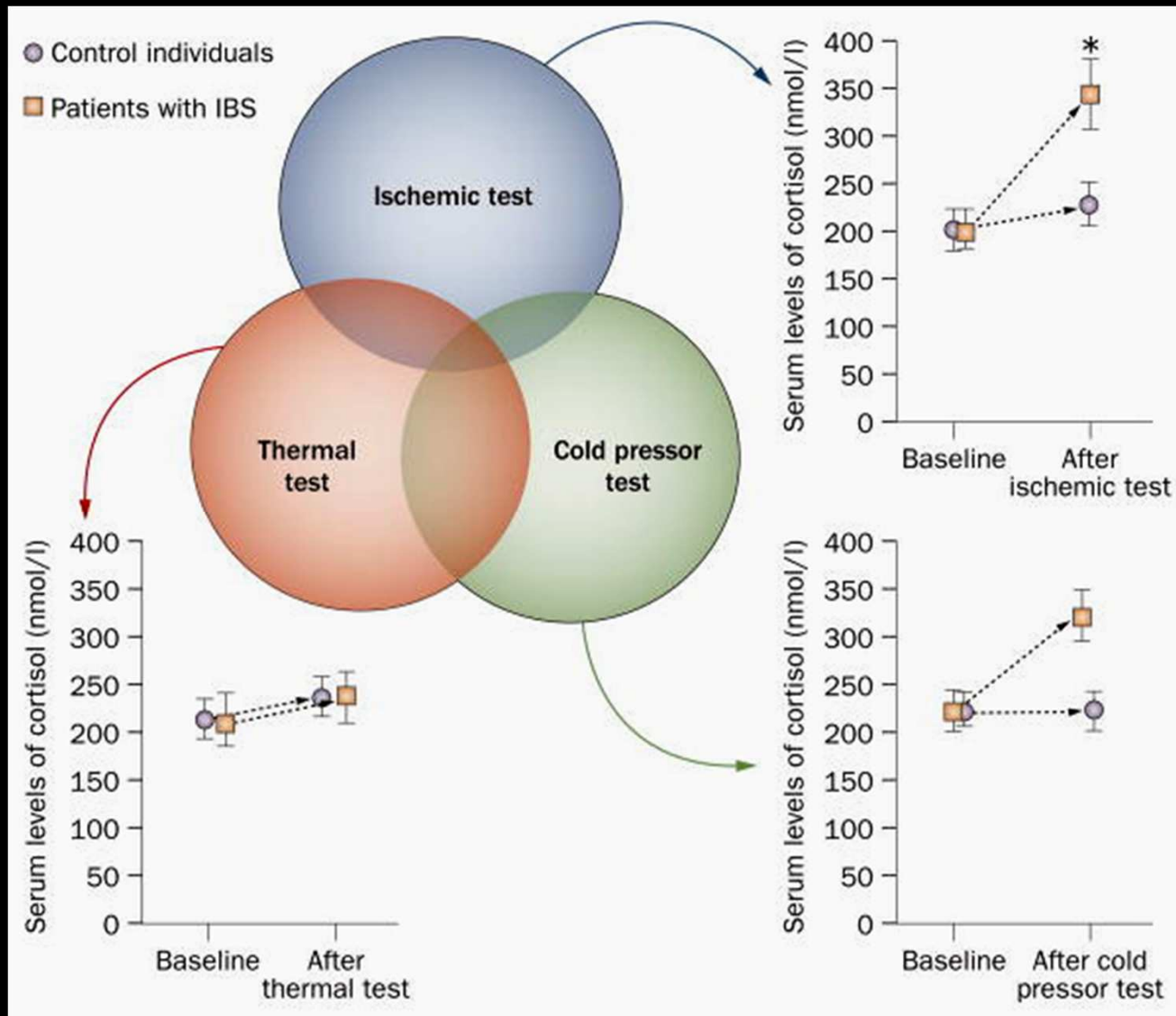


Increased TRPV1-immunoreactive sensory fibres in IBS



- 23 IBS pts; ~ 2/3 with non-D-IBS
- Low-grade inflammation
- Only TRPV1-IR nerves and MCs correlated with pain


Visceral and somatic hypersensitivity overlap in IBS pts



**IBS pts 2fold ↑
of somatic comorbidities
e.g. fibromyalgia, CFS, etc.**

Riedel A., et al., J Psychosom Res 2008;64:573-582

Pharmacological treatment




Non-opioid antinociceptive drugs

Non-opioid antinociceptive drugs

Drug	Dose (mg)	Frequency of administration
Paracetamol (acetaminophen)	1000	Every 6-8 hours
Aspirin	300	Every 8 hours
Diclofenac	75	Every 8 hours
Diflunisal	500	Every 8 hours
Etodolac	400	Every 8 hours
Ibuprofen	200	Every 6-8 hours
Indomethacin	50	Every 6-8 hours
Ketoprofen	75	Every 8 hours
Ketorolac	10	Every 4-6 hours
Naproxen	500	Every 12 hours
Sulindac	200	Every 12 hours
Piroxicam	40	Once a day
Selective COX-2 inhibitors <ul style="list-style-type: none"> • Celecoxib • Etoricoxib 	200 120	Every 12 hours Once a day

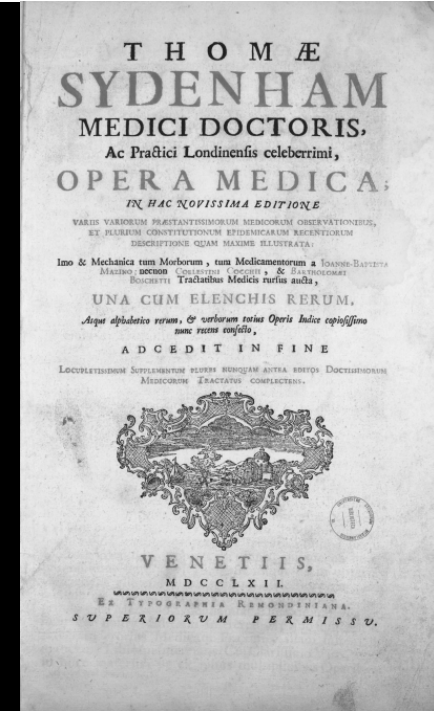Pharmacological treatment



Opioid drugs



Thomas Sydenham (1624-1689)



Among the remedies which it has pleased Almighty God to give to man to relieve his sufferings, none is so universal and so efficacious as opium...

Opioid System

- Endogenous opioids:

- Dynorphins
- β endorphins
- Enkephalins

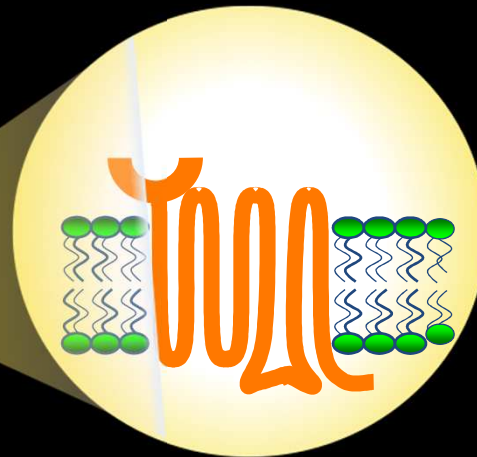
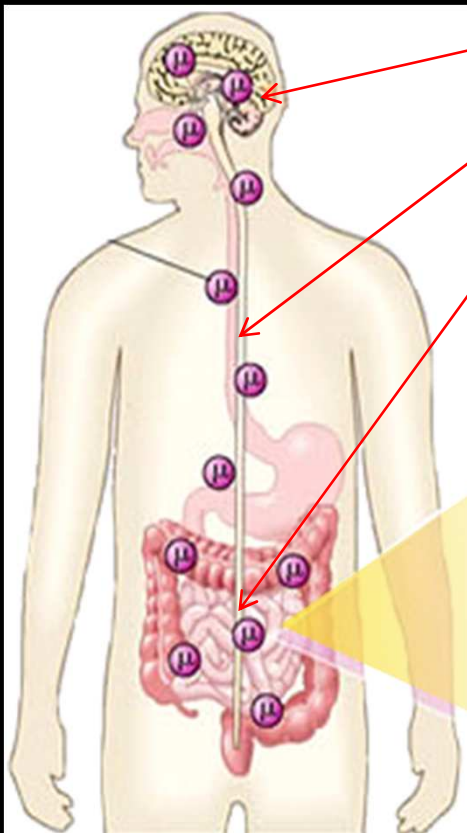
Receptors:

- μ
- δ
- κ
- σ

CNS

PNS

ENS



- Effects:

- Euphoria
- Analgesia
- Sedation
- Relief from diarrhea
- Cough suppression

- Localization & Function in the ENS:

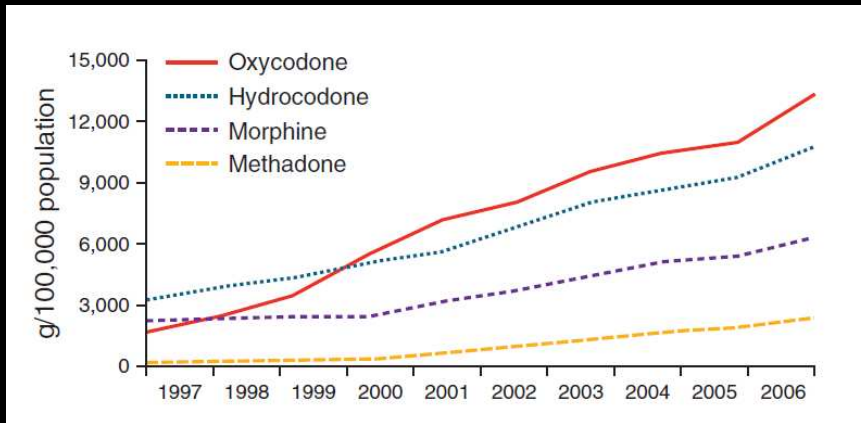
- Enteric neurons
- Smooth muscle cells
- Immune cells
- GI motility & secretion
- Immune response

Opioids

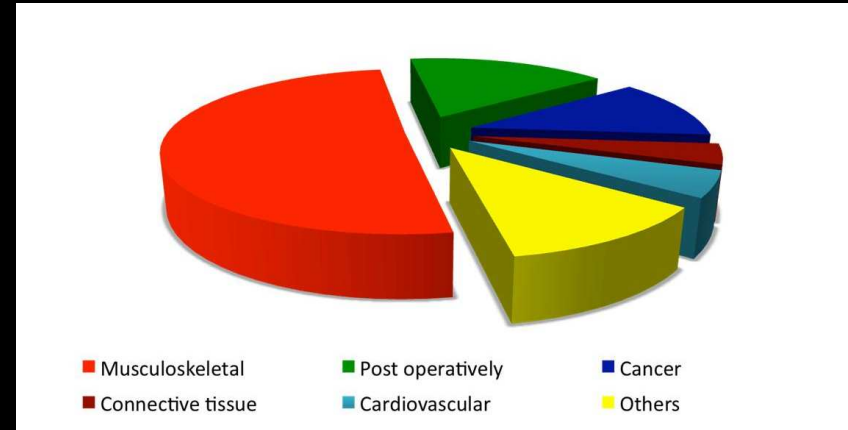
Opioid	Half life (h)	Onset (h)	Duration (h)	Relative potency	Initial dose (mg)	Dosing interval (h)
Pethidine / Meperidine (Demerol)	2-3	0.1-0.4	1-3	0.1	50-150	4
Codeine	3	0.25-1.0	3-4	0.15	30-60	4
Hydromorphone (Jurnista)	2-3	0.3-0.5	2-3	4	2-4	4
Oxycodone (Oxycontin)	2-3	0.5	3-6	1.5	5-10	6
Methadone (Dolophine, Eptadone)	15-30	0.5-1.0	4-6	3	20	6-8
Propoxyphene (Darvon, Darvocet)	6-12	1.0-2.0	3-6	0.15	100	6
Tramadol (Contramal, Ultram)	6-7	1.0-2.0	3-6	0.1	50	4-6
Morphine solution (Oramorph)	2-4	0.5-1.0	4	1	10	3-4
Morphine controlled release (MS Contin)	2-4	1.0	8-12	1	15	8-12
Fentanyl (Durogesic)	1-6	12-24	48-72	100	0.025-0.050/hr	48-72

Opioid use and prescriptions

Increased use of opioids



Indications for opioid prescribing



- In 2012, >240 million prescriptions for opiate analgesics in the USA
- ~40-80% of pts take opioids for chronic, non-cancer pain
- Up to 94% of patients with advanced illness who take opioids require laxatives
- Standard laxatives are often insufficient for treatment of OIC and fail in ≈50% of cases

Camilleri M., *Am J Gastroenterol.* 2011;106(5):835-42; IMS Health 2012 (reported by Fauber J. J Sentinel. March 6, 2013);

Holzer P., *Eur Rev Med Pharmacol Sci.* 2008; 12 (S1): 119-127;6

Side effects

Acute opioid intoxication/overdose

Signs and symptoms

Disruption of central control of peripheral sympathetic activity

Respiratory depression → apnea

Circulatory depression → hypotension

Constricted pupils (maybe dilated with meperidine)

Convulsions with meperidine and propoxyphene

Arrhythmias with propoxyphene

Pulmonary edema

Reduced reflexes

CNS depression

Drowsiness → sedation → coma

Treatment

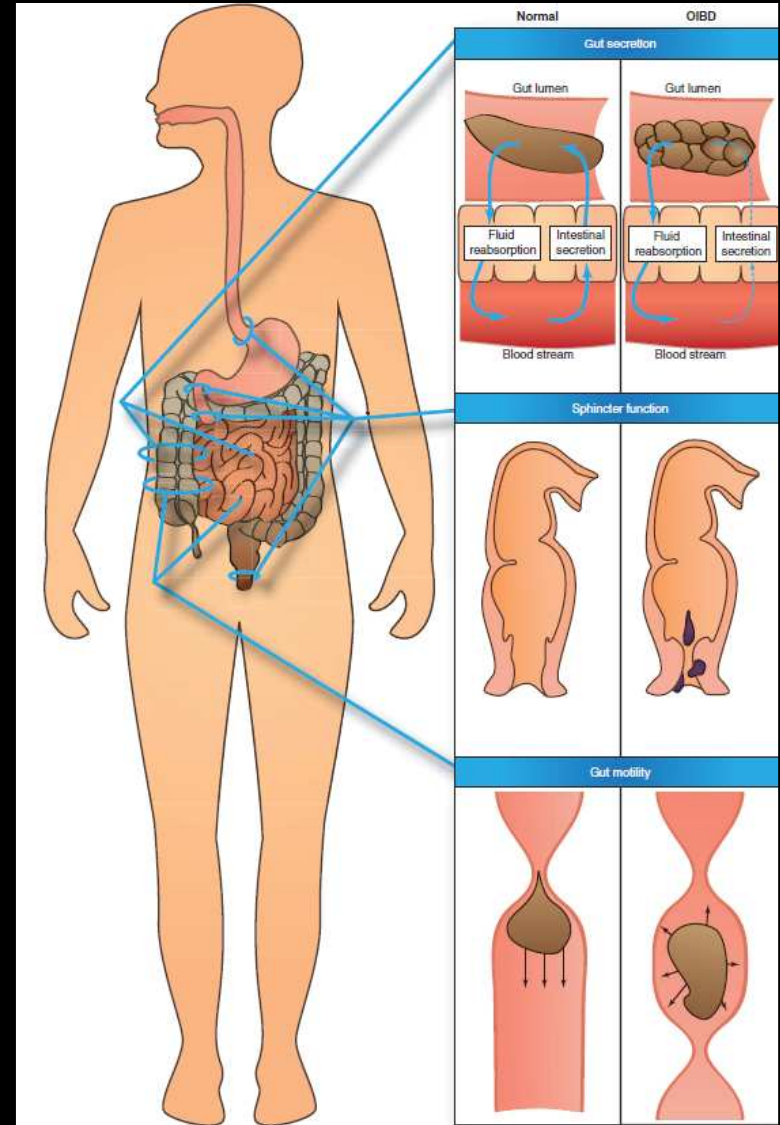
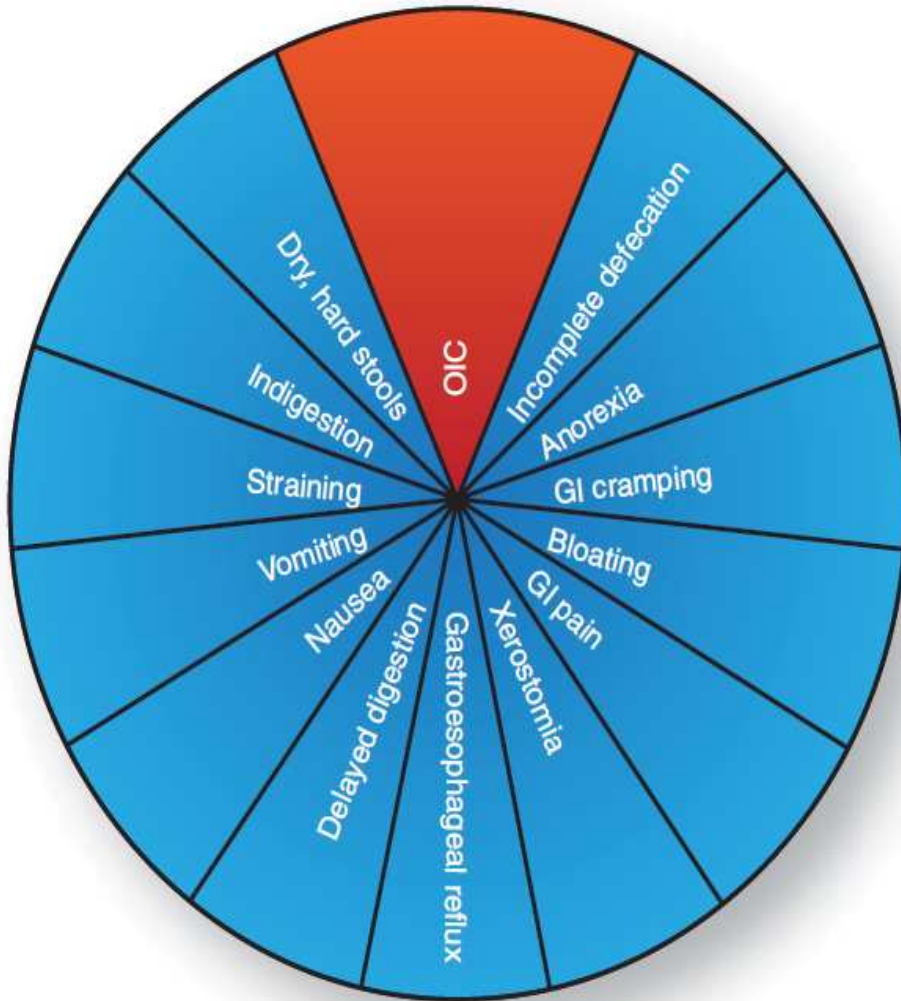
Naloxone

0.4 mg intravenously and repeated as necessary

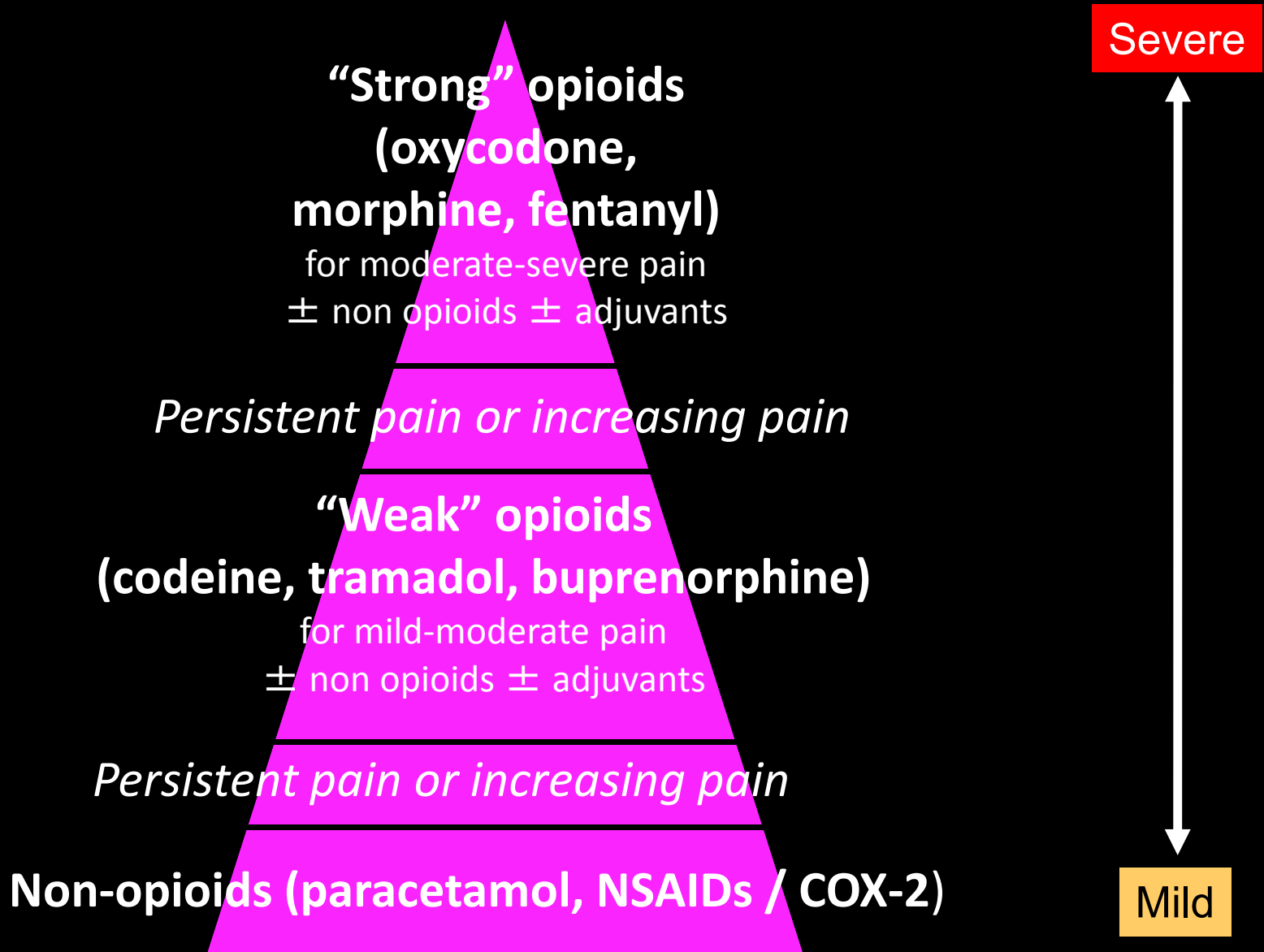
Short duration of action, 1-2hrs


Give every 30mins until patient is stable

Opioid induced bowel dysfunction



WHO pain ladder





DOLORE ADDOMINALE

E' sintomo comune di un gran numero di affezioni morbose e ne rappresenta il segnale d'allarme.

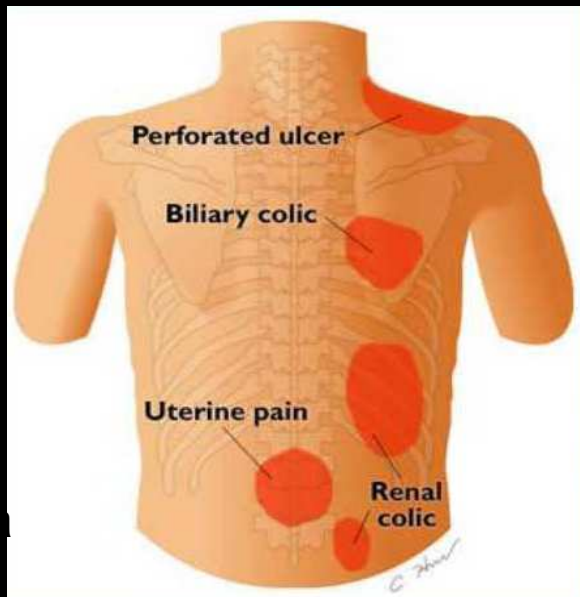
Il dolore è provocato da:

- distensione o spasmo di un viscere cavo (recettori algici presenti nella tonaca muscolare liscia)**
- distensione della capsula degli organi parenchimatosi (recettori algici presenti nelle capsule (fegato, milza, reni)**
- trazione sul mesentere, sui legamenti, sul peritoneo**
- infiltrazione o compressione neoplastica di nervi sensitivi**
- ischemia**

DOLORE RIFERITO

Si ha quando il dolore viene percepito lontano dalla sede della lesione.

E' dovuto alla confluenza degli stimoli algogeni sullo stesso neuromero dove affluiscono gli stimoli originati dall'organo interessato e dal dermatomero dove viene riferito il dolore.



DOLORE IN ADDOME SUPERIORE DESTRO

- FEGATO (stasi, ascesso epatico o sottoepatico, colangite, ecc...)
- COLECISTI (calcolosi complicata, empiema, ecc...)
- RENE (neoplasia, infarto renale, nefrolitiasi)
- RADICI NERVOSE (Herpes Zoster)
- PLEURA (Pleurite)

DOLORI EPI E MESOGASTRICI


- CUORE (angina pectoris, IMA, pericardite)
- STOMACO (ernia jatale, gastrite, ulcera)
- DUODENO (duodenite, ulcera)
- PANCREAS (pancreatite acuta o cronica, neoplasie)
- INTESTINO
- VASI ADDOMINALI (“claudicatio addominale”)

DOLORI IN ADDOME SUPERIORE SINISTRO

- CUORE (angina pectoris, IMA, pericardite)
- STOMACO (ulcera, neoplasia)
- INTESTINO (colite, neoplasie)
- PANCREAS (pancreatite acuta o cronica, neoplasie)
- RENE (nefrolitiasi, infarto renale, neoplasia)
- PLEURA (pleurite)
- MILZA (infarto splenico, splenomegalia)

DOLORI NELL'ADDOME INFERIORE

- INTESTINO (appendicite, ernia, ileite terminale, diverticolite, colon irritabile , neoplasia...)
- APPARATO UROGENITALE (nefrolitiasi, affezioni delle vescichette seminali, annessite, cisti ovarica, gravidanza tubarica, tumore uterino, miofibroma)



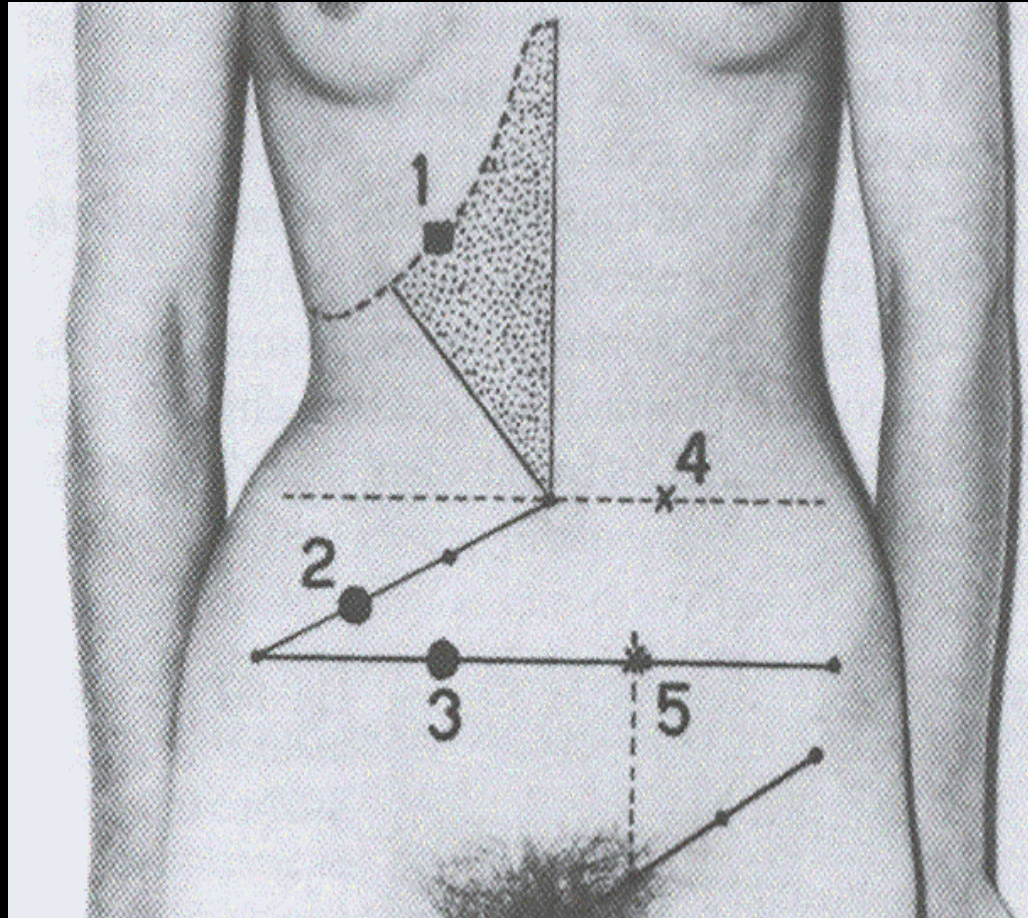
PUNTO CISTICO: ALL'INTERSEZIONE DEL MARGINE ESTERNO DEL M. RETTO DESTRO CON L'ARCATA COSTALE.

NELLE COLECISTITI ACUTE LA PALPAZIONE DEL PUNTO CISTICO E' ESTREMAMENTE DOLOROSA

SEGNO DI MURPHY: ARRESTO DELL'ATTO INSPIRATORIO IN SEGUITO AL DOLORE INDOTTO DALLA PALPAZIONE DEL PUNTO CISTICO (SI DISPONGONO LE PUNTE DELLE DITA DELLA MANO DESTRA IN PROSSIMITA' DEL PUNTO CISTICO AFFONDANDOLE LEGGERMENTE DALL'AVANTI ALL'INDIETRO E DAL BASSO VERSO L'ALTO, SI INVITA IL PAZIENTE AD ESEGUIRE UNA PROFONDA INSPIRAZIONE; CON L'ABBASSAMENTO DEL DIAFRAMMA L'INSPIRAZIONE PORTA AD UN BRUSCO AVVICINAMENTO DELLA COLECISTI ALLE DITA DELL'OSSERVATORE DA CUI IL DOLORE CHE FA CESSARE AUTOMATICAMENTE L'ATTO INSPIRATORIO)

SEGNO DI MURPHY POSITIVO

LITIASI DELLA COLECISTI



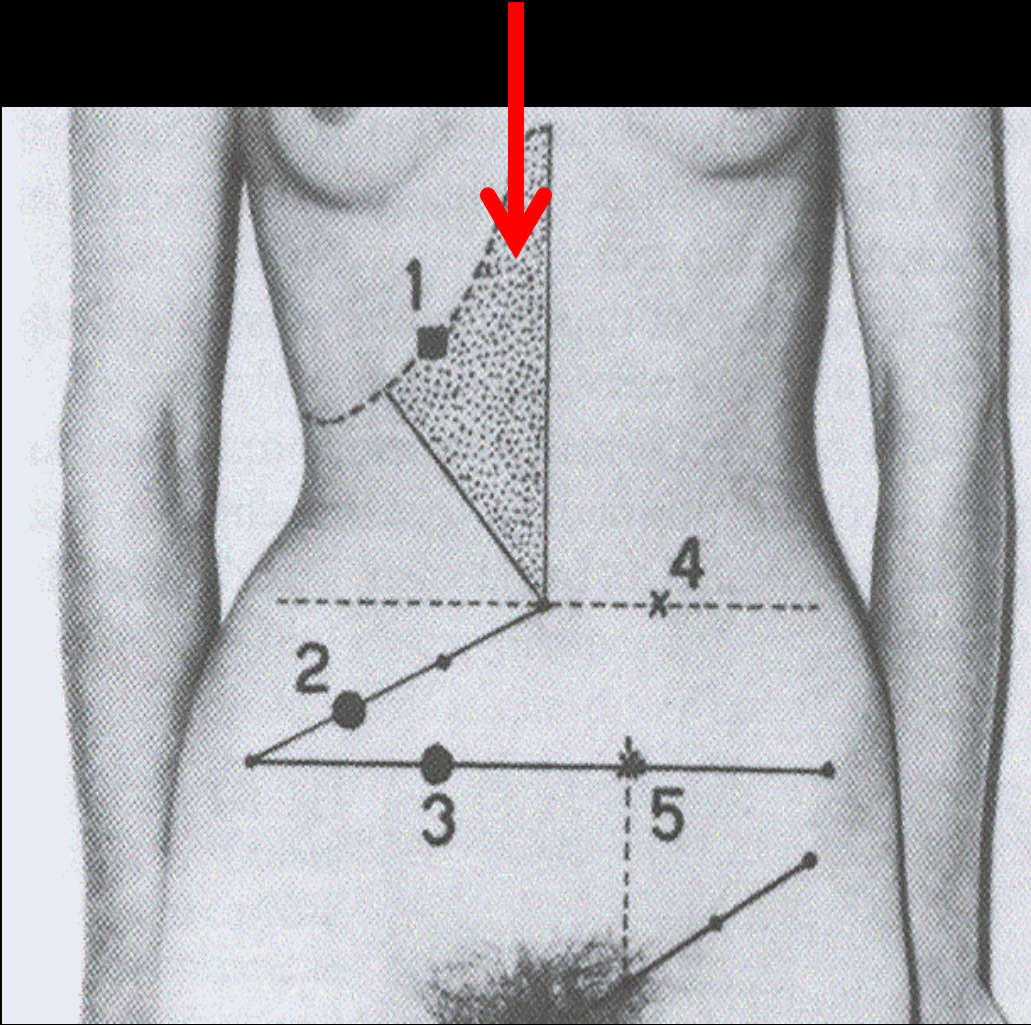
TRIANGOLO PANCREATICO DUODENALE DI CHAUFFARD

(tracciate le linee xifo-ombelicale ed ombelicale trasversa si disegna la bisettrice dell'angolo retto da esse delimitato in corrispondenza del quadrante superiore destro dell'addome. L'angolo situato tra questa bisettrice e la linea xifo-ombelicale comprende il triangolo Pancreatico duodenale di Chauffard)

CORRISPONDE ALLA PROIEZIONE DELLA PRIMA PORZIONE DEL DUODENO, DELLA TESTA DEL PANCREAS E DEL COLEDOCO.

E' DOLENTE NELL' ULCERA DUODENALE, NELLE PANCREATITI, NELLA LITIASI DEL COLEDOCO.

TRIANGOLO PANCREATICO DUODENALE DI CHAUFFARD



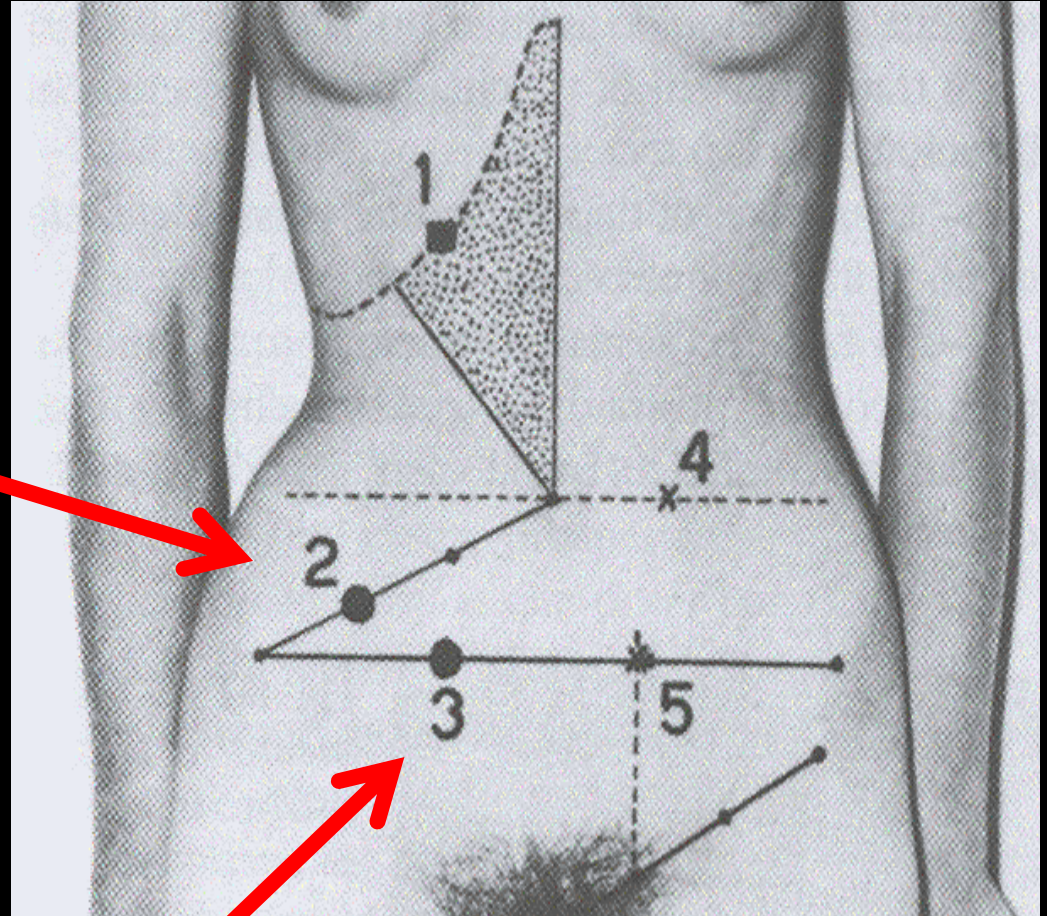
PUNTI APPENDICOLARI

NELLE FLOGOSI ACUTE E CRONICHE DELL' APPENDICE LA DOLORABILITA' ALLA PALPAZIONE SI LOCALIZZA IN CORRISPONDENZA DEL QUADRANTE INFERIORE DESTRO

PUNTO DI MAC BURNEY: SITUATO ALL' UNIONE TRA IL TERZO LATERALE E I DUE TERZI MEDIANI DELLA LINEA SPINO-OMBELICALE (LA LINEA CHE UNISCE LA SPINA ILIACA ANTERO-SUPERIORE ALL' OMBELICO)

PUNTO DI LANZ: SITUATO TRA TERZO MEDIO E TERZO LATERALE DESTRO DELLA LINEA BISPINO-ILIACA (LA LINEA CHE UNISCE LE DUE SPINE ILIACHE ANTERIORI SUPERIORI)

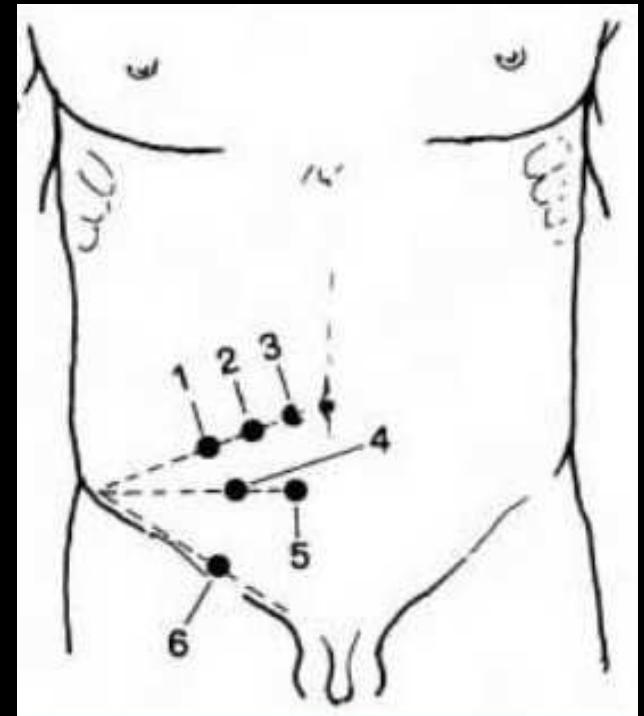
PUNTO DI MAC BURNEY

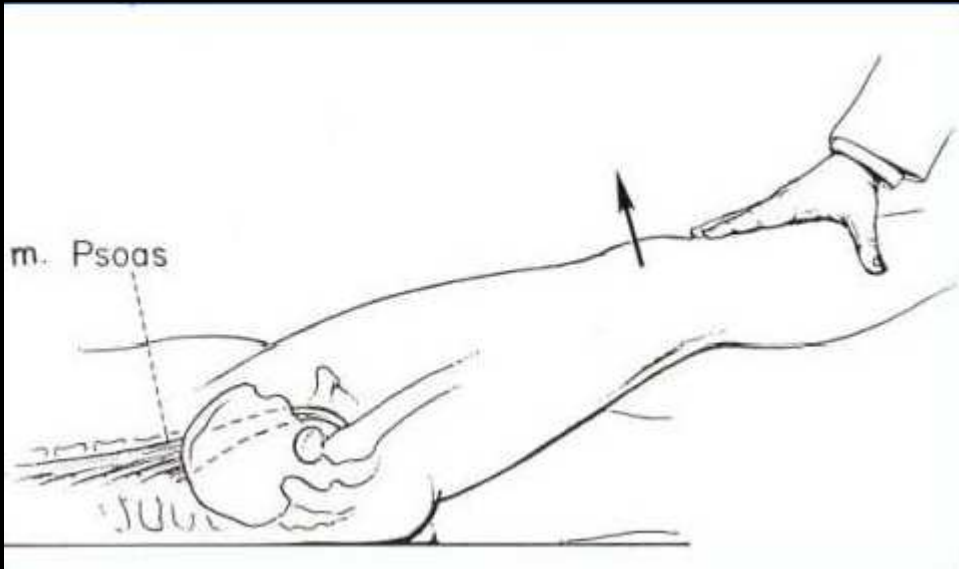


PUNTO DI LANZ

Punti e segni appendicolari

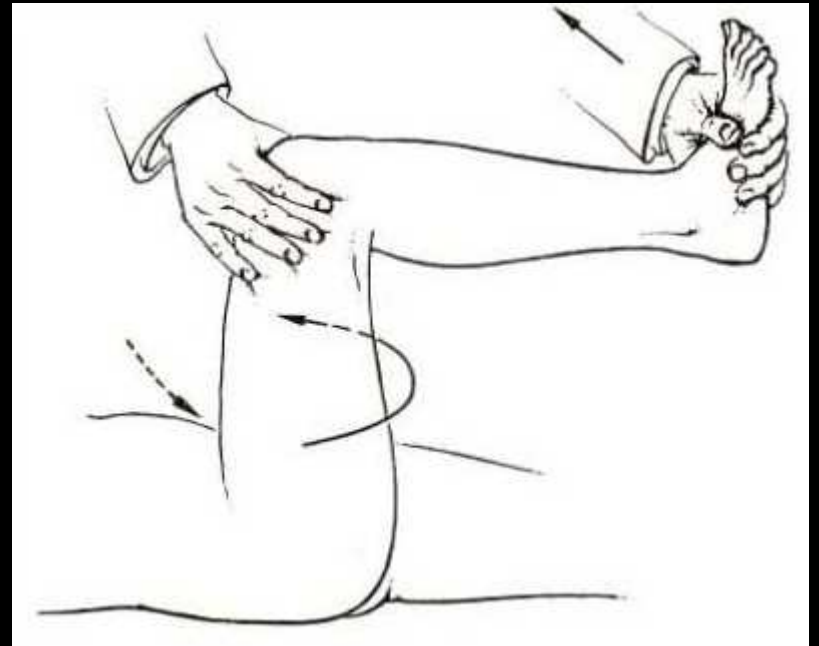
- punto di Mc Burney (1)
- punto di Morris (2)
- punto di Munro (3)
- punto di Lanz (4)
- punto di Clado (5)
- punto di Jalaguier (6)
- segno di Rovsing
(dolore ds alla compressione a sn)
- segno dell'ileo-psoas
(sollevamento coscia contro
pressione di mano opponente)
- segno dell'otturatore
(adduzione della coscia flessa contro
pressione di mano opponente)





SEGNO DELLO
PSOAS

SEGNO
DELL'OTTURATORIO



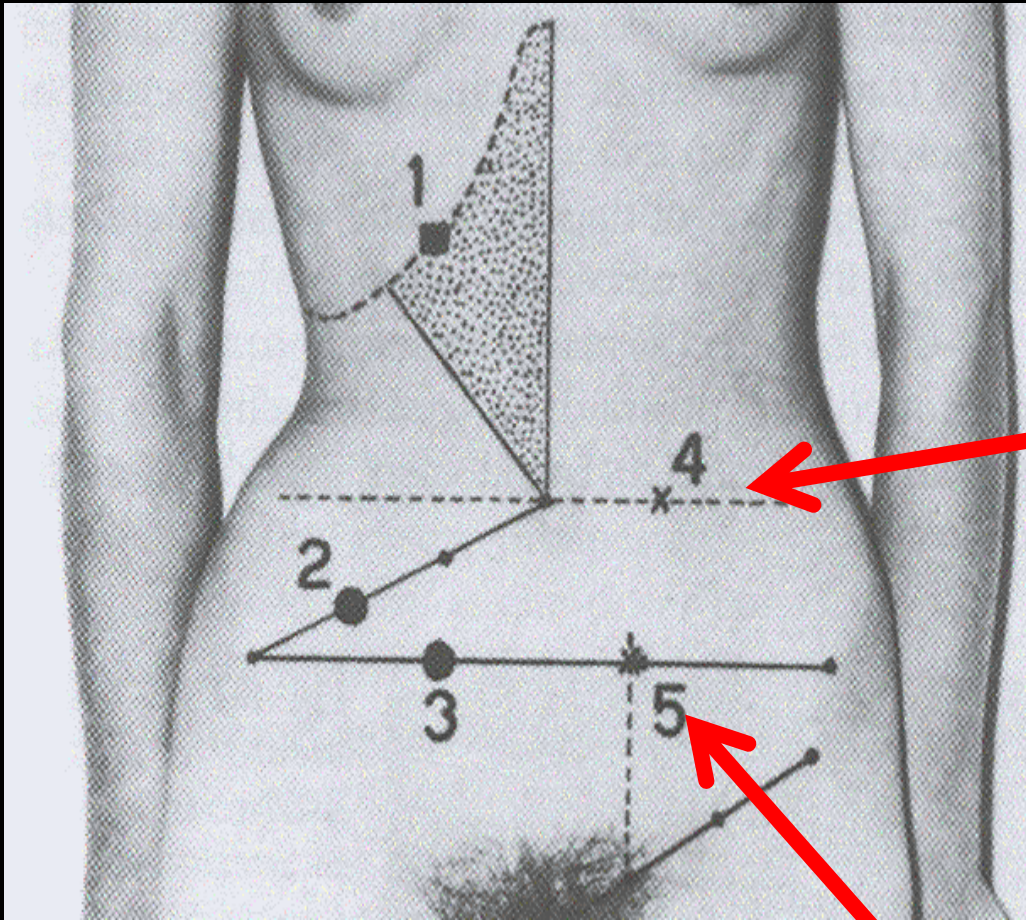
PUNTI URETERALI

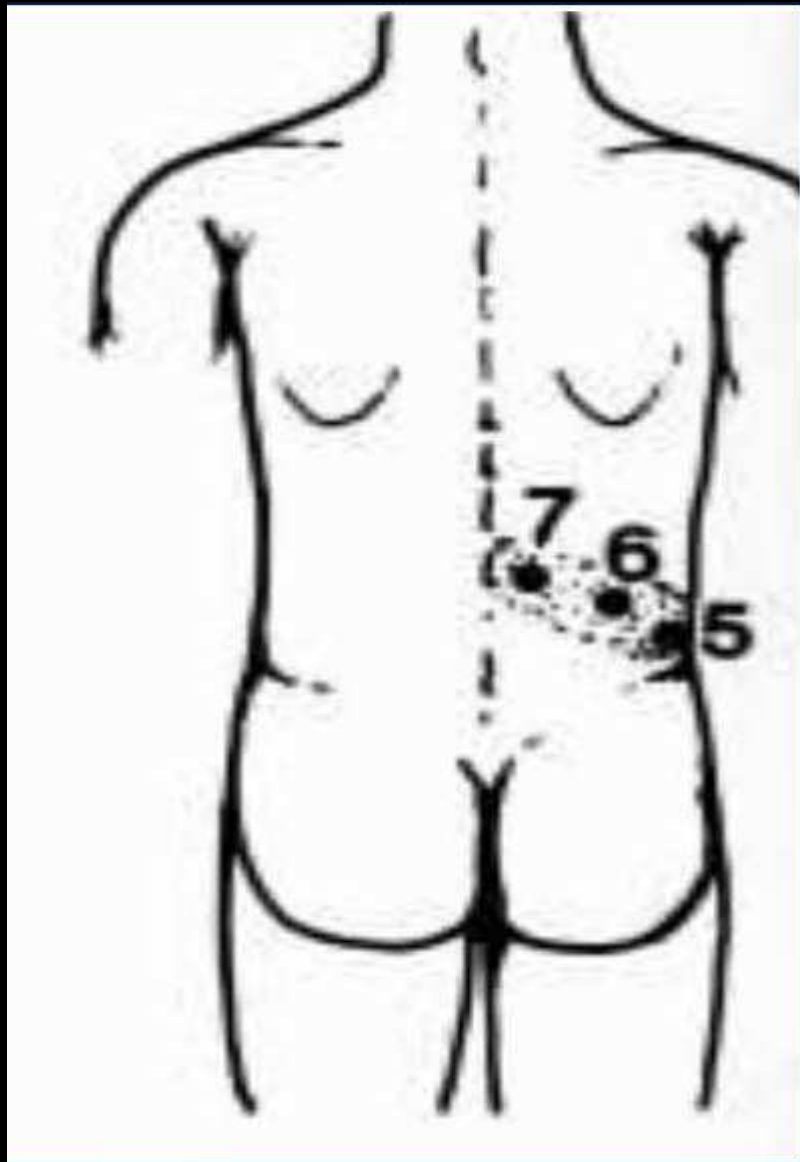
LA DOLORABILITA' DI UNO O PIU' PUNTI URETERALI E' INDICATIVA DI UN CALCOLO IMPEGNATO NELL' URETERE O DI UN DIFFUSO INTERESSAMENTO FLOGISTICO O MECCANICO DELL' URETERE STESSO

PUNTO URETERALE SUPERIORE: SULLA LINEA OMBELICALE TRASVERSA A TRE DITA DALL' OMBELICO

PUNTO URETERALE MEDIO: SULLA LINEA BISPINOILIACA, TRA TERZO MEDIO ED ESTERNO

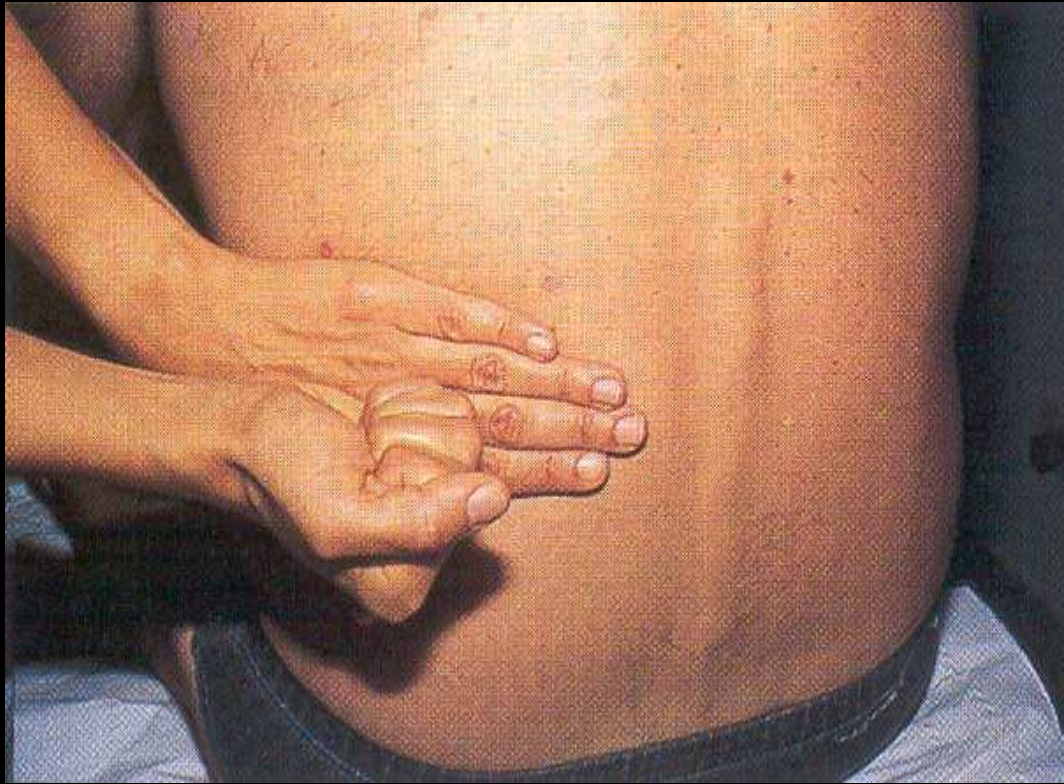PUNTO URETERALE INFERIORE: CORRISPONDE ALLO SBOCCO DELL' URETERE IN VESCICA VALUTABILE ALL' ESPLORAZIONE RETTALE NELL' UOMO (LATERALMENTE ED AVANTI ALLE VESCICOLE SEMINALI) ED ALL' ESPLORAZIONE VAGINALE NELLA DONNA (SPINGENDO IN AVANTI IL FORNICE LATERALE)

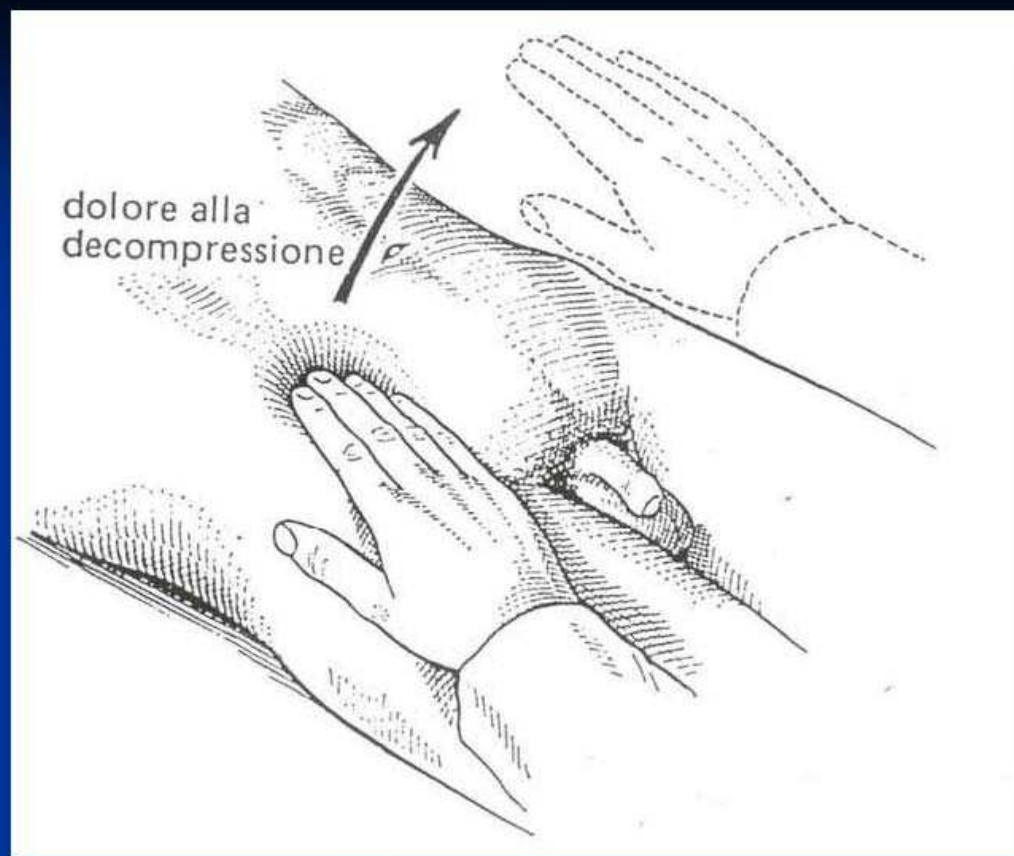





Punti renali

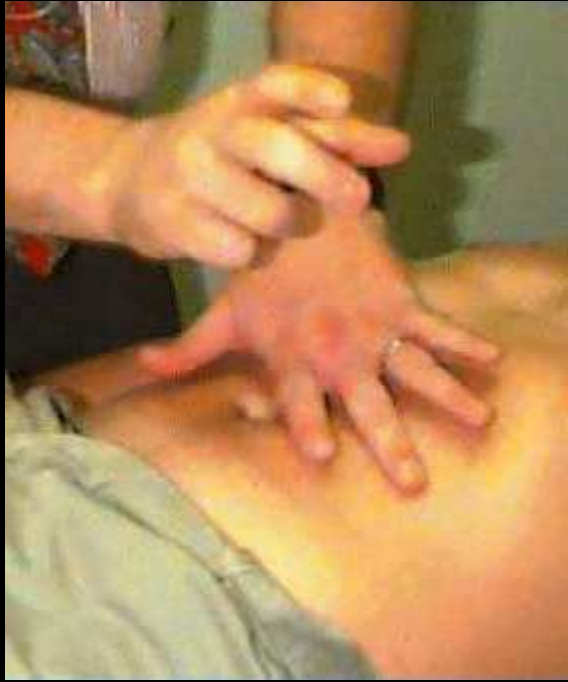- punto costo-muscolare (5)
- punto costo-lombare (6)
- punto costo-vertebrale (7)






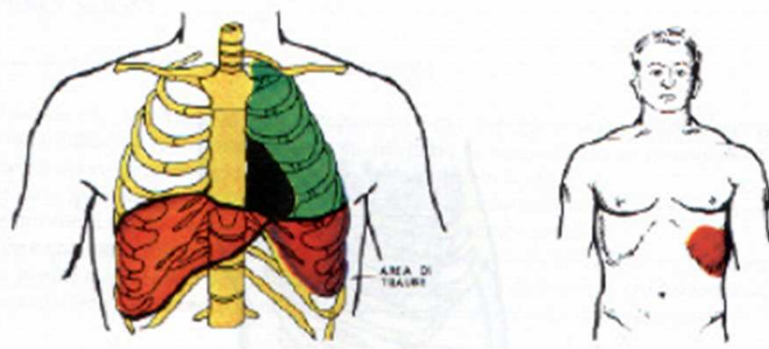








AREA DI TRAUBE



AREA DI TIMPANISMO E' dovuta alla proiezione del fondo gastrico sulla parete costale


LOCALIZZAZIONE:


- 1) VI cartilagine costale SX
- 2) IX cartilagine costale
- 3) Linea ascellare anteriore


Larga 12cm circa

Alta 10cm circa

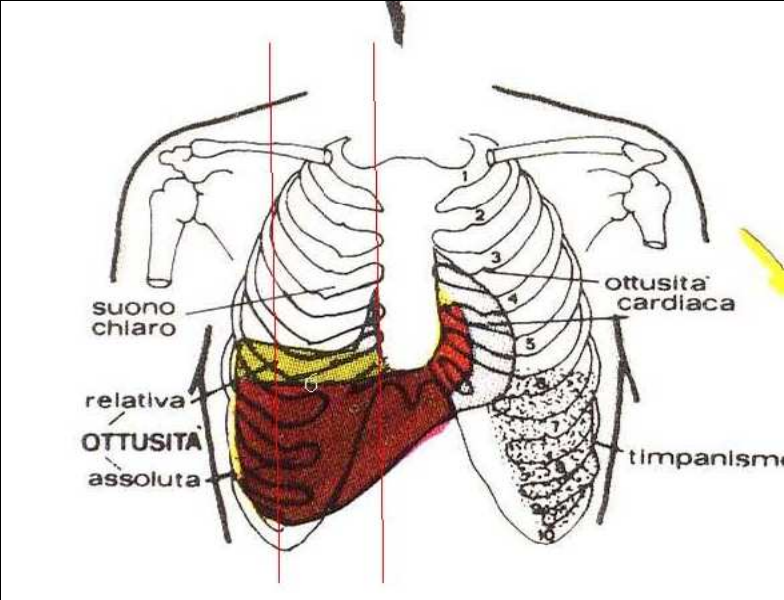
Grande importanza diagnostica assume la scomparsa dell'area di timpanismo.







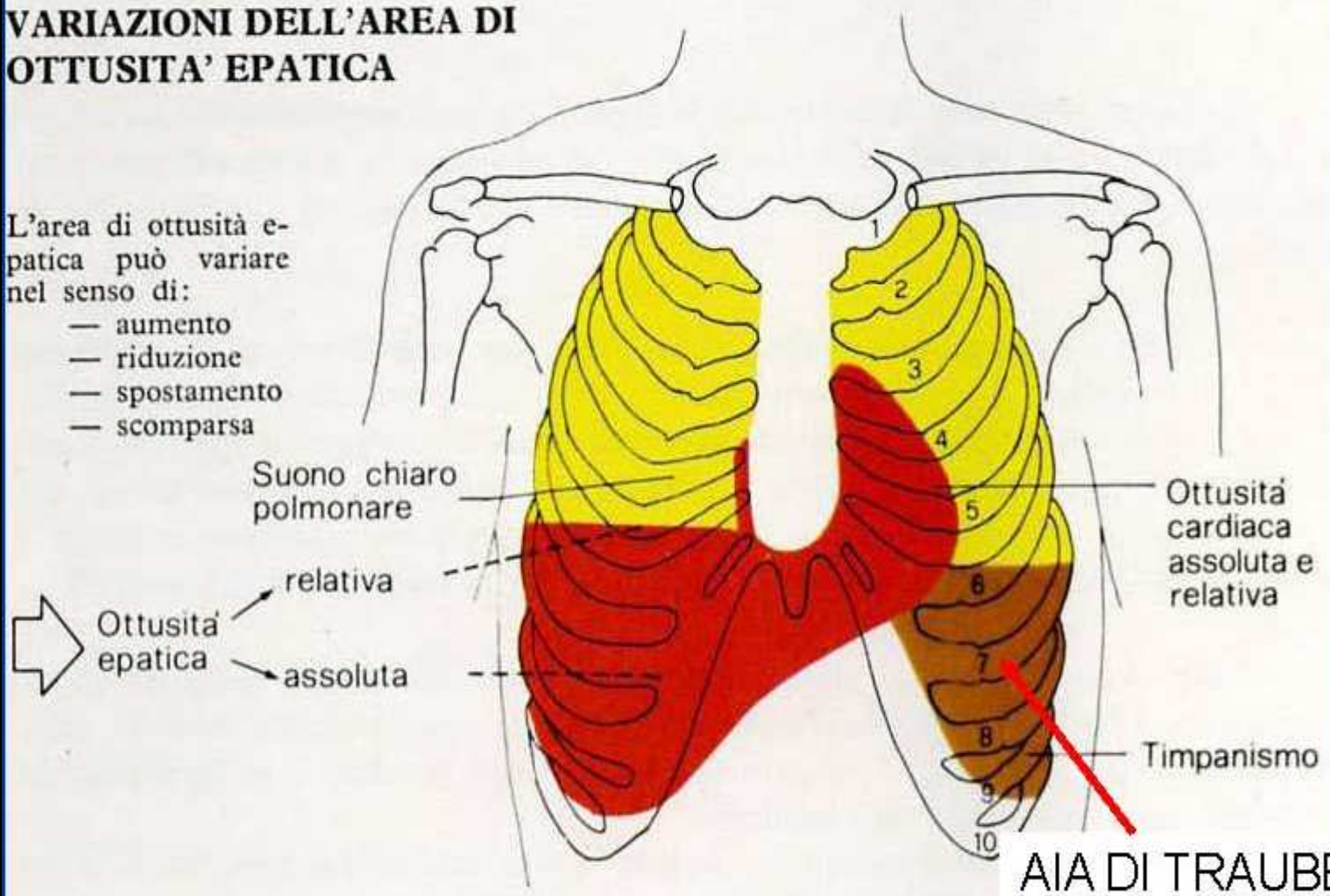


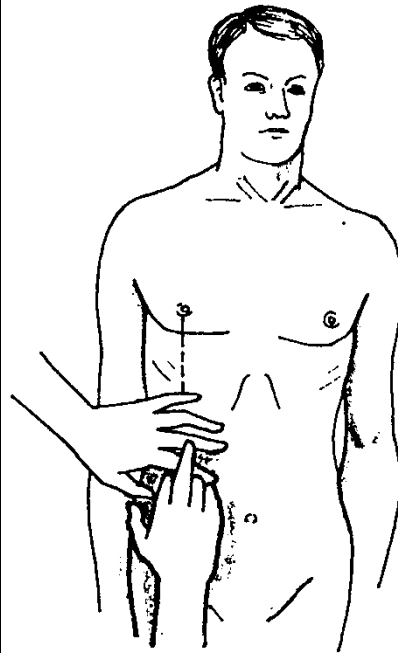


VARIAZIONI DELL'AREA DI OTTUSITA' EPATICA

L'area di ottusità epatica può variare nel senso di:

- aumento
- riduzione
- spostamento
- scomparsa



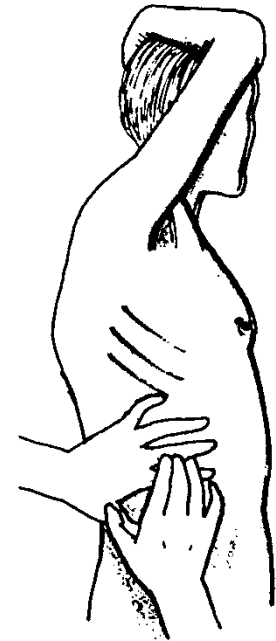

percussione anteriore del
fegato (sull'emiclaveare)

massima ampiezza
dell'area di ottusità:

10 cm.


(9 - 12)




percussione laterale
del fegato (lungo la
linea ascellare ant.)

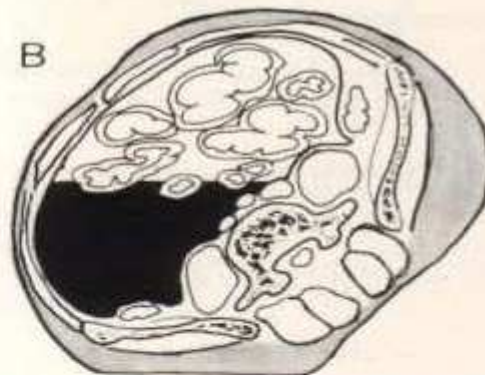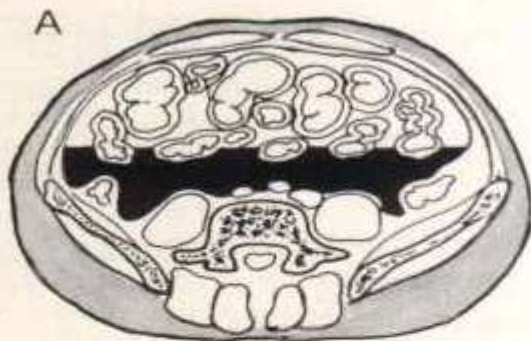
massima ampiezza
dell'area di
ottusità:

7 cm.

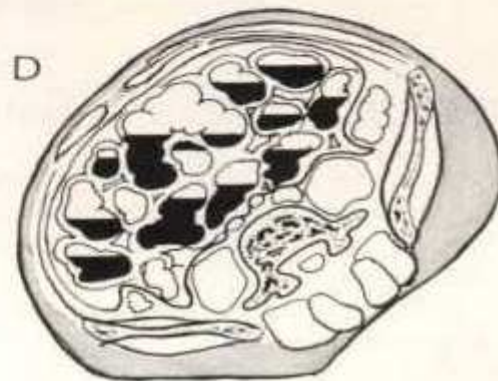
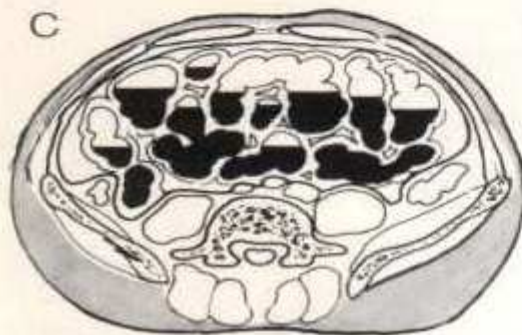





FLUIDO LIBERO NELLA CAVITA' PERITONEALE.

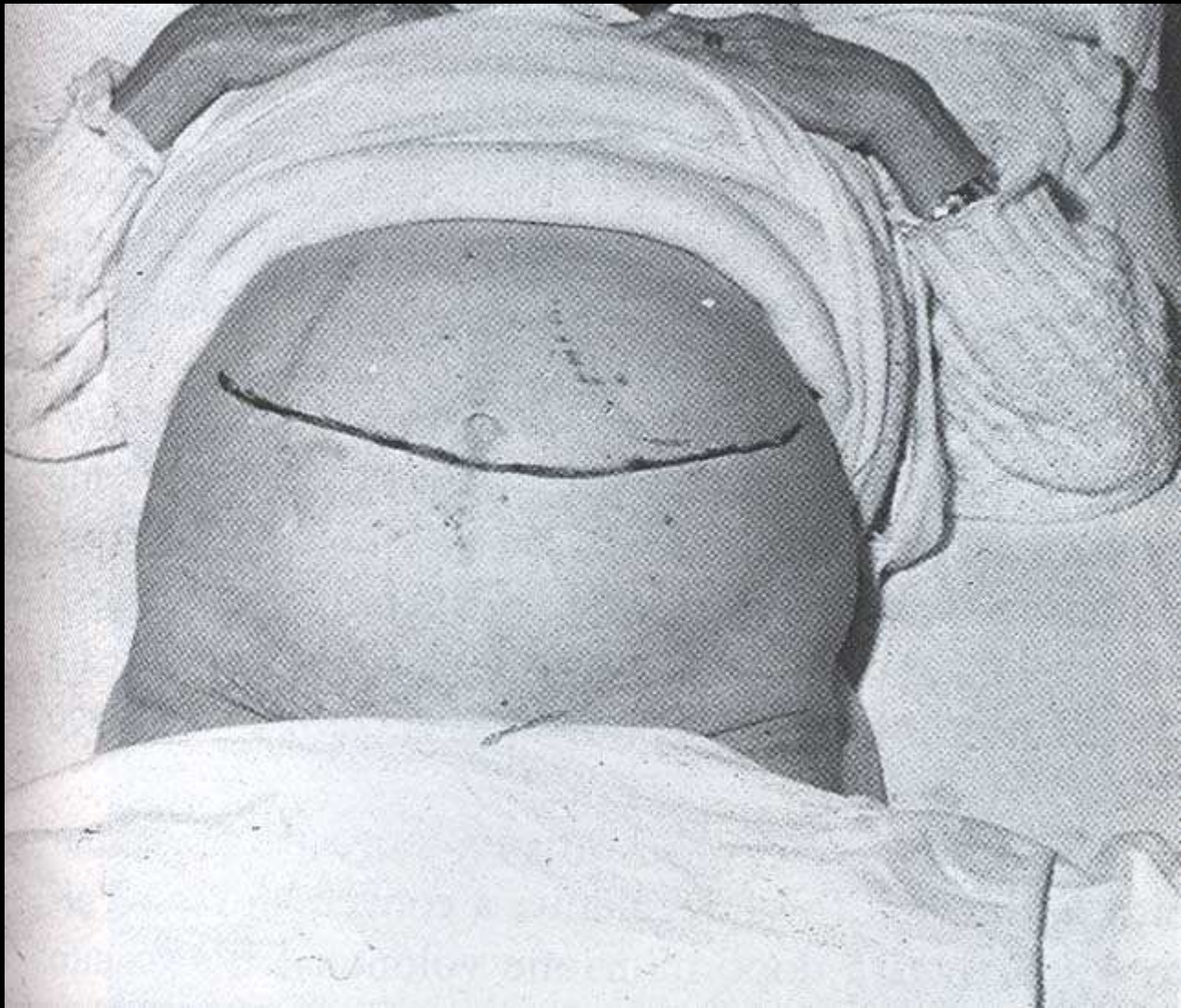


FLUIDO CONTENUTO ENTRO LE ANSE INTESTINALI



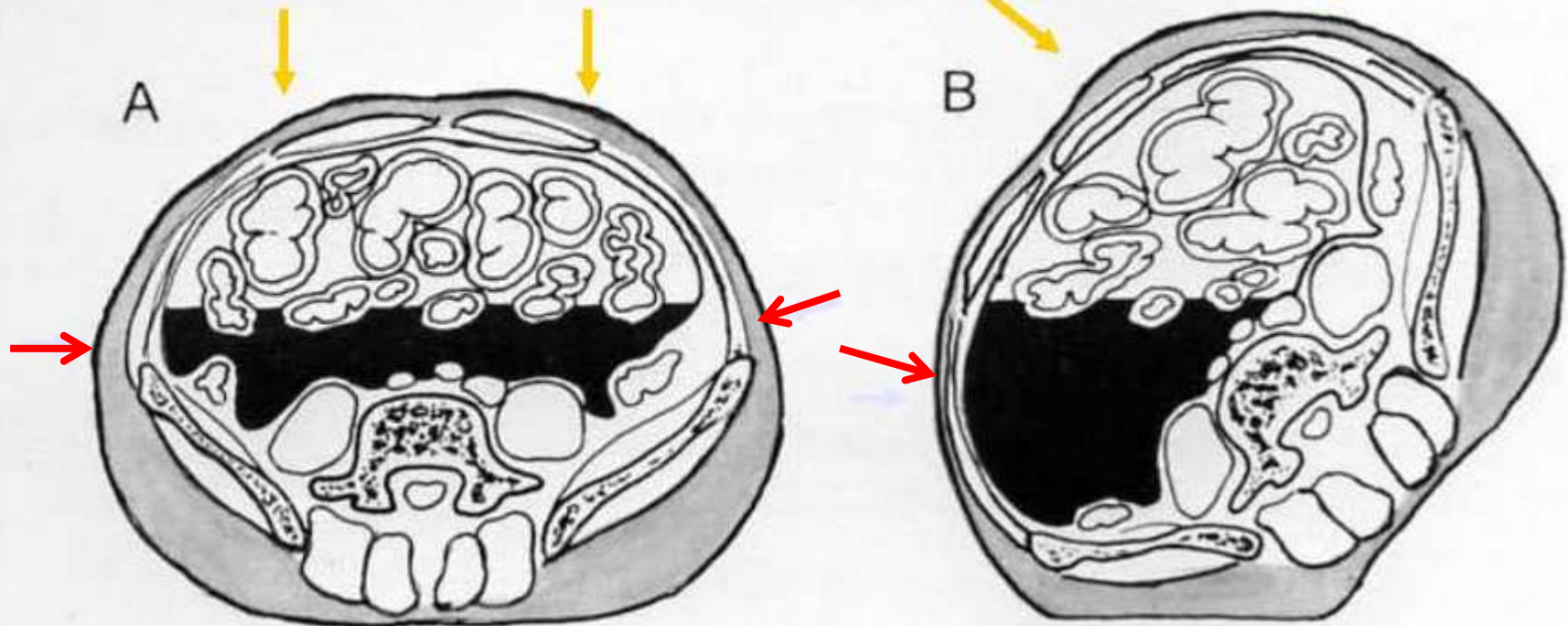




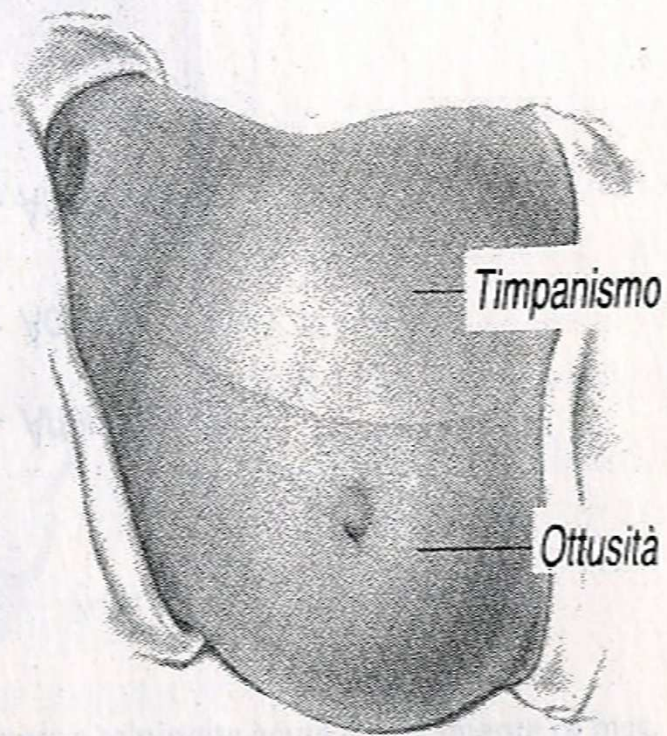
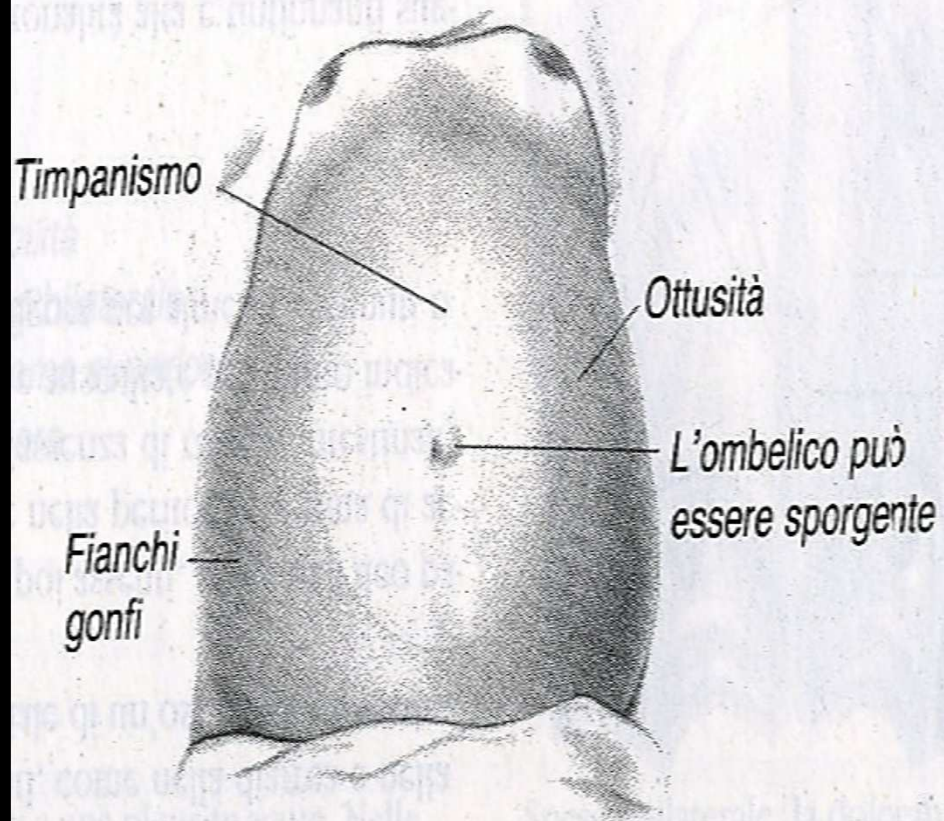


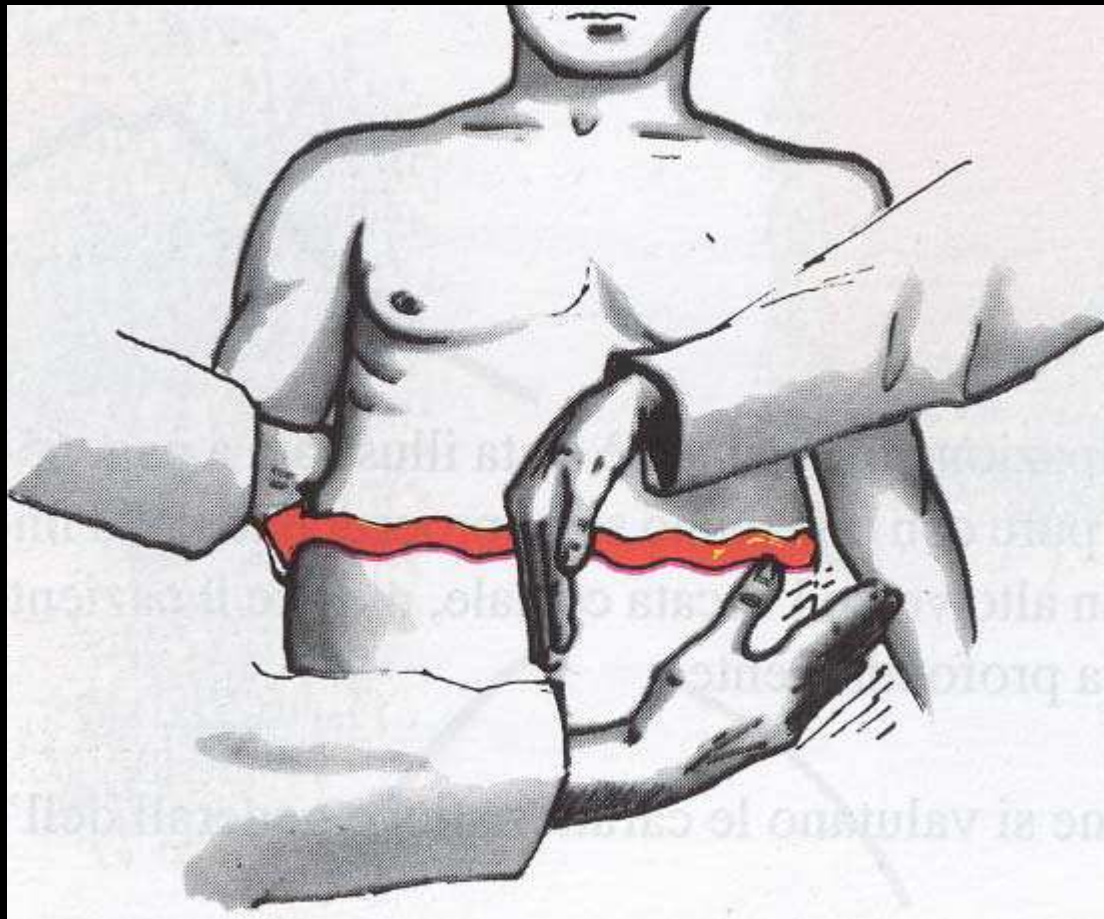



FLUIDO LIBERO NELLA CAVITA' PERITONEALE.




LIQUIDO ASCITICO




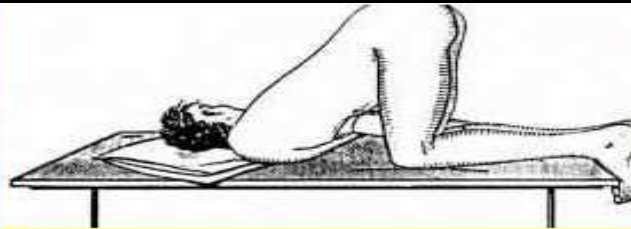



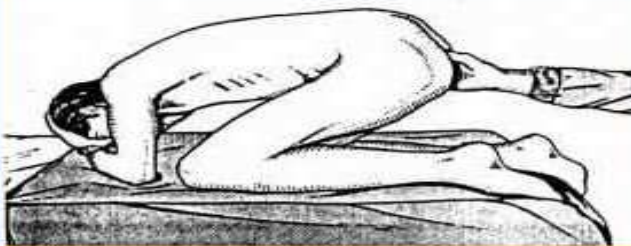




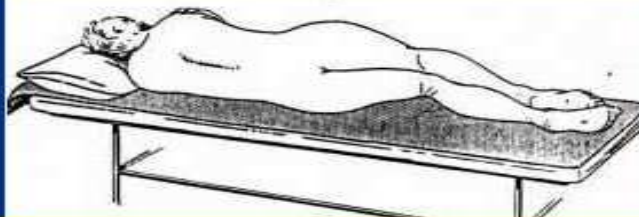




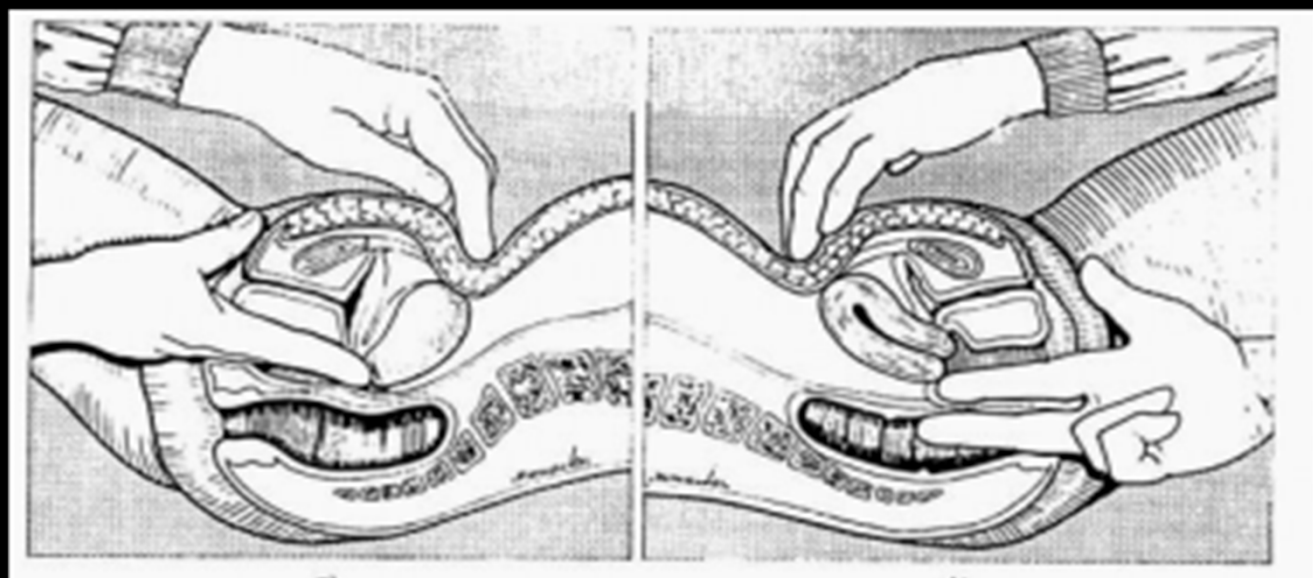
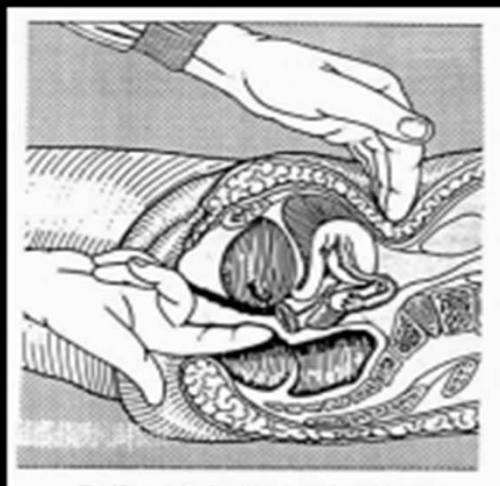Posizione genu-pettorale



Posizione genu-gomitale



Posizione laterale di Sims





}


}

}


}













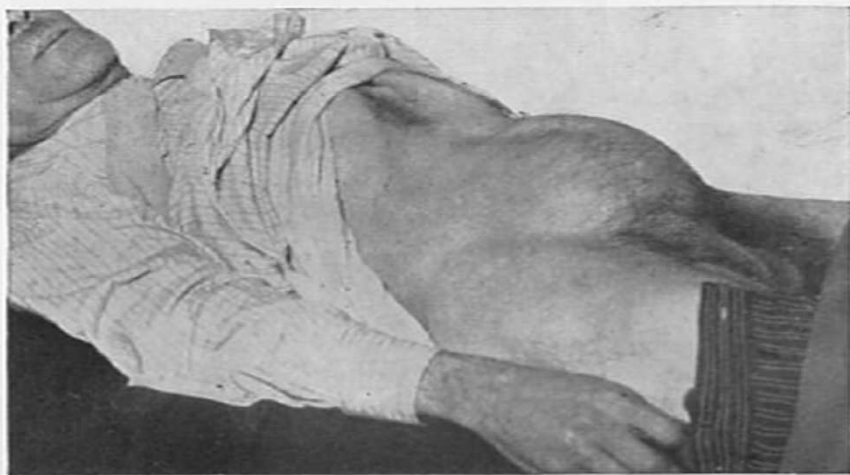



Fig. 717 - Ritenzione acuta. La vescica si estende fino all'ombelico.





N.B.

QUANDO IL COLON E' SPASTICAMENTE
CONTRATTO, L'ESAMINATORE,
DISPONENDO LE DITA
PERPENDICOLARMENTE AL TRATTO
INTERESSATO, PALPERA' LA CORDA
COLICA





REPERTO FREQUENTE NELLA
SD DELL'INTESTINO IRRITABILE
















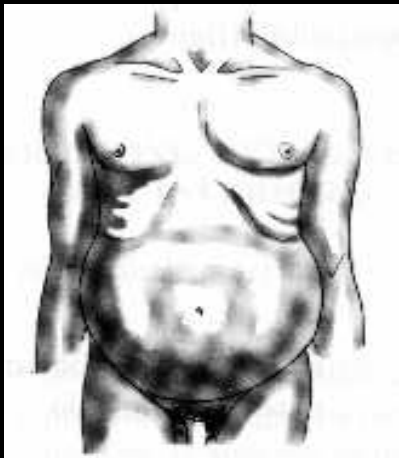
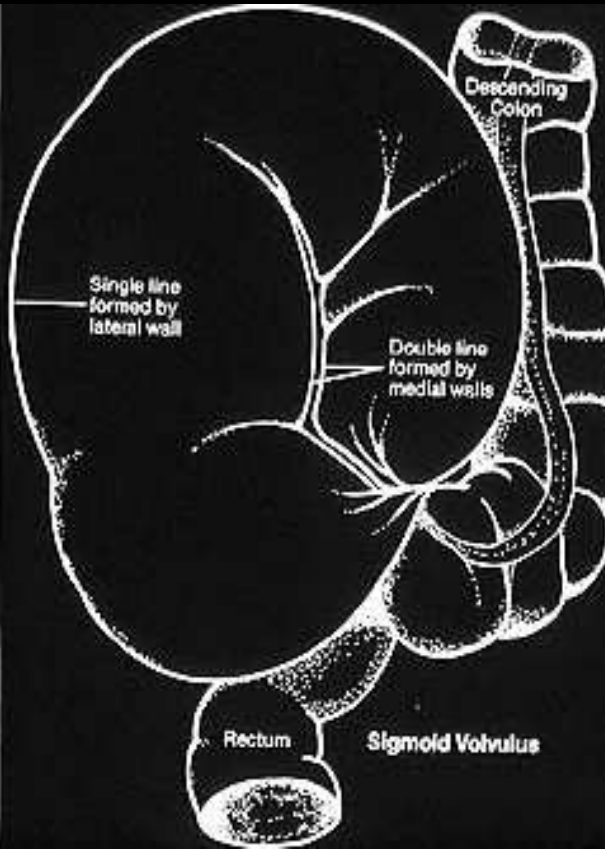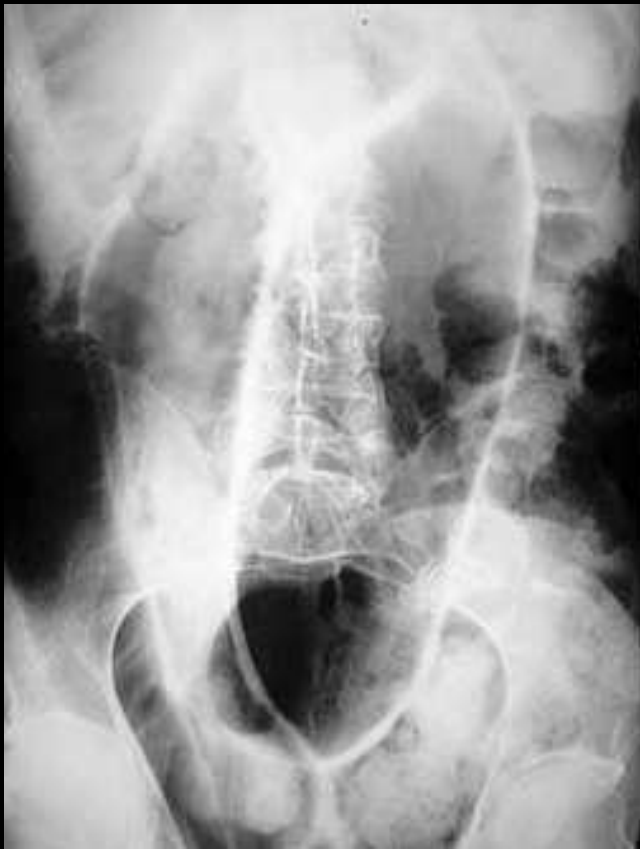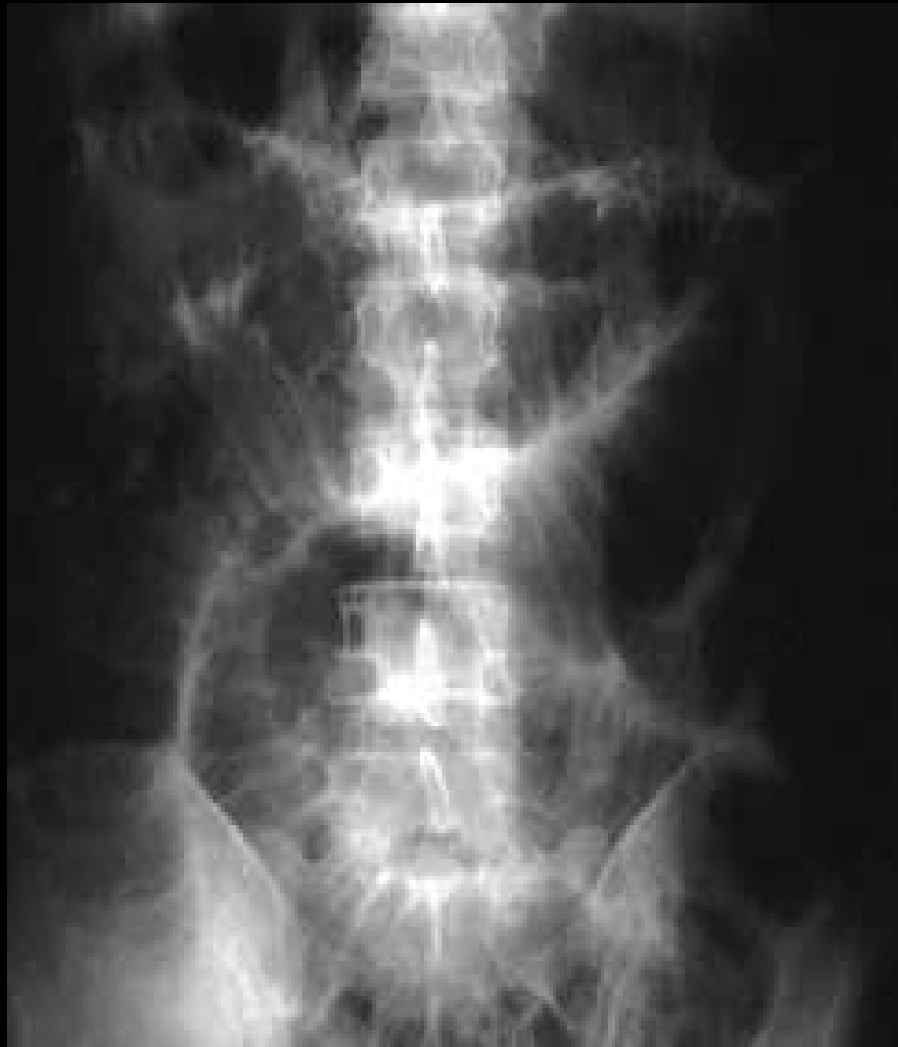




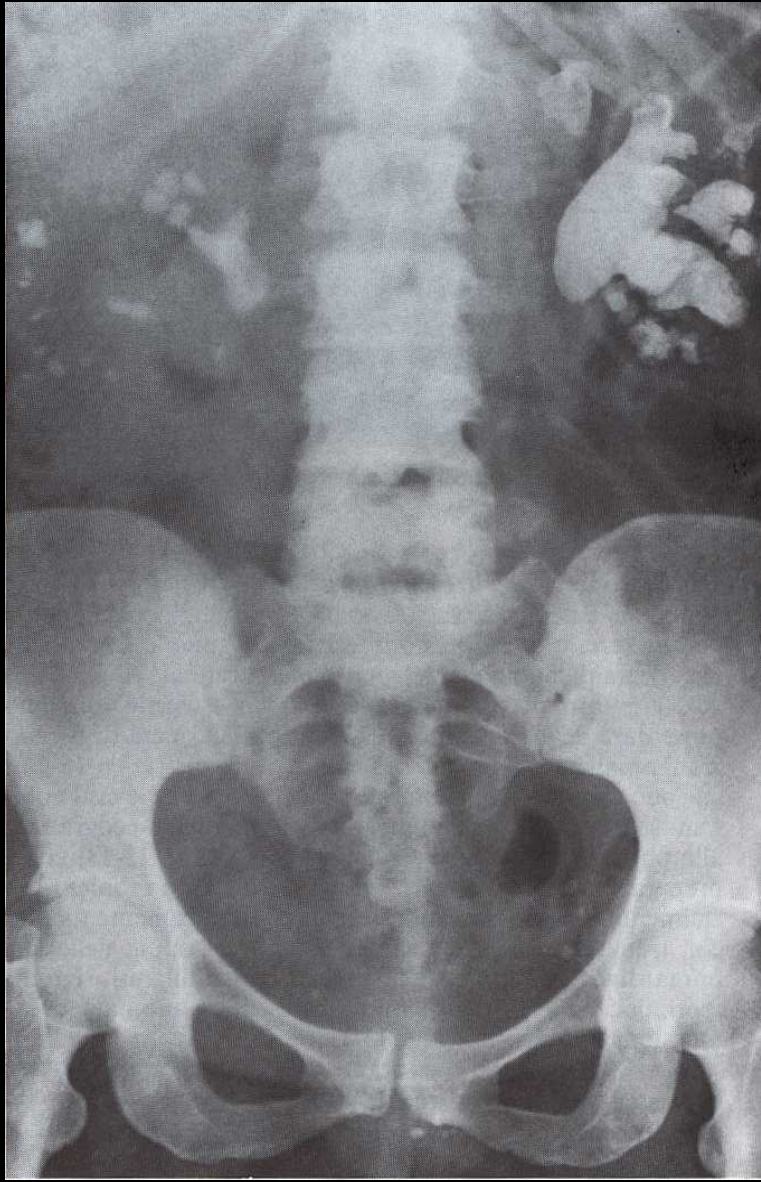

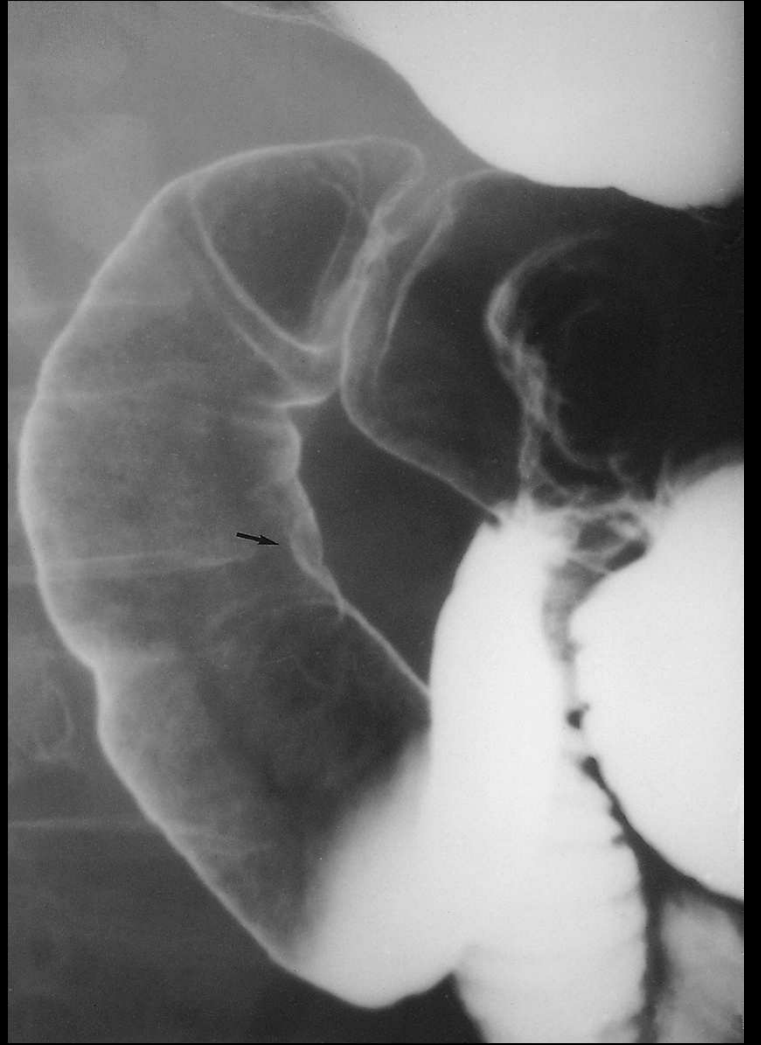
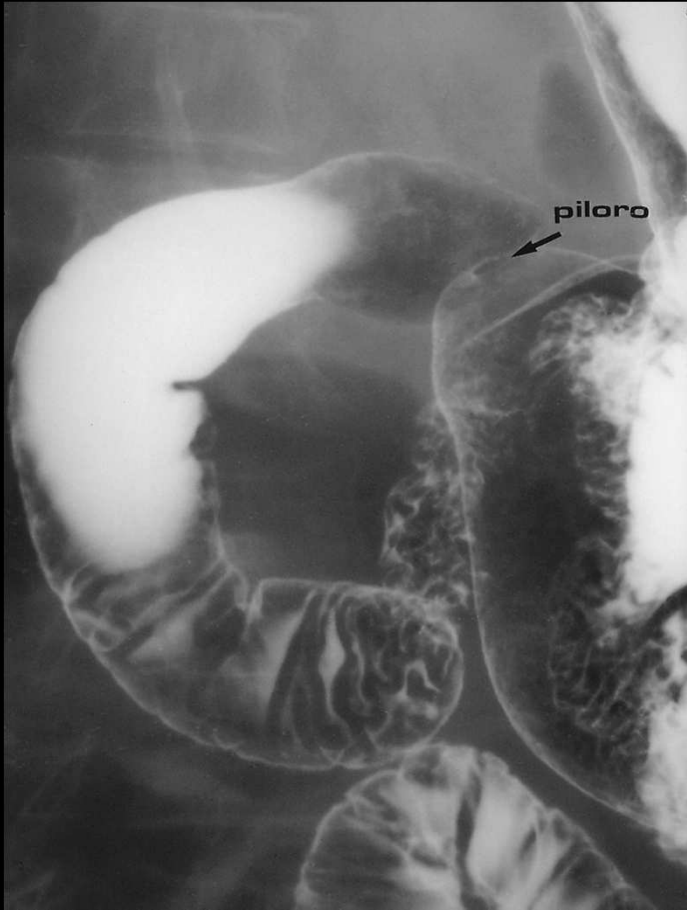


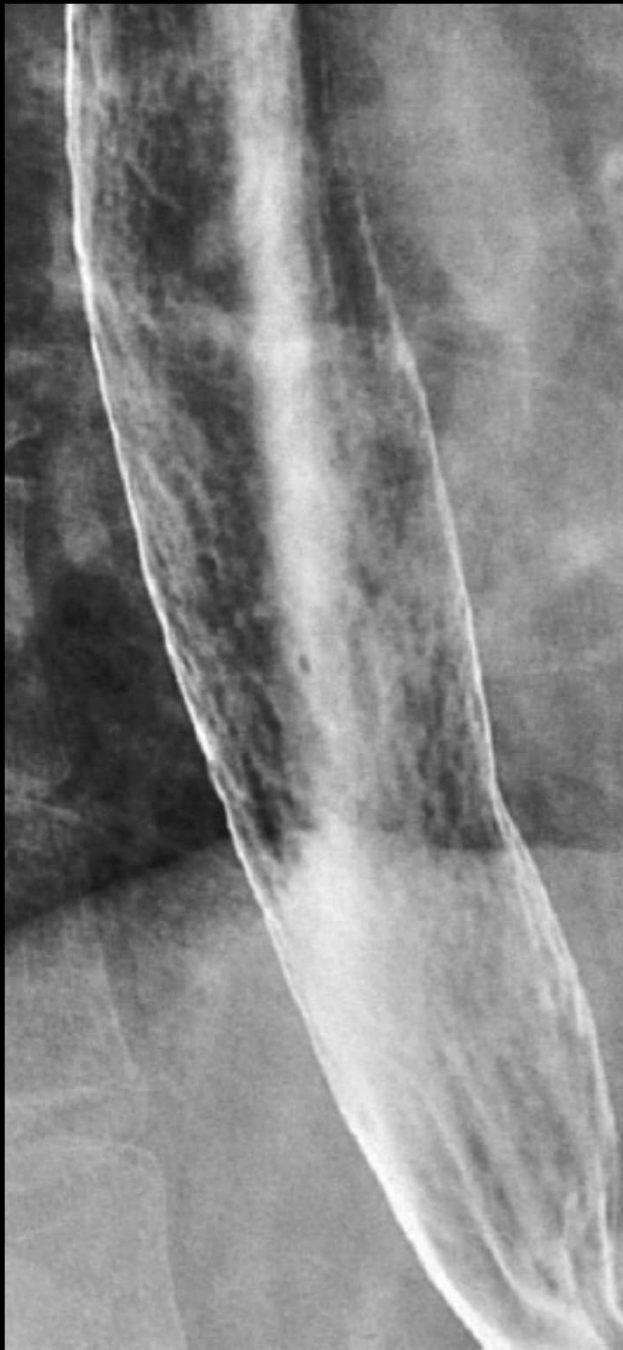













•


•

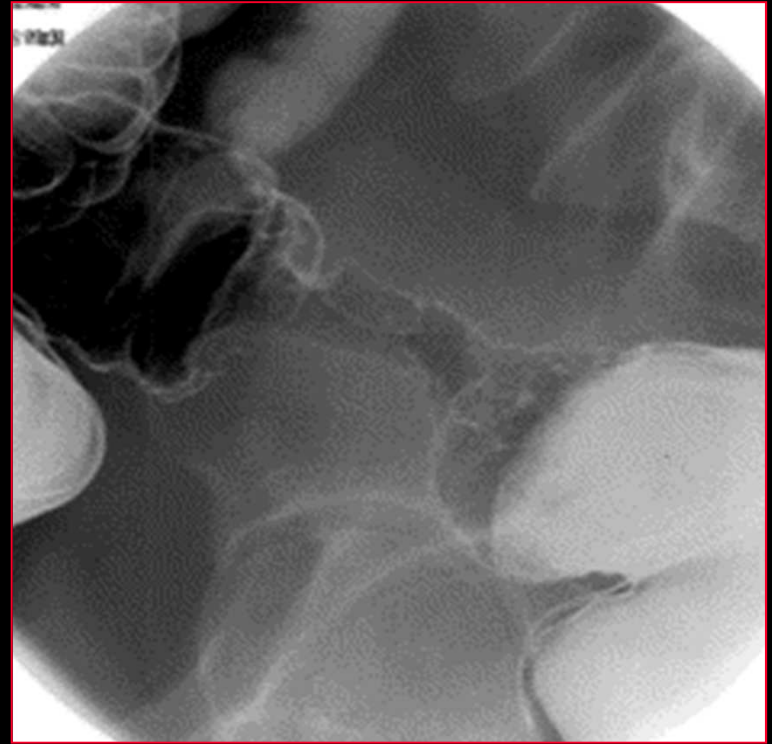
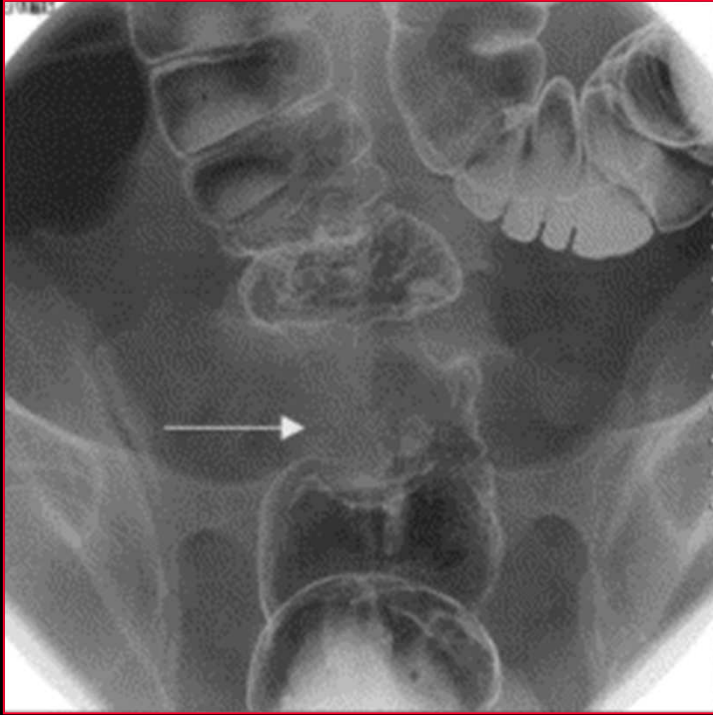
•

•

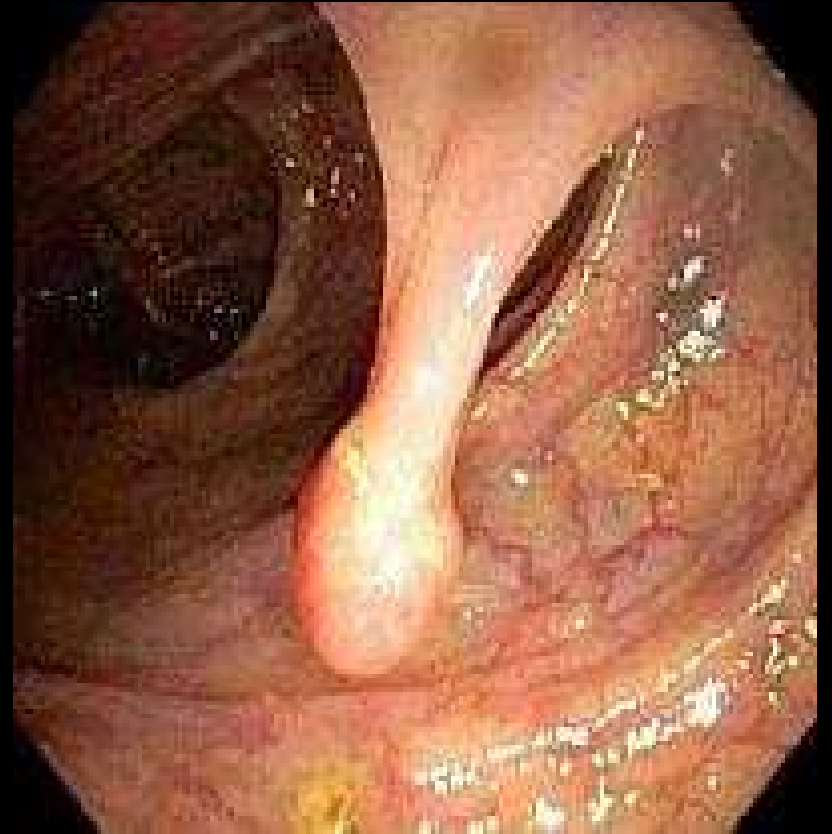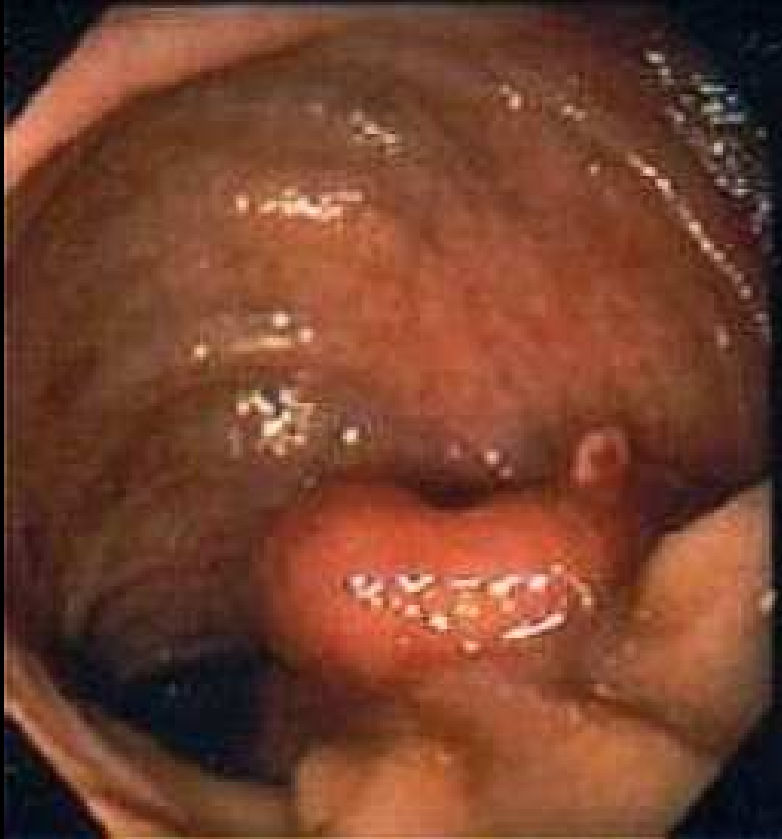•

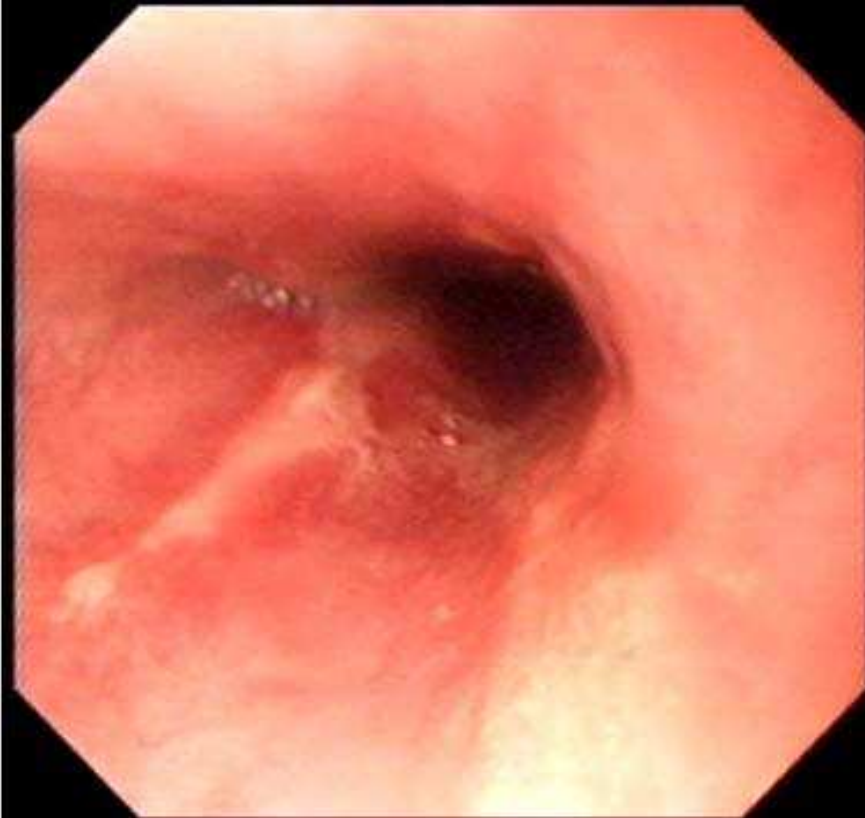
•

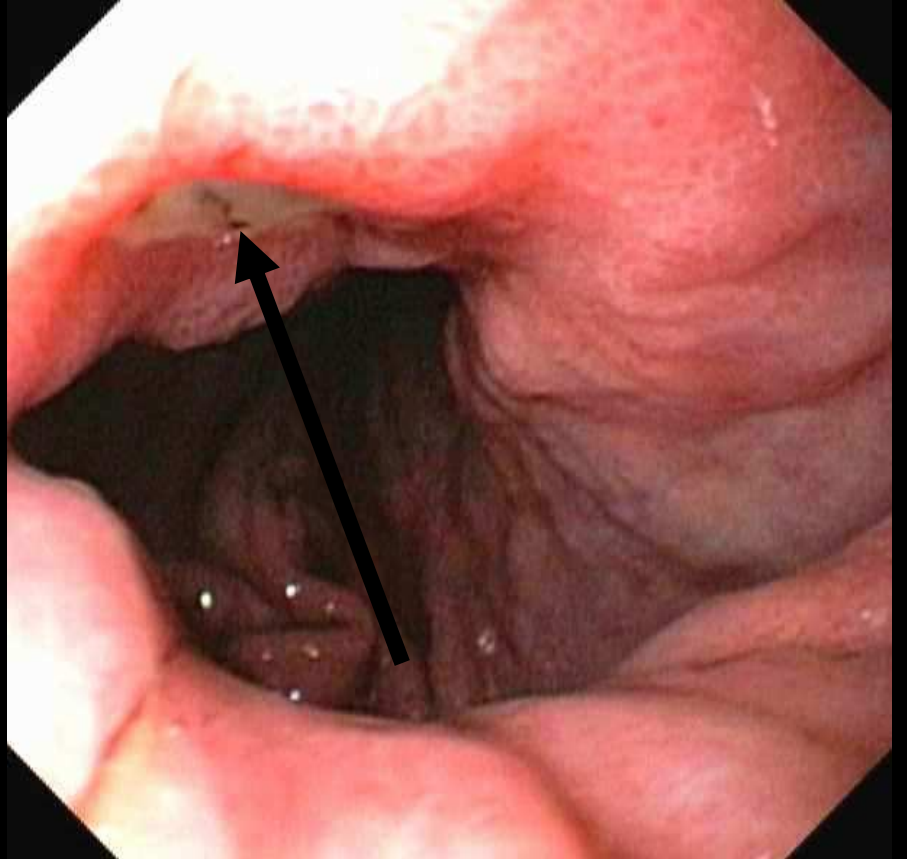





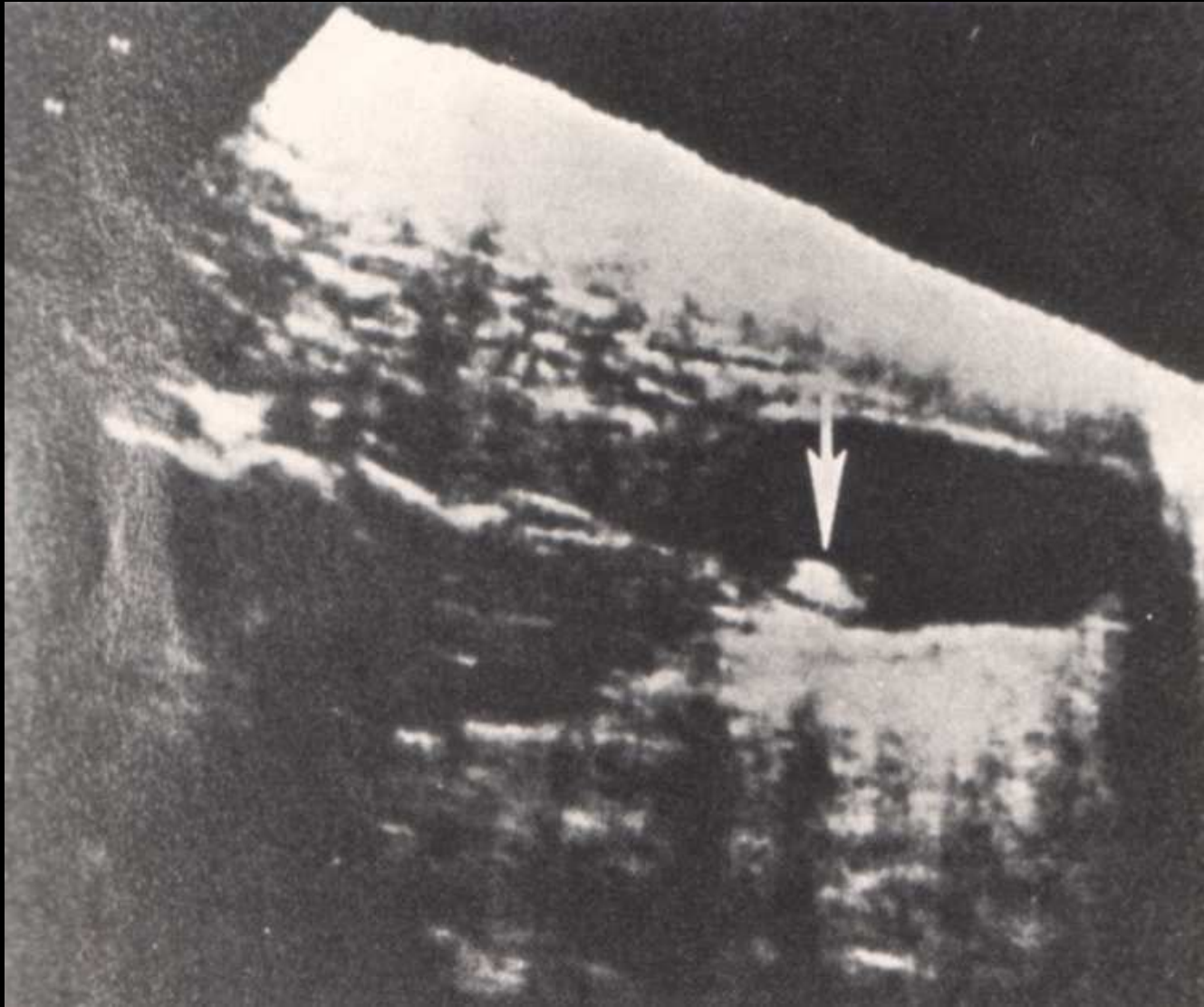





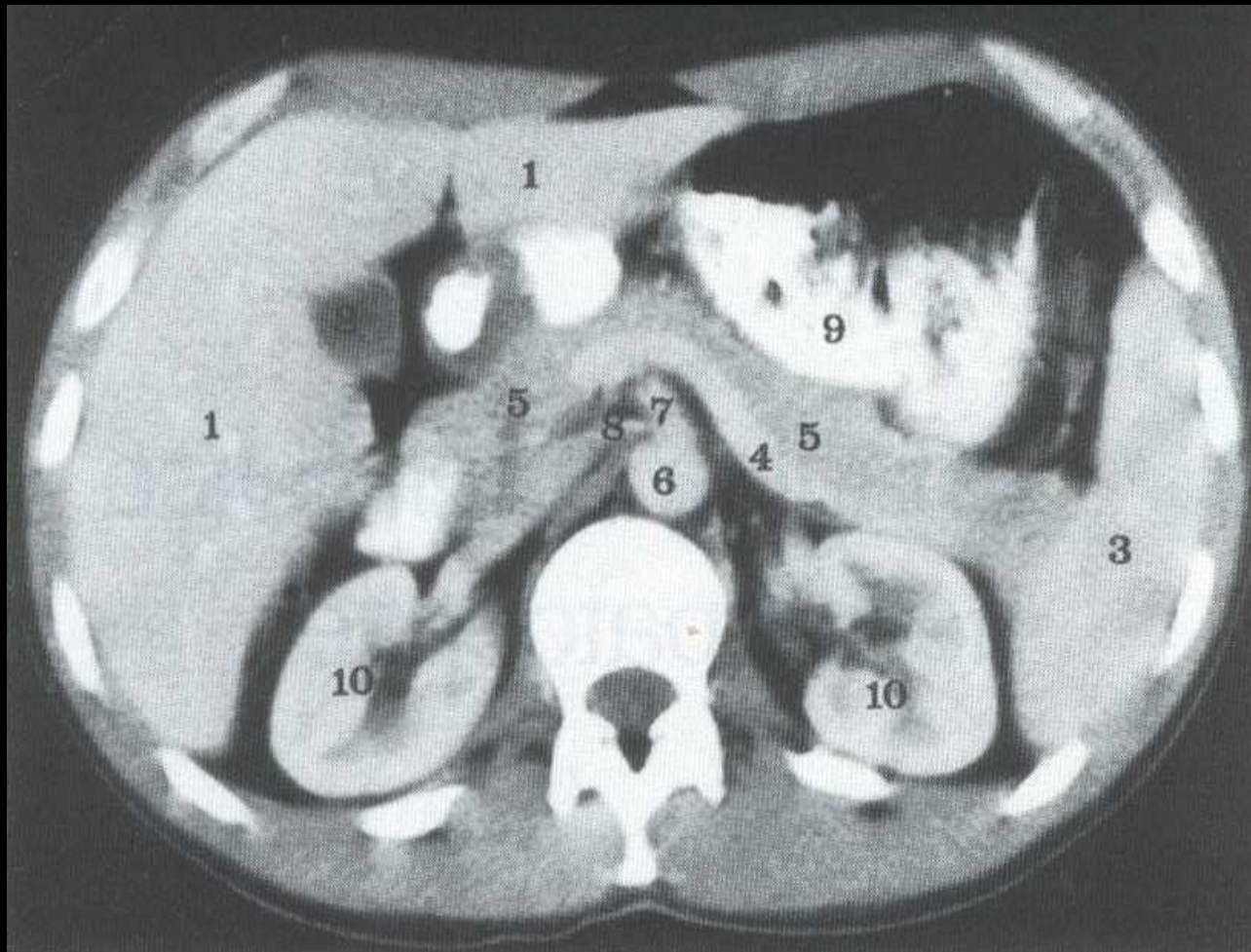






















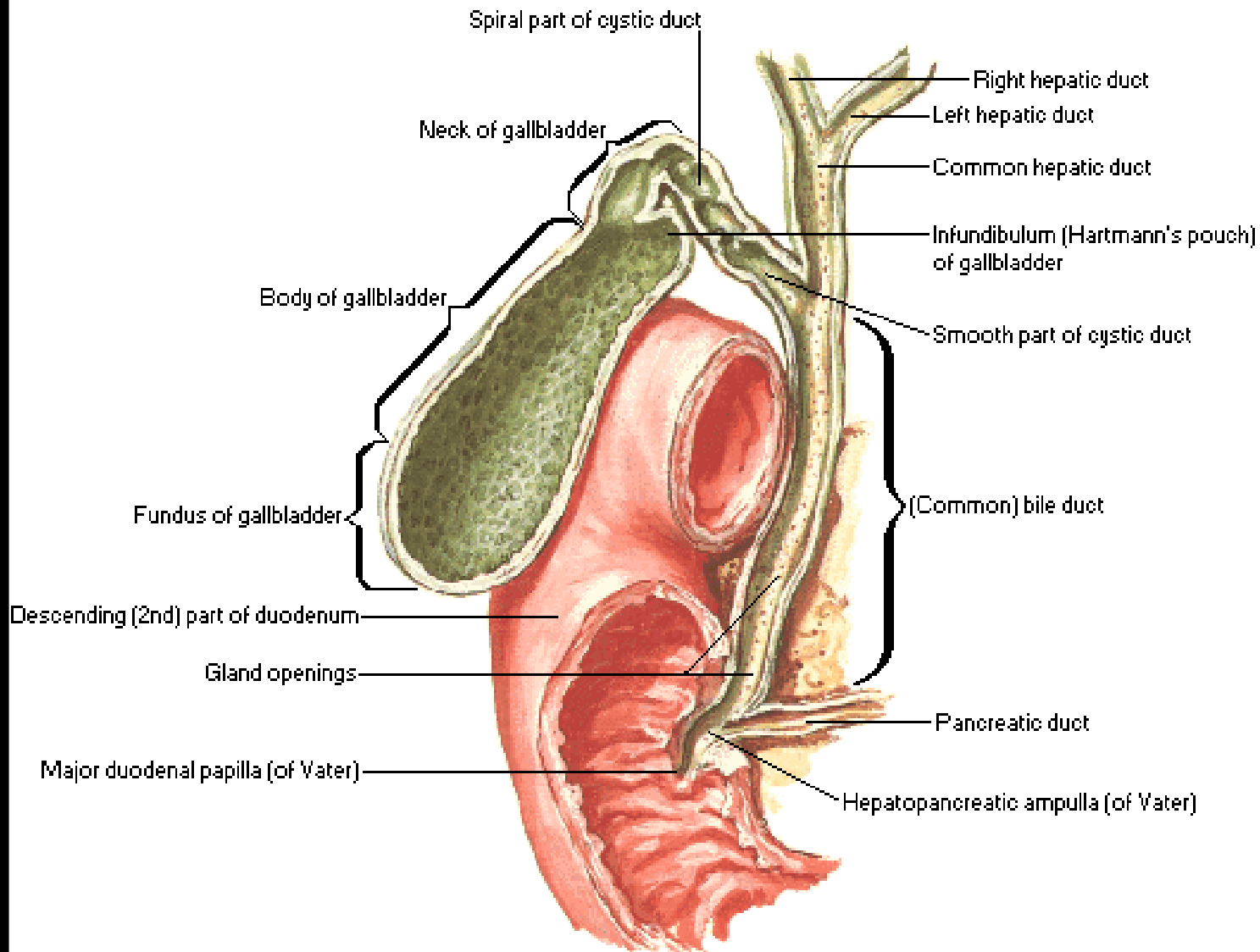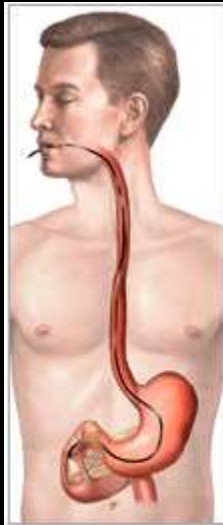










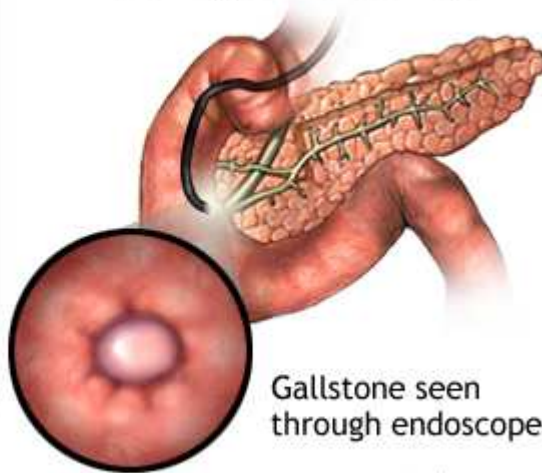






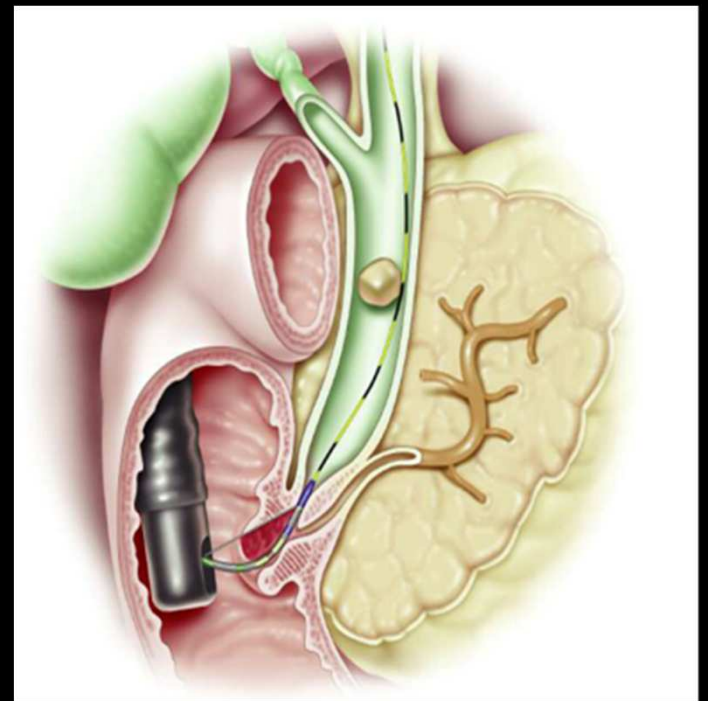
Endoscope inserted into mouth


Endoscope travels through gastrointestinal tract until reaching point of blockage





Gallstone seen through endoscope


ADAM.





















































Il valore dell'anamnesi (ανά μνεσις)...ma quale anamnesi ?

- **Anamnesi patologica prossima:**

Motivo del ricovero in PS, Reparto, della visita ambulatoriale, etc

Non sempre facile stabilire una netta separazione tra APR e APP...
(sintomi direttamente riconducibili alla patologia pregressa)

Sintomi !!!! Fondamentale chiedere: quando ?
come ? Acutamente o più gradualmente ?
caratteristiche ? Continuo...o periodico ?
intensità ?
è in relazione con atti fisiologici ? Postura ?

Se il sintomo è il «dolore»: sede, irradiazione, caratteri, tipologia
quando è comparso ? A digiuno ? Dopo
aver mangiato

C'è febbre ?

Acute pain

- **AMI**
- **Trigeminal nevralgia**
- **Migraine**
- **Renal colic**
- **Herpes zooster (VZV)**

Possible sites of alterations in gut sensitivity

